

## The Outcome of Delayed One Stage Urethroplasty in Post-Traumatic Prostatic-Membranous Urethral Stricture : A Retrospective Study of 50 Cases

ZH BHUIYAN<sup>a</sup>, MF ISLAM<sup>b</sup>, KMH TAWHID<sup>c</sup>, M SIRAJ<sup>d</sup>

### Summary:

*We have reviewed the result of delayed one stage urethroplasty through perineal approach in post traumatic prostatic-membranous urethral stricture with associated pelvic fracture in a retrospective study. The place of study is Bangladesh Medical College Dhaka. The study period was from Nov'01 to Aug'04. The sample size was 50. Thirty two cases presented with post-traumatic stricture of urethra ( PTSU ) with suprapubic cystostomy (SPC). The rest 18 cases were complicated and presented with recurrent stricture with associated periurethral abscess, suprapubic and perineal urethral fistula or thigh urinoma. These cases were managed initially by suprapubic cystostomy*

### Introduction :

Post traumatic stricture of urethra (PTSU) is one of the common problem with increasing incidence. The association between pelvic fracture and disruption of prostatic-membranous urethra following blunt trauma, as a result of high speed motor vehicle or pedestrian-motor vehicle accident is well described<sup>1</sup>. Management of traumatic prostatic-membranous urethral disruption or its subsequent complication is one of the most controversial and technically difficult problem in Urology<sup>2</sup>. Morbidity in the form of urethral strictures, impotence, incontinence may remain a source of life long misery<sup>3</sup>. The area of contention in the management of traumatic posterior urethral

*(SPC) and adequate local care before re-admission for definitive procedure.*

*All cases were underwent delayed one stage urethroplasty through perineal approach after > 3 months of SPC and were followed carefully for > 06 months in each case. The outcome in 42 cases were excellent; required no treatment. In 06 cases the result was good requiring 01 - 03 sessions of optical internal urethrotomy (OIU). Poor result was observed in 02 cases, managed by > 3 sessions of OIU followed by intermittent self dilatation (ISD). No patient needed re-operation. The overall result is excellent.*

*(J Bangladesh Coll Phys Surg 2007; 25 : 130-138)*

injury is centered on the argument that, primary urethral alignment is superior than conventional early SPC + delayed urethroplasty ? Which procedure decrease the need for further intervention ? However it is universally accepted that suprapubic cystostomy alone the best initial management. Further management depends upon the available facilities and experience of the surgeon<sup>3</sup>.

In general the short term success of immediate urethral realignment is excellent. But the long term result is not rewarding. It is currently accepted that it is a procedure of choice in cases of widely separated urethral ends or having associated bladder neck and rectal injuries. The major advantage of delayed urethral reconstruction is that it can be done under controlled conditions with better long – term result<sup>4</sup>. The main drawback of delayed urethral reconstruction is that the patient has to accept urethral stricture and suprapubic catheter for longer period<sup>5</sup>.

### Patients and methods :

This retrospective study was done in Bangladesh Medical College Dhaka. The study period was

- a. Zahid Hassan Bhuiyan FCPS (Surgery) MS (Urology) Assistant Professor,
- b. M Fakhru Islam Ph D Associate Professor
- c. KMH Tawhid MS Urol (Russia) Registrar
- d. Mamoon Siraj FRCS (Eng) FRCS (Edin) D Urol (UK) Assistant Professor

Dept. of Urology Bangladesh Medical College Dhaka.

**Address of Correspondence :** Md. Zahid Hassan Bhuiyan, FCPS (Surgery), MS (Urology). Assistant Professor, Dept. of Urology, Bangladesh Medical College Dhaka.

**Received:** 11 January, 2004

**Accepted:** 12 April, 2007

from Oct'01 to Sept'04. The selection criteria was traumatic prostatic-membranous disruption of urethra with associated pelvic fracture and the length of stricture segment is < 2.5 cm. The sample size was 50. Thirty two patients presented with PTSU with SPC. The rest 18 patients were complicated by previous intervention. We managed them with SPC first with adequate local care and was readmitted > 03 months later. All cases were re-evaluated with history, physical examination and investigations (to ensure operative fitness, normal renal function, sterile urine). Primary assessment of urinary tract was done by ultrasound scan and contrast imaging technique (Figure : 1, 2, 3.); simultaneous combined antigrade cystourethrogram and retrograde urethrogram (RGU). All patients were consulted routinely with orthopedic surgeon. Adequate movements of the lower limbs were assessed in all cases to ensure proper positioning during operation.

**Operative technique:** After spinal anaesthesia patients were placed in lithotomy position. The extent of stricture segment was assessed finally with the help of antigrade suprapubic and retrograde urethral dilators before the inverted U/Y incision was made in the perineum. With meticulous and clean dissection the immediate distal healthy urethra was exposed first. Then the total length of the stricture segment along with surrounding fibrous tissue was excised. The distal bulbar urethra and the proximal prostatic urethra was made pliable for tension free, spatulated, water tight anastomosis around a 14 Fr. Foley's catheter by interrupted 08 - 10 stitches using 5'0' vicryl suture. Mobilization of distal corpus spongiosum is sufficient in most of the cases to get well alignment of urethral ends. To further assist urethral alignment we needed to separate the corporal bodies in the midline with diathermy under the symphysis pubis in 10 cases. We didn't need urethral re-rooting or inferior pubectomy in any of our cases. Absolute haemostasis was ensured and the wound was drained routinely before closure in layers.

#### Result :

The mechanism of injury (Table : I) in pelvic fracture and prostatic-membranous urethral

disruption was either blunt trauma to the lower abdomen or compression injury to the pelvis. In 76 % (n = 38) of cases it was due to motor vehicle accident, in 12% (n = 06) of cases it was the result of pedestrian motor vehicle accident and in 8% (n = 4) of cases it results from crush injury and in 4% (n = 2) cases it results from accidental fall from height. Thirty percent (n = 15) of the patients were under went emergency laparotomy. Of them bowel repair with proximal enterostomy was done in 06 cases. Four cases were referred to us after closure of enterostomy. In rest 02 cases, enterostomy was closed after successful urethroplasty. Forty percent (n = 20) cases needed emergency orthopaedic management for fracture of pelvis and limbs. All cases of pelvic fracture were managed by conservative treatment. Of them 76% (n = 38) cases have high risk pelvic fracture (Table : II). The minimum age of the victim was 12, maximum 70 and average 32 years. The minimum period of time of accident and presentation to us was as low as 03 days and as high as 26 years (Table : III). Thirty two (64%) cases presented with SPC. The rest of the cases were complicated following intervention (Table : IV), presented with suprapubic leakage following failed delayed urethroplasty (8%, n = 4), dense recurrent urethral stricture with thigh urinoma (6%, n = 3), proximal periurethral abscess and fistula (22%, n = 11). These eighteen complicated patients were managed with SPC first and adequate local care (drainage of perineal abscess, thigh urinoma and regular dressing of the wound). Ten cases in our series developed secondary bladder stone. Of them 2 cases were under went suprapubic cystolithotomy two times and 8 cases for one time.

**Table-I**

*Nature of violence resulting urethral injury and pelvic fracture (n=50)*

Nature of violence	Number
Motor vehicle accident	38
Pedestrian motor vehicle accident	06
Crush injury	04
Accidental fall from height	02

**Table-II**

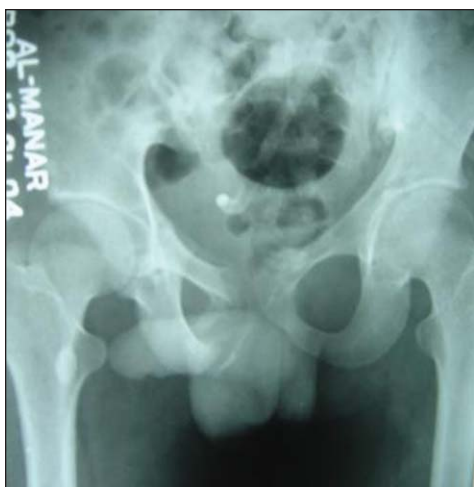<i>Various types of associated pelvic fracture ( n - 50 )</i>		Number
Low risk pelvic fracture	Single ramus ( pubic ) fracture	12
High risk	Diastasis (pubic symphysis) + multiple rami fracture pelvic fracture	30
	Diastasis (pubic symphysis ) + vertical displacement + multiple rami fracture	08

**Table -III**

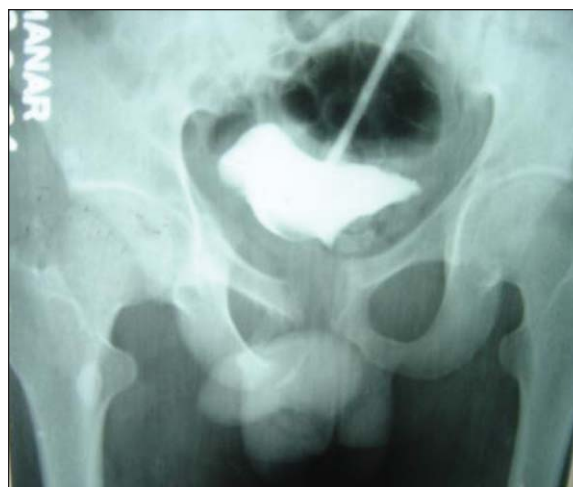<i>Age, duration between the onset of injury and presentation( n - 50)</i>				
	Age of patient	Number	Time of injury and presentation	Number
Min.	12 years	04	03 days – 3 year	48
Max.	70 years	01	22 - 26 years	02
Mean	32 years		1.5 years	

**Table -IV**

<i>History of past urological intervention ( n – 50)</i>			
			Number
SPC			32
Primary urethral re-alignment	Dilatation & catheterization		03
	Rail road method		09
	Primary Repair		02
Failed delayed perineal urethroplasty			04



**Fig.-1:** Control film : RGU + Antegrade cystourethrogram. (Healed mal-united pelvic fracture, suprapubic catheter in situ)



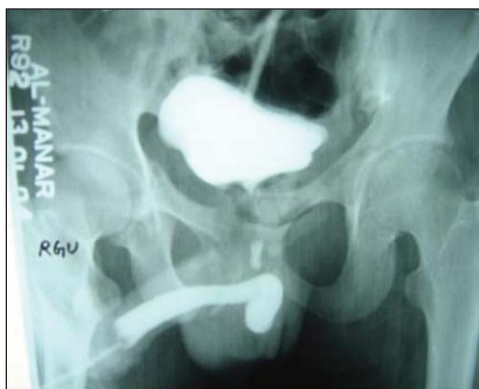**Fig.-2:** (same patient): Antegrade Cystourethrogram : Bladder is outlined, dye has not passed into the prostatic urethra due to bladder neck spasm.

After urethroplasty we ensure adequate rest of bladder by continuous drainage of urine through suprapubic and penile catheter (mainly to stent the anastomosis) aided with oral uro-selective anti-cholinergic drug. In complicated and doubtful cases (n-12) peri-catheter retrograde urethrogram (Figure : 4) was done at the end of 3<sup>rd</sup>. week. Anastomotic leakage of contrast was seen in two cases (Figure : 5) and the urethral catheter was continued for another 03 weeks (Total : 3 + 3 weeks). Repeat peri-catheter urethrogram appeared normal in both cases (Figure : 6). Urethral catheter was removed in 21<sup>st</sup>. POD in 48 cases, at the end of 6 week in 2 cases with clamping of suprapubic catheter. Suprapubic catheter was removed after ensuring the normal flow of urine in all cases.

All patients were followed carefully; monthly for three month and three monthly for one year, 6 monthly for one year then yearly afterwards.

**Table-V**

<i>Result of perineal anastomotic urethroplasty (n – 50)</i>	
	Number
Excellent (require no treatment)	42
Good (require 01 – 02 session of OIU)	06
Poor (require > 3 session of OIU + ISD)	02
Total failure	00

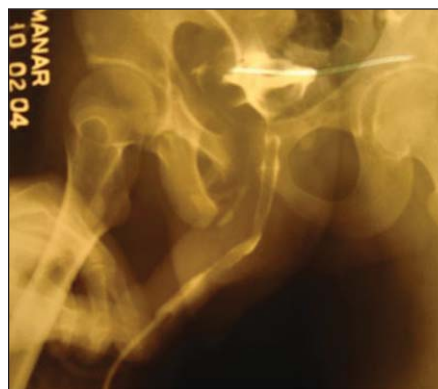


**Fig.-3:** (same patient) : Combined ante-grade cysto-urethrogram and retrograde urethrogram : Bladder is outlined, prostatic urethra is partially visualized, anterior urethra is well outlined upto bulbar urethra ; there is no communication between the anterior and posterior urethra.

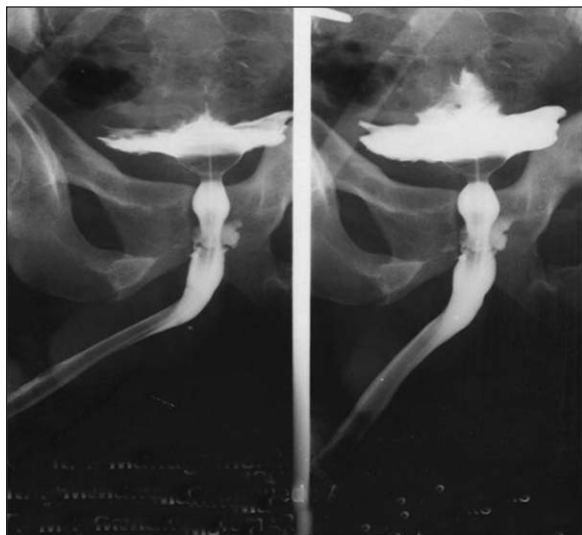Minimum period of follow-up was 06 months<sup>6</sup> if there is evidence of excellent AUA symptom score. Post-operatively we assessed every patients with history using American Urological Association (AUA) symptom index<sup>7</sup> and clinical examination. We routinely observe the urine flow during every follow-up. In equivocal and doubtful cases we have done uroflowmetry (n-15). All of our patients were continent (Table : V). Forty two cases had excellent urine flow. Further intervention was required only in 08 cases (01 – 02 session of OIU in 06 cases, > 3 session of OIU + ISD in 02 cases). We have taken history of penile erection and nocturnal tumescence in every cases before and after operation. Sixty eight percent (n - 34) of our patient have excellent quality of erection, 32% (n – 16) cases have sufficient penile turgidity. There was no significant change of quality of erection in our series following intervention.

**Table-VI**

<i>The overall Result of perineal urethroplasty (n – 50)</i>		
		Number
Parameters	Post-operative State	50
Continence	Well preserved	50
Potency	Not influence by operation	50
Rec. stricture	Membranous / short	08



**Fig.-4:** (same patient) : Post bulbo-prostatic perineal anastomotic urethroplasty. Retrograde peri-catheter urethrogram (21<sup>st</sup>. POD) : Dye has passed into the bladder and there is no anastomotic leakage. Urethral catheter could be removed with confidence.



**Fig.-5:** (Case - 2) : Post bulbo-prostatic perineal anastomotic urethroplasty. Retrograde peri-catheter urethrogram (21st. POD) : Dye has passed into the bladder and there is leakage in the anastomotic site. Urethral catheter was decided to continue for another 3 week.

#### Discussion :

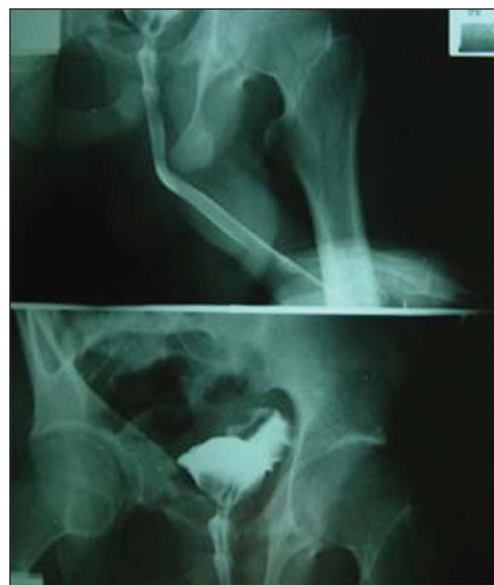Posterior urethral disruption usually occur after blunt rapid deceleration injury. Overall the risk of injury is greatly influenced by age and the types of pelvic fracture<sup>8</sup> Urethral injuries in association with pelvic fracture mostly due to indirect violence rather than direct trauma to the urethra by bony spicule<sup>1</sup>. High risk pelvic fracture and incidence of urethral injury is common in younger age group than in older patients<sup>8</sup>

As high as 3 to 25% of pelvic fracture and 10% -20% of bladder injuries have associated posterior urethral injury<sup>9</sup>. Obviously pelvic fracture as they are intimately related to urethral injuries may be classified as<sup>10</sup> :-

No risk group :- isolated fractures of acetabulum, ilium and sacrum.

Low risk group :- single or ipsilateral pubic or ischiopubic rami fracture.

High risk group :- straddle and Malgaigne fractures. These types of fracture results sudden upward displacement of hemi-pelvis specially



**Fig.-6:** (Case - 2 : Post urethroplasty anastomotic leakage in 21st. POD.) Repeat retrograde peri-catheter urethrogram ( 3 week later) : Dye has passed into the bladder and there is no leakage in the anastomotic site.

pubic rami results traction injury to the anterior and posterior urethral ligaments, sudden diastases of pubic symphysis also damage the posterior pubourethral ligament and urogenital diaphragm<sup>1</sup>. In our series most of the pelvic fracture ( n – 38 ) are of high risk group ( Table : II )

Initial evaluation of urethral injury was very difficult in most of the cases because of pain and co-morbidity. Patients who are unable to void with hematuria, blood at the urethral meatus, perineal hematoma or extravasation of urine with or without a high-riding prostate on digital rectal examination are signs that suggest a prostatomembranous urethral disruption<sup>11</sup>. In doubtful cases, retrograde urethrogram with gentle pressure using water soluble contrast will show urethral continuity with extravasation in case of partial urethral tear(34%) where as extravasation of contrast without urethral continuity is the feature of complete urethral disruption(66%)<sup>12</sup>. Emergency IVU may be done when severe injury is suspected. Cystogram phase of IVU may show extravasation of contrast in case bladder injury.



The extent of bladder elevation will give the idea of extent of urethral disruption or the volume of pelvic hematoma<sup>12</sup>.

The aim of rational management of the posterior urethral disruption is to make the patient free of strictures, continent and potent<sup>13</sup>. Management of urethral injury and its complication has been evolved in the last decade. Suprapubic cystostomy alone is the best initial management. It is an effective temporary technique of urinary diversion that does not interfere with the management of associated life threatening conditions. SPC is safe, simple may be performed quickly under local anaesthesia even in haemodynamically unstable patient in emergency situation within limited setup<sup>2</sup>. In our study ( Table : IV ) majority of urethral injuries ( n – 32, 64%) were managed by SPC in addition to laparotomy ( n – 15 ) for associated acute abdomen before referral to us. In rest of the case ( n – 18, 36% ) we did SPC first to manage the complications.

Primary urethral realignment using either railroad method, interlocking sound or endoscopic technique may be tried immediately or several days later after stabilization of associated injuries<sup>14</sup>. Though it is relatively easier technique, specially the endoscopic one but there may be chance of creation of false passage, introduction of infection, severe bleeding due to dislodgement of clot, pudendal nerve injury, difficulty in assessment of vitality of injured urethral ends<sup>5</sup>. In most patients who undergo primary realignment may develop stricture in the later period. In our study ( Table : IV) out of 18 failed cases 14 cases had history of primary urethral realignment. The subsequent morbidity of such recurrent strictures is directly related to different modalities of initial management. Urethroplasty may be easier in such cases because the strictures are usually short without lateral displacement of prostate<sup>15</sup>. Sometime it may also managed by optical internal urethrotomy with or without intermittent self urethral dilatation<sup>16</sup>. The need for multiple urethrotomies are proportional to the length of stricture segment ( > 2 cm.) or in presence of dense peri-urethral fibrosis. The success rate of

urethroplasty after multiple urethrotomy is much less. So repeated OIU is only recommended for unfit and elderly patients having short life expectancy. In our series failure cases following primary urethral realignment further complicated by periurethral abscess, fistula and thigh urinoma so urethroplasty was much difficult in those particular cases.

Considering various limitations and high incidence of late complication it is currently accepted that there are special criteria<sup>14</sup> where immediate urethral realignment is a procedure of choice without primary suture<sup>15</sup>.

Primary urethral realignment may be advantageous in cases of widely separated urethral ends or having associated bladder neck and rectal injuries.

Widely separated urethral ends are associated with disruption of all facial attachment and is likely to be disorganized even after dissolution of haematoma<sup>17</sup>. The accurate diagnosis of bladder neck injury and its primary anatomical repair is very important for the preservation of continence because external sphincter is usually damaged following injury or urethroplasty. Recognition of associated rectal injury and its repair will prevent the devastating events<sup>14</sup>.

Delayed reconstruction is advocated 2 – 6 months after initial suprapubic cystostomy. By this time the inflammation subsides and the scar matures<sup>18</sup>.

The major advantage of delayed urethral reconstruction after prostatomembranous disruption is that it can be done under controlled conditions when the patient has recovered from major associated injuries<sup>4</sup>. The main drawback of delayed urethral reconstruction is that the patient has to accept either incomplete or in most cases complete obliteration of urethra and also has to carry and care suprapubic catheter for longer period of time<sup>1</sup>.

Delayed endoscopic management of thin diaphragmatous stricture or those with a narrow lumen, is easier with insignificant morbidity. However, endoscopic maneuvers for complete urethral obliteration remains controversial. As much as 61% of impassable strictures could be managed endoscopically. The immediate success

rate may vary from 54% to 100% in different series. But the long-term recurrence rate of available series are not encouraging (62% to 89%)<sup>19</sup>. Despite initial enthusiasm for the newer technology, laser urethrotomy appears to offer no advantage over conventional urethrotomy<sup>5</sup>.

Delayed open urethral reconstruction may be done in single session or in two session. The most common two-stage repairs have been described by Johanson, Somervil et al, Schreiter and Noll. Two stage urethroplasty currently reserved in case of severe urethral damage, extensive urethral stricture or often after failed 1-stage repairs. The interval between two stages would allow for healing of the usually infected and damaged tissue before final reconstruction of the urethra<sup>20</sup>.

The different route of approach in single stage urethroplasty includes perineal, transpubic or combined perineal and suprapubic with or without free graft<sup>21</sup>. The success rate of delayed one stage urethroplasty through perineal approach in experienced hand is highly encouraging. It is more than 95%<sup>18</sup>. Much superior result (97%) was claimed in other study also<sup>22</sup>. We did delayed one stage urethroplasty through perineal approach in all cases with overall excellent result (Table : VI).

The assessment of exact site and extend is very important for operative planning. Conventional retrograde urethrogram is helpful to delineate the distal urethral margin. Antigrade cystourethrogram or MCU may fail to outline the prostatic urethra because of bladder neck spasm. The role of Color Doppler<sup>23</sup> and Sonourethrography<sup>24</sup> is useful for the assessment of anterior urethra strictures and local tissue vascularity better than conventional RGU. The narrow area of prostatomembranous stricture region is difficult to image accurately. Pelvic MRI though very expensive but is excellent in this regard for precise evaluation of distance and direction of disrupted prostatomembranous urethra<sup>22</sup>. Thus preoperative MRI has main clinical impact to determine the route of better approach, to justify the planning of total or inferior pubectomy in difficult situation. We did conventional RGU and antigrade cystourethrogram in all cases. We finally assess the stricture site

under anaesthesia before incision using antigrade suprapubic and retrograde urethral dilators.

The American Urological Association (AUA) symptom index was introduced in 1992 and has gained worldwide acceptance for the assessment of symptomatic BPH and its treatment outcome<sup>7</sup>. The role of AUA symptom index for assessment of therapeutic response after urethroplasty is well established. If the symptom scores were failed to diminished after urethroplasty subsequent investigations will show the presence or recurrence of stricture. Following successful re-operation it was seen to decrease the symptom score in the same patient<sup>25</sup>. We have also used AUA symptom index during history taking for the assessment of post operative outcome in all cases when attended in follow-up.

The result of different modalities of managements in post traumatic prostatic-membranous urethral disruption published in different journal from 1968 to 1990 were analyzed in a review study<sup>26</sup>. It was observed that some of the patients among immediate suprapubic cystostomy with delayed urethroplasty group ( total : n- 199 ) may develop normal flow of urine during the waiting period of operation, leading to conclusion that some of the cases of partial urethral rupture may heal completely without residual disability ( n – 9, 5.25%). No recurrence of stricture was seen in rest of the patient underwent delayed urethroplasty. Among the early urethral realignment group ( n- 304 ), 53.9% cases developed stricture. The result of the study is compatible to another review study of 237 patients of 5 different series<sup>12</sup>. In our series we did not find to establish the normal flow of urine in any of our patients while waiting for delayed urethroplasty. But we have seen to pass insignificant volume of urine in some of our cases ( n – 05 ). Eighty four percent ( n – 42 ) of our patients did not need any intervention after urethroplasty. Recurrent urethral stricture was seen in only 16%( n – 8 ) cases managed by OIU + ISD ( Table : IV). The overall result in our study is excellent and no patient needed re-operation.

Impairment of male sexual function after disruption of prostatomembranous urethra with

associated pelvic fracture is well known and it varies from 2.6 to 50%<sup>27</sup>. There was lot of controversies regarding the nature of intervention influencing the incidence of impotence and the incontinence. Morehouse et al claimed higher incidence of impotence and incontinence among the patients treated with immediate and early realignment technique than initial SPC and delayed urethroplasty. Webster et al<sup>12</sup> supported the observation of Morehouse et al and recommend to prefer initial SPC and delayed urethroplasty over immediate or early urethral realignment unless there is specific indication.

The study of Morehouse et al was thoroughly analyzed and was challenged later in many other studies<sup>14,26,27</sup>. It was observed that Morehouse et al. dealt a group of patients, referred to them after failed attempt of immediate realignment<sup>28</sup>. Higher incidence of impotence and incontinence was observed among referred group and was attributed to the result of initial operative technique. Morehouse et al compared those group of referred patients with their own population of patients to whom elective initial SPC and delayed urethroplasty was done. Patterson et al<sup>29</sup> in their series had shown the excellent preservation of potency in early realignment group; even equal or better preservation of potency was claimed in some study<sup>14</sup>. Where as Zincke H et al reported poor preservation of potency in delayed urethroplasty group<sup>30</sup>.

During delayed urethroplasty identification of neurovascular bundle may be impossible or at least very difficult because it lies more lateral or already entered in the corporal bodies. On the other hand it is difficult to explain the neurovascular injury during early urethral realignment by careful manipulation of only the trauma site, situated more anteromedial to the neurovascular bundle. Even then this maneuver is much specific by early endoscopic realignment technique<sup>14</sup>.

The nervi erigentes; situated dorsolateral to the prostate-membranous urethra is more likely to get injured following associated pelvic fracture<sup>14</sup>. King et al reported 42% incidence of loss of

potency if urethral rupture is associated with pelvic fracture and is only 05% when it is not associated with pelvic fracture. This study was supported by the study of Gibson et al<sup>27</sup>. There are also reported observation of regaining of potency following delayed urethroplasty<sup>27</sup>. It is also difficult to explain how delayed urethroplasty helps recovery of potency. Considering the current available literature it could be inferred that the outcome of management of post-traumatic prostate-membranous disruption in relation to potency and continence depends upon the result of initial injury to the neurovascular bundle supplying the corporal bodies and injury to the sphincter ( internal, or both external and internal ) rather than operative technique; provided it is done in good centre by expert hand<sup>14</sup>. In the present series so far preoperative and postoperative history concern operative technique did not influence the potency in any of our cases. All patients were continent postoperatively with intact internal urethral sphincter.

#### **Conclusion :**

Post traumatic prostatomembranous urethral disruption results from distraction force affecting the weakly supported membranous urethra may be associated with pelvic fracture. Every case is to be judged individually to select best options of available modalities. Suprapubic cystostomy alone is the best initial management. Further management depends upon the expertise of the surgeon and available facilities. Primary urethral realignment should be done only in selective group of patients. Two stage urethroplasty is currently reserved in case of severe urethral damage, extensive urethral stricture or often after failed 1- stage repairs. The best long-term result could be obtained by delayed one stage urethroplasty through perineal approach as seen in the present study.

#### **References :**

1. Perry MO, Husmann DA. Urethral injuries in female subjects following pelvic fractures. *J Urol* 1992; 147:139.
2. Glass RE, Flynn JT, King JB and Blandly JP. Urethral injury and fracture pelvis. *BJU* 1978; 50:578.



3. Turner-warwick R. A personal view of the immediate management of pelvic fracture urethral injuries. *Urol Clin North Am* 1977; 4:81.
4. McAninch JW. Traumatic injuries to the urethra. *J Trauma* 1981; 21:291.
5. Guille F, Cipolla B, Leveque J-M, Guirassy S, Olivo JF and Lobel B. Early endoscopic realignment of complete traumatic rupture of posterior urethra. *BJU* 1991; 68:178-80.
6. Roehrborn CG and McConnel JD. Analysis of factors contributing to success or failure of 1-stage urethroplasty for urethral stricture disease. *Urol* 1994; 151:869-874.
7. Ukimura O, Kojima M, Inui E, Ochiai A, Hata Y et al. A statistical study of the American Urological Association symptom index for benign prostatic hyperplasia in participants of mass screening program for prostatic diseases using transrectal sonography. *J Urol* 1996; 156:1673.
8. Koraitim MM, Morzouk ME, Atta MA and Orabi SS. Risk factors and mechanism of urethral injury in pelvic fracture. *BJU* 1996; 71:876.
9. Carlin BI, Resnik MI. Indications and Techniques for urologic evaluation of the trauma patient with suspected urologic injury. *Semin Urol* 1995; 13:9-24.
10. Koraitim, MM. Pelvic fracture urethral injuries : The unresolved controversy. *J Urol* 1999; 161:1433-41.
11. Morey AF, Hernandez J, McAninch JW. Reconstructive Surgery for Trauma of the Lower Urinary Tract. *Urol Clin North Am* 1999; 26:49-60.
12. Webster GD, Mathes GL and Selli C. Prostatomembranous urethral injuries : A review of the literature and a rational approach to their management. *J Urol* 1983; 130:898-902.
13. Husmann DA, Wilson WT, Boone TB and Allen TD. Prostatomembranous urethral disruption : management by suprapubic cystostomy and delayed urethroplasty. *J Urol* 1990; 144:76-78.
14. Follis HW, Koch MO and McDougal WS. Immediate management of Prostatomembranous urethral disruptions. *J Urol* 1992; 147:1259-62.
15. Koraitim MM. Pelvic fracture urethral injuries : Evaluation of various methods of management. *J Urol* 1996; 156:1288-91.
16. Devine CJ Jr, Jordan JH and devine PC. Primary realignment of the disrupted prostatomembranous urethra. *Urol Clin North Am* 1989; 16:291.
17. Turner-warwick R. Complex traumatic posterior urethral strictures. *J Urol* 1977; 118:564.
18. Carr LK, Webster GD. Posterior urethral reconstruction : Perineal approach. *Alt Urol Clin North Am* 1997; 5:125-37.
19. Heyns CF, Steenkamp JW, De Kock MLS and Whitaker P. Treatment of male urethral strictures : is repeated dilatation or internal urethrotomy useful? *J Urol* 1998; 160:356-58.
20. de la Rosette JJMCH, de Vries JDM, Lock MTWT and Debruyne FMJ. Urethroplasty using the pedicled island flap technique in complicated urethral strictures. *J Urol* 1991; 146:40-42.
21. Goel MC, Kumar M, Kapoor R. Endoscopic management of traumatic posterior urethral stricture. Early results and follow-up. *J Urol* 1997; 157:95-97.
22. Morey AF, McAninch JW. Reconstruction of posterior urethral disruption injuries: Outcome analysis in 82 patients. *J Urol* 1997; 157:506-510.
23. Chiou RK, Anderson JC, Tran T, Patterson RH, Wobig R et al. Evaluation of urethral strictures and associated abnormalities using high-resolution Color Doppler Ultrasound. *Urol* 1996; 47:102.
24. Morey AF and McAninch JW. Role of preoperative Sonourethrography in bulberurethral reconstruction. *J Urol* 1997; 158:1376-79.
25. Morey AF, McAninch JW, Duckett CP and Rogers RS. American Urological Association symptom index in the assessment of urethroplasty outcomes. *J Urol* 1998; 159:1192-94.
26. Herschorn S, Thijssen A and Radomski SB. The value of immediate or early catheterization of traumatized posterior urethra. *J Urol* 1992; 148:1428-31.
27. Dhabuwala CB, Hamid S, Katsikas DM and Pierce JM Jr. Impotence following delayed repair of prostatomembranous urethral disruption. *J Urol* 1990; 144:677-78.
28. Morehouse DD, Belitsky P and MacKinnon K. Rupture of the posterior urethra. *J Urol* 1972; 107:255.
29. Patterson DE, Barrett DM, Myers RP, DeWeered SH, Hall BB and Benson RC Jr. Primary realignment of posterior urethral injuries. *J Urol* 1983; 129:513.
30. Zencke H and Furlow WL. Long-term results with transpubic urethroplasty. *J Urol* 1985; 133:605.