

# Role of CT (Computed Tomography) in the Evaluation of Fungal Diseases in Paranasal Sinus

T ISLAM<sup>a</sup>, SA AZAD<sup>b</sup>, ME KARIM<sup>c</sup>, L KHONDKER<sup>d</sup>, K RAHMAN<sup>e</sup>

## Summary:

*A cross sectional study carried out with patients having suspected paranasal sinus (PNS) mass during January 2009 to October 2010 to evaluate the fungal diseases in PNS by computed tomographic(CT) image and comparison of the findings of this modality with histopathological result. Among the total 76 patients, the mean age of the patients was 35.95 ± 18.24 and common complaints of the patients were nasal obstruction (73.7%) and maximum 53.9% patients had PNS mass in maxillary sinuses. Out of all cases 10 were diagnosed as having fungal infection/mass by CT scan and confirmed by histopathological evaluation. Two cases were diagnosed as having fungal infection/mass by CT scan but not confirmed by histopathological findings.*

## Introduction:

There are many radiologically important diseases of paranasal sinuses. Acute sinusitis, nasal polyposis, mucocoeles, different types of fungal diseases, Wegener's granulomatosis and different types of benign to life threatening malignant tumours are important.<sup>1</sup> The radiologic examination is considered sometimes a complementary or supplementary diagnostic procedure to the clinical findings.<sup>2</sup> CT scanning has the ability to

*Of 64 cases of other than fungal infection/mass, which were diagnosed by CT scan, six were confirmed as having fungal infection/mass and 58 were other than having fungal infection/mass by histopathology. Sensitivity of CT scan to diagnose fungal infection/mass was 62.5%, specificity 96.7%, positive predictive value 83.3%, negative predictive value 90.6% and accuracy 89.5%. CT scan of the fungal diseases in paranasal sinus provides more information and better image quality and CT diagnosis correlate well with the findings of histopathology.*

**Key words:** CT evaluation of PNS mass, fungal diseases in PNS, histopathology of PNS mass.

(J Bangladesh Coll Phys Surg 2013; 31: 189-193)

obtain thin-slice, high-resolution sectional images. CT scan is an imaging modality of choice for evaluation of a suspected PNS mass. It provides useful information in regards to: location of the mass, characteristics of the mass (fat, fluid, solid); likely origin, mode of extension or spread.<sup>3</sup> Recent advances in imaging techniques have made it possible to detect various PNS mass with the aid of computed tomography (CT) and magnetic resonance (MR) imaging.<sup>4</sup>

Various fungal diseases involve the sinonasal cavities. The most common and most important of these include mucormycosis, histoplasmosis, and candidiasis and diseases caused by Aspergillus.<sup>5</sup> The radiographic features of fungal diseases involving the paranasal sinuses are usually nonspecific and include opacification of the sinus as well as a sclerotic bony reaction. Air-fluid levels are uncommon and, when present, suggest a bacterial infection rather than a fungal infection.<sup>6</sup> Mucor-mycosis occurs almost exclusively in immunocompromised hosts. Fifty percent to 75% of these patients have poorly controlled or uncontrolled diabetes mellitus. The causative organisms are invasive and tend to spread rapidly from the nasal cavity to the paranasal sinuses. They have a propensity for invading blood vessels. In doing so, they denude the endothelial lining and initiate thrombosis, which leads to venous cerebral infarcts.<sup>7</sup> Invasion of the orbits, cavernous sinuses, and ophthalmic veins is common. Intracranial extension, via

- a. Dr Tahmina Islam, MBBS, MD, OSD, DGHS, Mohakhali, Dhaka.
- b. Professor Dr. Salahuddin AI-Azad, MBBS, FCPS, DMRD, Chairman, Department of Radiology & Imaging Bangabandhu Sheikh Mujib Medical University, Dhaka.
- c. Professor Dr. Md. Enayet Karim, MBBS, MD, FCPS, DM RD Department of Radiology & Imaging Bangabandhu Sheikh Mujib Medical University, Dhaka.
- d. Dr. Lubna Khondker, MBBS, DDV, MCPS, FCPS, Assistant Professor, Dept. of Dermatology and Venereology Bangabandhu Sheikh Mujib Medical University (BSMMU). Shahbag, Dhaka.
- e. Dr. Khalilur Rahman, MBBS, M Phil, MD, Assistant Professor, Department of Radiology & Imaging Dhaka Medical College Hospital, Dhaka.

**Address of Correspondence:** Dr. Tahmina Islam, Department of Radiology & Imaging, dermatology and Venereology and Otolaryngology and department of Pathology of the Bangabandhu Sheikh Mujib Medical University, Dhaka. Mobile: 01612132170

**Received:** 25 April, 2012

**Accepted:** 10 September, 2013

emis-sary vein, may extend to the meninges and eventually lead to cerebral abscess. Progression may be rapid, occurring within a few days. The disease also occurs in immunocompromised patients with hematologic malignancies and those with acquired immunodeficiency syndrome (AIDS). Because fungi tend to bind calcium, manganese, and other heavy metals, a large number of affected paranasal sinuses may appear hyperdense on CT scans and of low signal intensity on MRI studies. In the latter stages of infection bony destruction may mimic an aggressive tumor such as squamous cell carcinoma.<sup>8</sup> On the other hand, Aspergillus infection usually occurs in otherwise healthy patients and has no relationship to pulmonary aspergillosis which is known to occur in debilitated patients. The radiographic appearance, however, is similar to other fungal infections with opacification of a single paranasal sinus, a hyperdense paranasal sinus on CT scans, hypointense signal on T2-weighted MRI studies from heavy metal, and osseous destruction mimicking aggressive tumor in the later stages. Although less aggressive than mucormycosis, Aspergillus infection may cause a vasculitis that results in cerebral thrombosis as well.<sup>9</sup> This study will help our people to save their hard earnings as well as policy maker to take proper action in case of the patients of PNS mass. Present study designed to evaluate the fungal diseases among other PNS mass by CT (computed tomographic image) and findings of this modality were compared with histopathological result.

#### Materials and Methods:

A cross sectional study was carried out with 76 patients, in the department of Radiology & Imaging, Dermatology and Venereology and Otolaryngology and department of Pathology of the Bangabandhu Sheikh Mujib Medical University, Dhaka. This study was carried out with suspected PNS mass having patients who were attended in the department of Dermatology and Venereology and Otolaryngology, BSMMU Dhaka and department of Radiology & Imaging of same hospital and this study was carried out from January 2009 to October 2010. Samples were selected purposively among the patients. Inclusion criteria were patients with PNS mass evaluated clinically and patients with PNS mass evaluated by PNS radiograph. Exclusion criteria were

patients refusing to do CT scan and patients who were unwilling to do histopathology. A pre-tested questionnaire were used as research instruments. Statistical analysis of the results were presented in tables and figures. For the validity of study outcome, sensitivity, specificity, accuracy, positive predictive value and negative predictive value of CT scan in the diagnosis of fungal diseases in the paranasal sinus were calculated.

Scanning technique of CT scan and Histopathological correlation:

All patients were undergone CT examination of PNS at the department of Radiology and Imaging, BSMMU, Dhaka. All CT scan was performed with a third generation CT, Hitachi W2000. These scans were obtained using 120 kv, 150 mA, 7.5 mm collimation and 1 sec scanning time for 1 slice. Both pre and post contrast scan was performed. 50 ml of non ionic water soluble iodinated contrast medium of 370 strength was administered. Immediately after completion of bolus injection 3-5 mm contiguous slice was obtained. The postoperative resected tissues were examined histopathologically in the department of pathology and then the collected reports were correlated with findings of CT.

#### Result:

Figure I showed the age distribution of the patients. Maximum 30.3% patients were belonged to 46 to 60 years age group followed by 26.3% within 16-30 years, 17.1% more than 60 years, 15.8% within 31 to 45 years and 10.5% up to 15 years. Mean (SD) age of the patients was 35.95 ( $\pm$  18.24) and all patients were belonged from 4 years to 70 years.

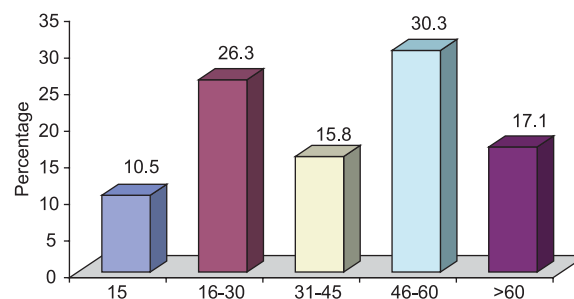


Fig-1: Age distribution of the patients

**Table-I**

*Distribution of patients by clinical presentation (n=76)*

Clinical presentation	Frequency	Percent
Nasal obstruction	56	73.7
Breathing difficulty	36	47.4
Headache	30	39.5
Epistaxis	16	21.1
Eyeache	9	11.8
Proptosis	8	10.5
Gradual swelling of face	7	9.2

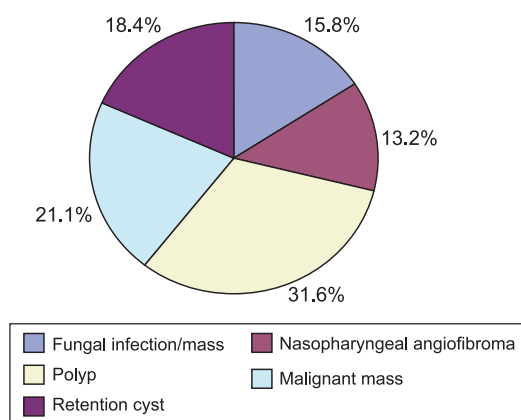
Table I showed the different clinical presentations of patients having PNS mass. Of them maximum 73.7% had complaints of nasal obstruction, followed by 47.4% had breathing difficulties, 39.5% had headache, 21.1% had epistaxis, 11.8% had eyeache, 10.5% had proptosis and 9.2% had puffiness of their face.

**Table-II**

*Distribution of location of the lesion of PNS (n=76)*

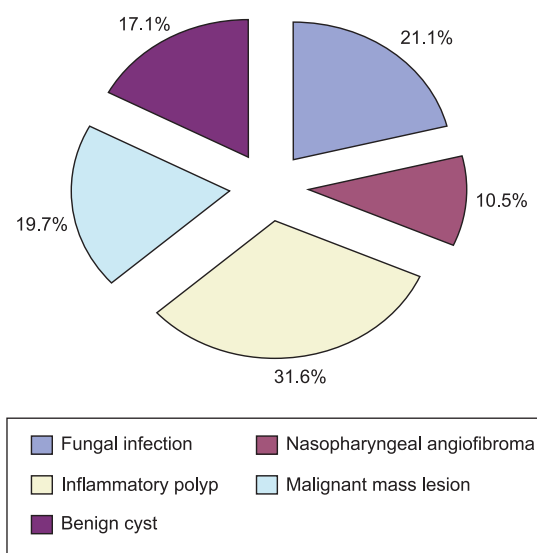
Location of the lesion	Frequency	Percent
Maxillary sinuses	41	53.9
Nasal cavity	13	17.1
Ethmoid sinuses	11	14.5
Sphenoid sinuses	8	10.5
Frontal sinuses	5	6.6

Table II showed the frequency distribution of the PNS mass at different locations. Maximum 53.9% patients had PNS mass in maxillary sinuses followed by 17.1% in nasal cavity, 14.5% in ethmoid sinuses, 10.5% in sphenoid sinuses and rest 6.6% in frontal sinuses.



**Fig.-2: CT diagnosis of PNS masses**

Figure II showed the CT diagnosis of PNS masses. Out of 76 cases 31.6% had polyp, 21.1% had malignant mass, 15.8% had fungal infection/mass, 13.2% had nasopharyngeal angiofibroma, and 18.4% had retention cyst.



**Fig.-3: Histopathological diagnosis of PNS masses**

Figure III showed the histopathological diagnosis of PNS masses. Out of 76 cases 31.6% had inflammatory polyp, 19.7% had malignant mass, 21.1% had fungal infection, 10.5% had nasopharyngeal angiofibroma, and 17.1% had benign cyst.

**Table-III**

*Distribution of fungal diseases in PNS by CT scan and histopathological diagnosis*

CT diagnosis	Histopathological diagnosis	
	Fungal infection	Other
Fungal infection(12)	10	2
Others(64)	6	58
Total(76)	16	60

Out of all cases 10 were diagnosed as having fungal infection/mass by CT scan and confirmed by histopathological evaluation. They were true positive. Two cases were diagnosed as having fungal infection/mass by CT scan but not confirmed by histopathological findings. They were false positive. Of 64 cases of other than fungal infection/mass, which were diagnosed by

CT scan, six were confirmed as having fungal infection/mass and 58 were other than having fungal infection/mass by histopathology. They were false negative and true negative respectively.

**Table-IV**

*Sensitivity, specificity, positive and negative predictive value and accuracy of the CT scan in the diagnosis of fungal diseases.*

Validity test	Percentage	95% CI
Sensitivity	62.5	44.8-71.2
Specificity	96.7	91.9-99.0
PPV	83.3	59.7-95.0
NPV	90.6	86.2-92.8
Accuracy	89.5	82.0-93.1

Sensitivity of CT scan to diagnose fungal infection/mass was 62.5%, specificity 96.7%, positive predictive value 83.3%, negative predictive value 90.6% and accuracy 89.5%.

#### **Discussion:**

This cross sectional study was conducted with total 76 patients. Mean (SD) age of these patients was 35.95 ( $\pm$  18.24) and maximum 30.3% patients were belonged to 46 to 60 years age group. In a previous study done by Rupa et al, similar age group was evaluated. Mean age of their patients was 29.39 years and maximum patients were within 10-19 year age group.<sup>10</sup> In study by Swamy and Gowda age incidence varied from 9 months to 60 years and commonest age group was 11 to 20 years (36.66%).<sup>11</sup> Our study findings do not correlate with others. As our patients included in the study, were collected from outdoor patients department(OPD) of Bangabandhu Sheikh Mujib Medical University and this OPD works only in official hours(8 am to 2 pm), so patients aged less than 45 years, usually attend less, due to their official or business activities.

Nasal obstruction (73.7%), breathing difficulties (47.4%), headache (39.5%), epistaxis (21.1%), eyeache (11.8%), proptosis (10.5%) and puffiness face (9.2%) were the commonest presenting symptoms of the patients of present study. In study by Swamy and Gowda, nasal obstruction (76.66%), epistaxis (53%), and nasal discharge (50.0%) were the commonest symptoms followed by mass, headach, hyposmia and nasal twang of speech.<sup>11</sup>

In the present study CT scan evaluated the patients with provisionally diagnosed PNS masses. Out of 76 cases 31.6% had polyp, 21.1% had malignant mass, 15.8% had fungal infection/mass, 13.2% had nasopharyngeal angiofibroma, and 18.4% had retention cyst. After radiological diagnosis, all of these patients underwent surgical procedure and histopathological diagnosis and finally 31.6 % patients were diagnosed as having inflammatory polyp, 19.7% malignant mass, 21.1% fungal infection, 10.5% nasopharyngeal angiofibroma, and 17.1% benign cyst. In Rupa series out of 33 patients 33.0% had sinonasal polyp, 9% fungal infection, 24.24% angiofibroma, 3% haemangioma and 27.27% malignant mass.<sup>10</sup> These findings were evaluated by CT scan. After histopathology 30.3% patients were diagnosed as polyp, 12.12% fungal infection, 21.21% malignant mass, 27.27% angiofibroma, 6% haemangioma and 3% meningioma.

Out of all cases 10 were diagnosed as having fungal infection/mass by CT scan and confirmed by histopathological evaluation. Two cases were diagnosed as having fungal infection/mass by CT scan but not confirmed by histopathological findings. Of 64 cases of other than fungal infection/mass, which were diagnosed by CT scan, six were confirmed as having fungal infection/mass and 58 were other than having fungal infection/mass by histopathology. Sensitivity of CT scan to diagnose fungal infection/mass was 62.5%, specificity 96.7%, positive predictive value 83.3%, negative predictive value 90.6% and accuracy 89.5%. Fungal diseases of the paranasal sinuses appears to be relatively rare in occurrence, but there is a growing incidence of them in accordance with the increasing use of antibiotic, steroid hormones, anticancer drugs, and radiation therapy. Kwon et al have seen 15 cases of aspergillosis of the paranasal sinuses in which computed tomography (CT) was helpful for diagnosis.<sup>12</sup> The characteristics feature of CT findings was the intermixture of high and low density areas in the affected paranasal sinuses, apparently caused by increased X-ray absorption due to calcification. These findings indicate that CT is useful in the diagnosis of fungal diseases in the paranasal sinuses.

#### **Conclusion:**

In conclusion, CT scan of the fungal diseases in paranasal sinus provides more information and better

image quality and CT diagnosis correlate well with the findings of histopathology. MRI could be added as an additional imaging modality in solvent patients and comparing its diagnostic accuracy with clinical findings of CT scan.

### References:

1. Zinreich JS, Kennedy DW, Rosenbaum AE, Gayler BW, Kumar AJ, Stammberger H. Paranasal sinuses: CT imaging requirements for endoscopic surgery. *Radiology* 2007;163: 769-75.
2. Abayomi OK, Bankoff MS. Computerized tomographic evaluation of tumors of the nasopharynx and maxillary sinus: potential impact on results of treatment. *Journal of the National Medical Association* 2006;78(4): 311-16.
3. Bhattacharyya N, Fried MP. The accuracy of computed tomography in the diagnosis of chronic rhinosinusitis. *Laryngoscope* 2003;113(1): 125-29.
4. Reider-Grosswasser I, Solomon A, Zikk D, Godel V. Computerized tomography in conditions concomitantly involving the orbits and the paranasal sinuses. *Computerized Radiology* 2006;10(2-3): 119-126.
5. Som PM, Shapiro MD, Biller HF, et al. Sinonasal tumors and inflammatory tissues: Differentiation with MR. *Radiology* 2008;167: 803-808.
6. Bilaniuk LT, Zimmerman RA. Computed tomography in evaluation of the paranasal sinuses. *Radiol Clin North Am* 2002;20: 51-66.
7. Duvoisin B, Landry M, Chapuis L, Krayenbuhl M, Schnyder P. Low-dose CT and inflammatory disease of the paranasal sinuses. *Neuroradiology* 2001;33( 5): 403-406.
8. Cagici CA, Cakmak O, Hurcan C, Tercan F. Three-slice computerized tomography for the diagnosis and follow-up of rhinosinusitis. *European Archives of Oto-Rhino-Laryngology* 2005;262(9): 744-50.
9. Parsons C, Hodson N. Computed tomography of paranasal sinus tumors. *Radiology* 2009;132(3): 641-5.
10. Rupa LT, Zimmerman RA. Computed tomography in evaluation of the paranasal sinuses. *Radiol Clin North Am* 2002;20: 51-66.
11. Swamy KV, Gowda BVC. A clinical study of benign tumours of nose and paranasal sinuses. *Indiana Journal of Otolaryngology and Head and Neck Surgery* 2004;56(4).
12. Kwon J, Park KH, Park SI, Jin SY. Aspergillosis of the paranasal sinuses-Diagnostic significance of the computed tomography. *Yonsel Medical Journal* 2009; 30(3): 194-7.