

Clinicopathological Profile of Wilms' Tumour in Children

M MAZUMDER^a, A ISLAM^b, N FAROOQ^c, M ZAMAN^d

Summary:

Introduction: Wilms' tumor is the most common primary malignant renal tumor of childhood. It is important to pick up the children with wilms' tumor earlier as early stages has excellent outcomes after treatment.

Objective : To find out the common clinical presentations and pathological profile of Wilms' tumor in children.

Methods and Materials : A hospital based prospective study done with twenty diagnosed patients of Wilms tumour enrolled from department of Pediatric haemato-oncology, BSMMU, Dhaka in the period between January to December 2008.

Results- The peak incidence of Wilms' tumor was in 1 to 5 years age group (80%,n=16). Median age at presentation was 49 months with male: female ratio 1.8:1. The most common presentation was abdominal swelling (80%,n=16), followed by flank mass (75%,n=15), abdominal pain (55%,n=11),

haematuria (15%,n=3), hypertension (10%,n=2). Thirteen raised from right kidney, ratio of right to left involvement 1.8:1. Histologically 13(65%) patients had triphasic histology having blastemal, stromal and epithelial elements, 7(35%) was biphasic having blastema and epithelia. All had favourable histological pattern. Most patients presented in stage III (55%,n=11) followed by stage II (25%,n=5), Stage IV(10%,n=2), Stage I(10%,n=2). No bilateral presentation.

Conclusions : Most of the patients of Wilms' tumor presented within 1 to 5 years of age(80%) with abdominal distension(80%) and flank mass(75%), few associated with haematuria(15%) and hypertension(10%). Histologically all were favourable and maximum presented in stage III(55%) followed by stage II(25%).

Keywords: Clinicopathological profile, Histological pattern, Wilms' tumour.

(J Bangladesh Coll Phys Surg 2014; 32: 5-8)

Introduction:

In 1899 surgeon Max Wilms (1867-1918) described seven children suffering from nephroblastoma in a monograph of 'mixed tumors'. It is now recognized that Wilms' tumor accounts for approximately 6% of pediatric cancers and is the second most common malignant abdominal tumor in childhood.¹ With multimodality treatment and recent advancement it has

become one of the curable tumor.² With the introduction of adjuvant chemotherapy and sometimes radiotherapy, survival rates approaching 90% were achieved for localized tumor by 1970s.³

Wilms' tumor is a mixed embryonal neoplasm composed of three elements – blastema, epithelia and stroma. It may arise in one or both kidneys; the incidence of bilateral Wilms' tumor is 6%. It may be associated with hemihypertrophy, aniridia and genitourinary anomalies, including hypospadias and cryptorchidism, some syndromes eg. WAGR or Denys-Drash syndromes.¹ The incidence of wilms' tumor is approximately 8 cases per million children <15 yrs of age.¹ It usually occurs in children between 2-5 yrs of age. The tumor presents at an earlier age among boys, with the mean age at diagnosis for those with unilateral disease being 41.5 months compared with 46.9 months among girls.⁴ The median age is highest for patients with unilateral unicentric disease (36.1 mon) and lowest for those with synchronous bilateral Wilms' tumors (25.5 mon).⁵ Wilms' tumor usually presents as an abdominal mass often noticed by the parents during bathing or dressing. The mass is usually smooth, firm, of variable size and

- Dr. Monika Mazumder, Registrar (Neonatology), Department of Paediatrics, Rangpur Medical College Hospital, Rangpur.
- Prof. Afiquel Islam, Chairman, Department of Pediatric Haemato-oncology, Bangabandhu Sheikh Mujib Medical University (BSMMU), Dhaka.
- Dr. Nusrat Farooq, Registrar (Neonatology), Apollo Hospital, Dhaka.
- Dr. Mahmuda Zaman, Registrar (paediatrics), Apollo Hospital, Dhaka.

Address of Correspondence: Dr. Monika Mazumder, Registrar (Neonatology) Department of Paediatrics, Rangpur Medical College Hospital Rangpur, Mobile: 01920703009, 01711134991, E-mail: monikamaz26@yahoo.com / monika.bd@in.com,

Received: 5 January, 2013

Accepted: 31 December, 2013

occasionally may cross midline. Abdominal pain in about 30%- 40% cases, vomiting, constipation, haematuria(12–25%), hypertension (3- 25%), pallor, signs of Wilms' tumor associated syndromes eg. aniridia, facial dysmorphism, partial or complete hemihypertrophy, hypospadias, cryptorchidism, pseudohermaphroditism.^{1, 6} Wilms'tumor (hereditary or sporadic) appears to result from changes in one or more of at least ten genes. The *WT1*, *WT2*, *p53*.^{4,7} Favorable histology (90%) having blastema, stroma, epithelia without any anaplastic features has cure rate close to 90%. Unfavourable histology (10%) is characterized by the presence of anaplasia.¹ There is no statistical record on incidence of Wilms Tumour in Bangladesh, though a number of cases are found in different hospitals each year. In a survey of surgical problems in children in Dhaka Shishu Hospital from 1981 to 1990, it was found that out of 12189 patients, 228 patients (about 2%) were diagnosed as Wilms' Tumour.⁸ Another study found that out of 90 cases of malignancy, 22% was nephroblastoma during the four year study period.⁹

Development of surgical techniques, sensitivity to radiation and availability of several active chemotherapeutic agents led to a dramatic change in prognosis for most patients with this once lethal malignancy. So the findings of this study could help the health professionals in early diagnosis of Wilms' tumor and offer the patients the best options of treatment that brings in much better outcome.

Methods and materials:

A hospital based prospective study done with twenty diagnosed patients of Wilms tumour enrolled from department of Pediatric Haemato-oncology, Bangabandhu Sheikh Mujib Medical University (BSMMU), Dhaka in the period between January to December 2008. Age below 15 years and diagnosed case of Wilms' tumor as suggested by history, clinical examinations with or without imaging was included. Age over 15 years and renal mass due to other cause was excluded. Objective was to find out the common clinical presentations and pathological profile of Wilms' tumor in children. During the study period total 23 patients were enrolled. Among them, 2 cases were neuroblastoma and 1 case was renal cell carcinoma as diagnosed later by histopathology.

Results:

In this study 20 patients were enrolled and the findings are subsequently presented in tables and figures.

Table-I

Age distribution of study patients.

	Age in months		Age in years		Median age (months)
	0 - 12	13 - 24	25 - 60	5 - 10	
No of patients	1	3	12	2	2
percentage	5%	15%	60%	10%	10%

Table 1 shows age distribution of study patients. Median age was 49 months. 16 (80%) presented within 5 yrs of age and 12 (60%) presented between 25–60 months of age.

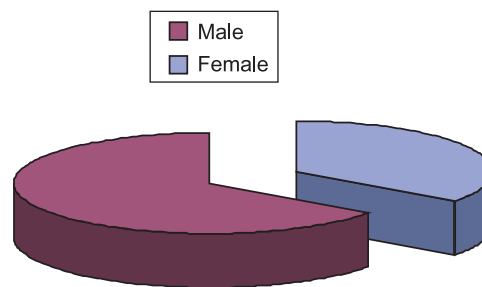


Fig-1: Sex distribution of study patients (n=20).

Fig.-1: The pie chart shows sex distribution of study patients. 13(65%) patients were male, 7(35%) patient were female. Male : Female =1.8:1.

Table-II

Clinical presentation of study patients(n=20).

Clinical presentation	No. Of patients	Percentage (%)
Abdominal swelling	16	80%
Flank mass	15	75%
Abdominal pain	11	55%
constipation	8	40%
Vomiting	6	30%
Pallor	4	20%
Haematuria	3	15%
Hypertension	2	10%

Table 2 showing distribution of percentage of presenting features in study group. The most common presentation was abdominal swelling (80%, n=16) followed by flank mass(75%, n=15), abdominal pain(55%, n=11), haematuria(15%, n=3), hypertension(10%, n=2).

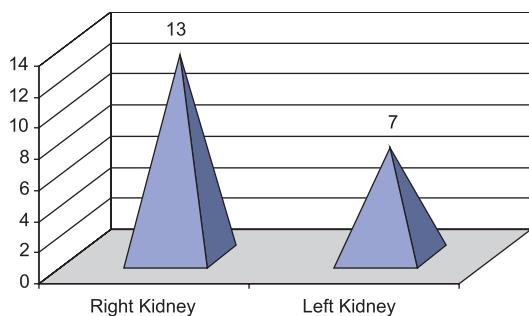


Fig.-2: Site of origin of Wilms' tumor.

Bar diagram showing origin of Wilms tumor by ultrasonography. Thirteen (65%) raised from right kidney, 7(35%) from left kidney. There was no bilateral tumor. R:L = 1.8 : 1.

Table-III

Biopsy and Histopathology findings (n= 20).

Histology	No. of patients	%
<i>Blastemal cells</i> (Small rounded cells scanty blue cytoplasm, hyperchromatic nuclei)	20	100%
<i>Epithelial cells</i> (forming tubules, cords, rosette)	16	80%
Stromal elements	13	65%
Necrosis	6	30%

Table-3 showing all patients had blastemal cells, 16(80%) patients had epithelial cells and 13(65%) patients had stromal elements in histopathology. Necrosis was found in 4(20%) patients. None had anaplasia.

Bar diagram showing 11(55%) was in stage III, 5(25%) in stage II, stage I and stage IV was 2(10%) each.

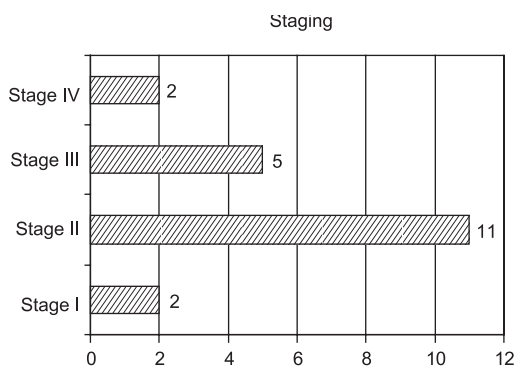


Fig.-3 : Staging of Wilms tumor in study patients(n=20).

Discussion:

Wilms' tumor is the commonest primary renal neoplasm in children. Most children have non specific symptoms in early disease course. So the tumor is often missed unless there is high suspicion and good abdominal examination in early stage. It is important to pick up the children with wilms' tumor earlier as early stages have excellent outcomes after treatment.

This study is a simple prospective study reflecting the mode of clinical presentation and histopathological pattern in patients of Wilms' tumor in children under 15 years. The study was carried out in the department of Pediatric Haemato oncology, BSMMU, from January to December 2008.

Twenty three cases were enrolled primarily. History taking included history of consanguinity, family history, and onset of the disease, complaining symptoms, presence of congenital anomalies and the method of surgical interference like FNAC. Clinical examination included examination of any congenital anomalies as aniridia, genitourinary malformations, hemi-hypertrophy or signs of overgrowth and hypertension. Radiological examination included chest X-ray (CXR), abdomen-pelvic ultrasonography and CT scan for confirming the origin and any residual or metastatic disease. Laboratory examination included complete blood picture (CBC), urinalysis, renal and liver profiles, and diagnosis was confirmed by biopsy and histopathology. Among the 23 cases 2 cases were neuroblastoma and 1 case was renal cell carcinoma as diagnosed later by histopathology. So twenty patients were finally diagnosed as Wilms' tumor.

Among the twenty (20) cases of Wilms tumor 16 (80%) presented below 5 years of age and 12 (60%) was within 25 – 60 months with male: female= 1.8:1. Median age at presentation was 49 months. The results of the study almost corroborate with the study by Paul et al, who found 90% presented in <6 years and 66.7% in <3 years with a Male: Female= 2.1:1.¹⁰ The study of Hisham et al, 2005 showed the male : female ratio 1.5 :1.¹¹

Major clinical presentations were abdominal swelling (80%, n=16), flank mass (75%, n=15), abdominal pain (55%, n=11), constipation (40%, n=8), vomiting (30%, n=6). Few patients had haematuria (15%, n=3), hypertension (10%, n=2). Some patient also presented with gradual pallor. None of them had syndromes or any congenital anomaly. In the study of Hisham et al, the most common complaint was abdominal swelling (82.3%), followed by haematuria (14.5%), then abdominal pain (13%).¹¹ The work of Pianezza et al,

where an abdominal mass was the most common presenting feature (85%), followed by abdominal pain (17%), and then haematuria (10%).¹² Both studies almost corroborate with the findings of present study in term of clinical presentation.

Of the 20 cases 65% (n=13) was originated from right kidney and 35%(n=7) from left kidney, Right: Left = 1.8:1. This corroborates with the study of K Basu et al, as they found right kidney involved in 63% cases and left kidney 37% cases.¹³ There was no bilateral tumor. But in the study of Sharma et al they found left kidney involvement in 60% cases and Hung IJ et al found 55.8% right kidney and 38.2% left kidney, 6.8% bilateral involvement.¹⁴ The work of Pianezza et al, also reported 4.8% cases as bilateral Wilms' tumor.¹²

Histological results showed triphasic(having blastema, epithelia, stroma) histology in 65%(n=13) cases, biphasic (blastema and epithelia) in 35%(n=7) cases. None had anaplastic or monophasic histology. So all cases (100%) were of favourable type according to prognostic consideration. This findings corroborates with the study of Basu et al.¹³ But the study of Quijano and Drut found blastemal cells in all cases but stromal cells in 90% cases and epithelial cells in only 40% cases.¹⁵ Hung IJ et al found 85.3% favourable histology and also Hisham et al reported 65.4% favourable histology.^{11, 14} These two studies does not corroborate with present study.

According to National Wilms' Tumor Study Group (NWTSG) patients were divided into 5 stages. In this study most patients presented in stage III (55%, n=11), followed by stage II (25%, n=5), and 10% (n=2) each in stage I and IV. No one was in stage V. This is comparable with the study of K Basu et al where they found 68% cases in stage III followed by 21% stage II and 10.5% stage IV.¹⁰ But Hung IJ et al found 43.2% in stage I, 23% stage III, 19.3% stage II and 6.8% each in stage IV and V. In the study of Hisham et al, 22 patients (35.5%) had stage I disease, 17 cases (27.4%) had stage II, 16 cases (25.8%) had Stage III, 4 cases (6.5%) had stage IV and 3 cases (4.8%) had stage V disease.¹¹ To describe clinicopathological profile of Wilms' tumor, a study period of one year may not reflect the real situation. As per consequence sample size was also small. An extended period follow up study may reveal the actual situation and clinicopathological correlation with outcome in patients with Wilms' tumor. So this study raises the need for more large scale work.

Conclusion:

Most of the patients of Wilms' tumor presented within 1 to 5 years of age(80%)with abdominal distension

(80%) and flank mass(75%), few associated with haematuria(15%) and hypertension(10%). Histologically all were favourable and most presented in stage III(55%) followed by stage II (25%). So the patients of Wilms' tumor presents mostly in later stages. Data obtained from this study may lead to early detection due to early clinical suspicion and thus further improvement in prognosis of paediatric malignant solid tumor in our country.

References:

1. Norman J, Vicki H, Neoplasms of kidney, Nelson's textbook of paediatrics, 18th ed, WB Saunders Co, 2008; 2140-2143.
2. Metzger ML, Dome JS, Current therapy for Wilms' tumor, The Oncologist 2005 ;10 : 815-826.
3. Kathy p jones, Nephrectomy only for Wilms' Tumor ; negotiating the tangled web requires multi-professional input, paediatric blood cancer 2010;45:865 – 866.
4. Dome JS, Pearlman EJ et al, Renal tumors, Principles and Practice of pediatric oncology by PA Pizzo, 5th ed, Lippincot Williams & Wilkins 2006 ; 905-928.
5. Breslow N, Olshan A, Beckwith JB, Green DM. Epidemiology of Wilms tumor. *Med Pediatr Oncol.* 1993; 21:172-81.
6. Copps MJ, Paulino AC, Wilms' Tumor - overview , eMedicine specialties, Pediatrics, Oncology, Mar 2009, available at <http://emedicine.medscape.com/article/989398-overview>.
7. Royer-Pokora B, Weirich A, Schumacher V, et al.: Clinical relevance of mutations in the Wilms tumor suppressor 1 gene WT1 and the cadherin-associated protein beta1 gene CTNBN1 for patients with Wilms tumors: results of long-term surveillance of 71 patients from International Society of Pediatric Oncology Study 9/Society for Pediatric Oncology 2008; 113: 1080-9.
8. Masood AFM, Khan AR, Islam MK, Surgical problems in child. 10 years survey in DSH; DSH journal, 1991;7:45.
9. Khan WA. Malignant tumor in children, A Histopathological study. DSH journal, 1991;7:30.
10. Paul L, Thaver D, Muzaffar S et al, Clinicopathological profile of Wilms' tumor in children. *Indian J Pediatrics*, 2000; 67:765-767.
11. Hisham H, Abdel All, Emdad E Habib et al. Wilms' Tumor: The Experience of the pediatric unite of Kasr El-Aini centre of radiation oncology and nuclear medicine(NEMROCK), *Journal of the Egyptian Nat.cancer Inst.* 2005 ; 4 :308-314.
12. Pianezza ML, Rubin S, Bass J, Chou S, Pike JG, Leonard MP. Wilms' tumor at the Children's Hospital of Eastern Ontario. *Can J Urol.* 2004, 11: 2151-6.
13. Basu K, Das S et al,). Role of FNAC in Wilms' Tumor- an interim report, *J assoc pediatr* , 2001; 6 : 130-133.
14. Hung IJ, Yang CP et al, Epidemiology, clinical feature and treatment outcome of Wilms' Tumor in Taiwan: a report from Taiwan pediatric oncology group. *J Formos Med Assoc*, 2004;103:104-11.
15. Quijano G, Drut R. Cytologic characteristics of Wilms' tumor in fine needle aspirates. A study of ten cases. *Acta Cytol* 1989; 37:477-482.