

## Early outcome of “Modified Uncut Roux-En-Y” Technique in Gastric Reconstruction Surgery

ABMM RAHMAN<sup>a</sup>, T ALAM<sup>b</sup>, AHMS ALAM<sup>c</sup>, AKMMU BHUIYAN<sup>d</sup>, MS HOSSAIN<sup>e</sup>, MA RANA<sup>f</sup>

### Summary:

*Loop gastro-Jejunostomy and Roux-en-Y gastro-Jejunostomy, the commonest reconstructions in gastric surgery, are significantly associated with alkaline reflux gastritis and Roux stasis syndrome (RSS) respectively. The Modified Uncut Roux-en-Y (MUREY) technique could be an effective technique in preventing both the conditions.*

*This prospective observational study was designed to evaluate the effectiveness of Modified UREY reconstruction to prevent RSS and Alkaline reflux gastro-esophagitis while avoiding “Staple- line dehiscence”. A total of 47 patients of gastric outlet obstruction, both benign and malignant, undergoing Modified Uncut Roux-en-Y reconstruction with/without Gastrectomy at BMCH over the span of July 2014 to July 2016, were incorporated in this study. Patients were followed up from the immediate post-operative periods till discharge and postoperatively for 2 months.*

*There was no incidence of bile reflux or bilious vomiting in the follow-up period. There were two (4.3%) incidences*

*of RSS among the 47 patients ( $P < 0.001$ ). Postoperative endoscopy was carried out in 9 patients to assess the integrity of staple line occlusion which revealed normal looking mucosa of upper GIT with an intact staple line occlusion. There was significant decrease in the average Visick score, from  $3.5 \pm 0.6$  (SD) preoperatively to  $1.2 \pm 0.4$  (SD) in the post-operative period. Average increase in the body weight at the time of final follow-up was  $6.7\% \pm 5.1$  kg.*

*The Modified “Uncut Roux-En-Y” reconstruction technique is both feasible and safe. It is effective in preventing RSS and alkaline reflux gastritis while preventing Staple-line dehiscence and, can be a preferred technique of gastric bypass.*

**Keywords:** Modified Uncut Roux-en-Y (MUREY), Roux Stasis Syndrome (RSS), Biliary reflux.

(*J Bangladesh Coll Phys Surg 2018; 36: 139-144*)

DOI: <http://dx.doi.org/10.3329/jbeps.v36i4.36085>

### Introduction:

Loop gastro-jejunostomy with or without partial gastrectomy is inherently associated with bile reflux

- Dr. A.B.M. Mahbubur Rahman, Assistant Professor, Department of Surgery Bangladesh Medical College Hospital
- Dr. Tamjeed Alam, Junior Consultant, Department of Surgery, Bangladesh Medical College Hospital
- Prof AHM Shamsul Alam, Professor and Head, Department of Surgery, Bangladesh Medical College
- Dr. A.K.M. Minhaj Uddin Bhuiyan, Assistant Professor, Department of Surgical Oncology, National Institute of Cancer Research & Hospital
- Dr. Md. Shamim Hossain, Assistant Professor of Urology, Bangabandhu Sheikh Mujib Medical University
- Dr. Mushtaque Ahmad Rana, Associate Professor of Gastroenterology Bangladesh Medical College Hospital

**Address of Correspondence:** Dr. A B M Mahbubur Rahman, Assistant Professor, Department of Surgery, Bangladesh Medical College Hospital, House 33-35, Road- 14/A (old-25), Dhanmondi, Dhaka-1209, Email: mahbubur.rahman07@yahoo.com, Tel: +88 01712 911326.

**Received:** 9 August, 2017

**Accepted:** 25 June, 2018

gastritis, leading to an unacceptably higher incidence of post-operative recovery period. Roux-en-Y reconstruction, on the other hand, primarily designed for bile reflux prevention, poses another problem on itself, the roux stasis syndrome (RSS)<sup>1</sup>. Conceptualizing the basic principle of conventional REY, the “Uncut Roux-en-Y” reconstruction can prevent alkaline reflux following gastro-jejunostomy by occluding the afferent jejunal loop adjacent to the G-J stoma, hence called the “Uncut Roux en Y (UREY)” procedure (Fig 1)<sup>1</sup>. In addition, it can avoid RSS that accompanies the standard REY procedure<sup>2-9</sup>, as anatomical continuity of jejunum is preserved. Other international publications, however, showcased incidences of staple line dehiscence<sup>10,11</sup>, put the objectives of the procedure into question. To prevent staple-line dehiscence, a series of interrupted non-absorbable sero-muscular sutures over the staple line is now advocated, called the “Modified Uncut Roux-en-Y “(MUREY) procedure<sup>11</sup>. The purpose of our study

was, therefore, to evaluate the early clinical outcome of this modified technique and effectiveness of the procedure in alleviating the reflux induced GI symptoms and patients convalescence following the MUREY procedure.

#### Materials and Method:

Clinical data of 47 cases, 40 malignant and 7 benign cases undergoing Modified Uncut Roux-en-Y gastric bypass with or without gastrectomy with follow-up data from January 2014 to July 2016 was purposefully incorporated in this study. Patients underwent total gastrectomy, non-resectable gastric malignancy, recurrent gastric carcinoma, h/o previous gastric surgery were excluded from the study. Observations were made during immediate post-operative periods till discharge and subsequent monthly follow-up for 2 months in the OPD and over telephone regarding the nature of nasogastric aspirates, presence or absence of bilious vomiting, amount and quality of food intake, post-prandial symptoms and weight gain. Status of the overall quality of life was assessed using the "Visick" grade<sup>12</sup>. Postoperative endoscopy was carried out in 9 patients to assess the integrity of staple line closure and in search of the evidence of reflux biliary gastro-esophagitis.

#### Modified Visick grade

- Grade 1 - No symptoms, perfect result
- Grade 2 - Patient states that results are perfect, but symptoms can be elicited
- Grade 3 - Mild to moderate symptoms, patient and surgeon satisfied with the result
- Grade 4 - Mild to moderate symptoms, patient and surgeon dissatisfied

#### Operative Technique:

The procedures were performed under G/A. For gastric carcinoma, sub-total gastrectomy and loop gastro-jejunosomy with standard D1+/D2 lymphadenectomy were done. Whereas, laparoscopy assisted bilateral truncal vagotomy and loop gastro-jejunosomy were done for benign gastric outlet obstruction.

For the "Uncut" part of the procedure, jejunal lumen was occluded 25-45 cm distal to the ligament of Treitz using a single, double-row non-cutting linear GI stapler (Fig 2). The staple line was then reinforced by interrupted seromuscular sutures with 3/0 silk to prevent staple line dehiscence (Fig 3). Gastro-jejunosomy was constructed

5 cm distal to the jejunal occlusion site. Approximately 20-30 cm distal to the anastomosis, on the efferent limb, a "Braun" side to side jejuno-jejunosomy was created with the afferent limb for diverting duodenal fluids (Fig 4). This anastomosis corresponds to a site 10-20 cm distal to the ligament of Treitz on the proximal jejunum (afferent limb).

For laparoscopy assisted procedure, bilateral truncal vagotomy and gastro-jejunosomy was carried out using a 10mm supra-umbilical camera port and two working ports of 10mm and 5mm in diameter, placed right lateral to the camera port in mid-clavicular and anterior axillary line respectively. An additional 5mm port was used in epigastrium for liver retraction. The "Modified Uncut" portion of the procedure was carried out extra corporeally, by enlarging the supra-umbilical port to the left of the patient.

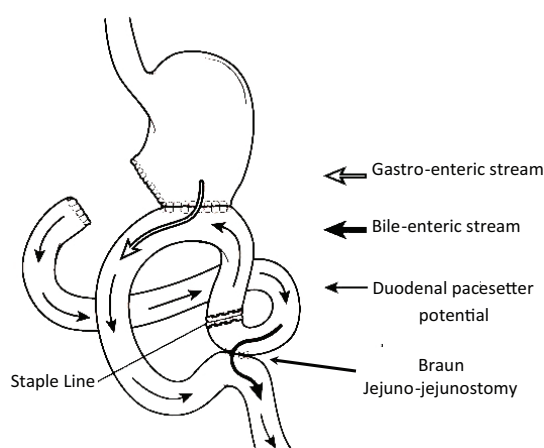


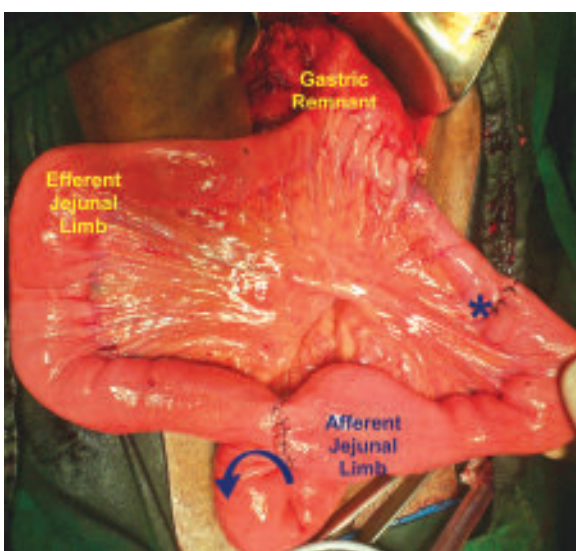
Fig-1: The Uncut Roux-en-Y Gastro-jejunosomy

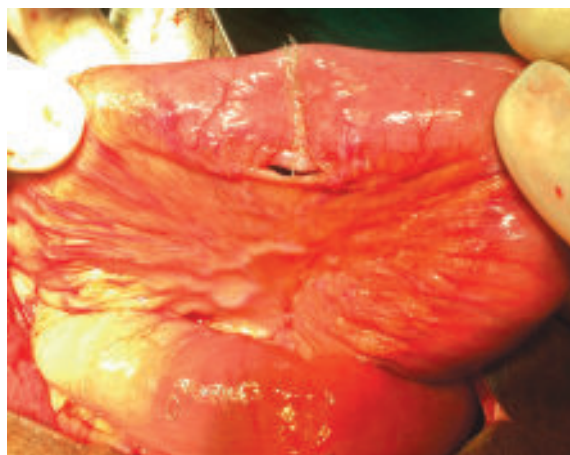
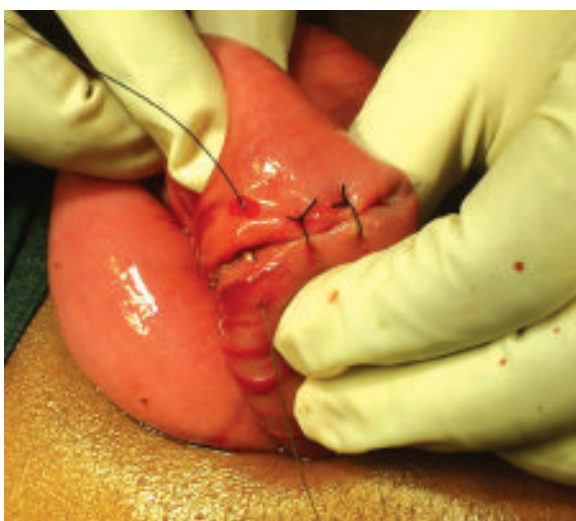
Fig-2: Double row of staples fired to occlude the Afferent limb



**Fig.-3:** Seromuscular sutures to reinforce the staple line (MUREY)

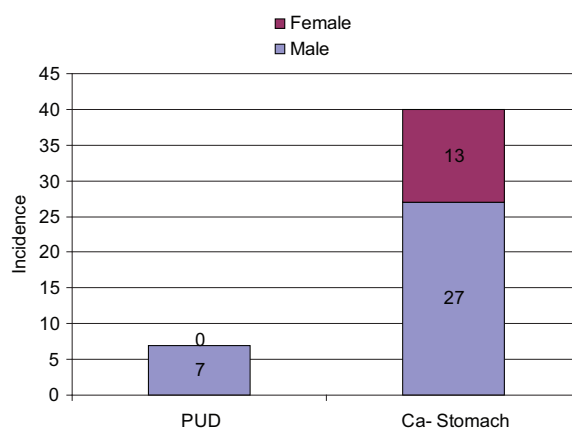


**Fig.-4:** The completed Modified “Uncut” Roux-en-Y procedure.

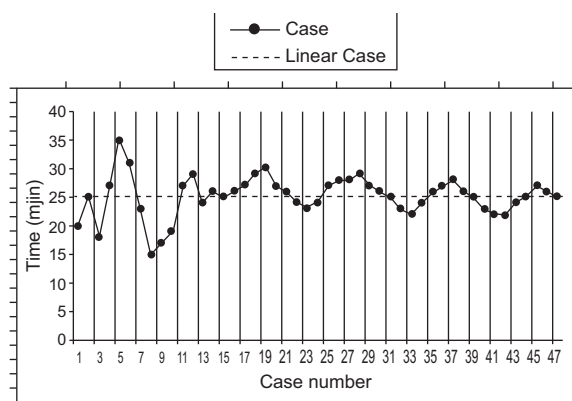
**Results:**

47 patients, 13 female and 34 male, aged between 35 to 66 years, average being  $51.2 \pm 10.12$  years (Mean age  $\pm$ SD) received modified uncut Roux En Y gastric bypass, analyzed in this study. Among them, 40 patients had carcinoma stomach and the rest had gastric outlet obstruction from chronic PUD (Fig 5). The average time taken to perform the “Modified Uncut Roux – En- Y” component of the procedure was  $24 \pm 4.7$  minutes (Mean $\pm$ SD) (Fig 6). The duration of the

MUREY component of the procedure was recorded, starting after completion of gastro-jejunostomy to the completion of both jejun- jejunostomy and the jejunal occlusion. The average post-operative hospital stay was  $9.3 \pm 3.4$  days (Mean $\pm$ SD). The minimum postoperative stay was 5 days while the maximum stay being for a period of 20 days. The Superficial wound infection occurred in 3 patients which resolved with regular dressing. One patient developed burst abdomen which was repaired under general anesthesia. Paralytic ileus was seen in two patients, settled with conservative management. As per clinical criteria, there was two (4.3%) incidences of Roux Stasis Syndrome (RSS) among the 47 patients after the 8 weeks follow-up period ( $p < 0.005$ ) (Table 1). There were one hundred and seventy four (174) symptoms preoperatively among the 47 patients with an average of  $3.9 \pm 0.5$



**Fig.-5:** Sex distribution of the indications for surgery



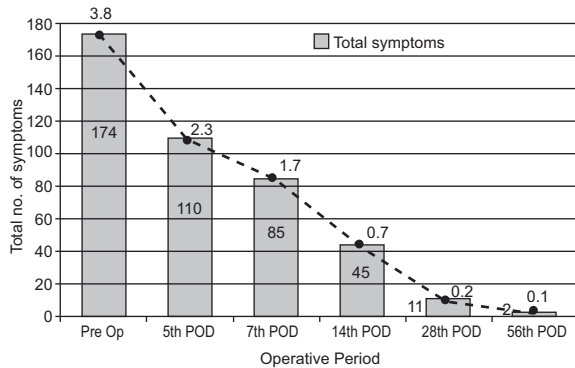
**Fig.-6:** Operative time for performing the Modified Uncut Roux-en-Y part of the procedures

**Table-I**

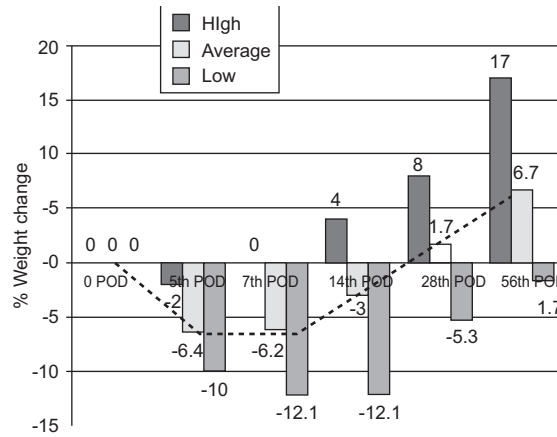
*Incidence of Post-operative Complications (n=47)*

Complication	Frequency	Percentage (%)
Burst Abdomen	2	4.3
Superficial Wound Infection	3	6.4
Bile Reflux	0	0.0
Roux Stasis Syndrome	2	4.3
Anastomotic Leakage	0	0.0
Staple Line Dehiscence	0	0.0
Duodenal Stump Leakage	0	0.0
Persistent Pain	1	2.1
Paralytic Ileus	2	4.3
Death	0	0.0

(mean±SD) symptoms per patients. At the time of final follow-up, only two patients (4.3%) complained of post-prandial pain, with an average being, 0.1±0.2 (mean±SD) symptoms per patient after 8 weeks (Fig 7). There was no incidence of bile reflux, anastomotic leakage and duodenal blow-out. Post-operative endoscopy was carried out in 9(19.14%) patients which revealed integrated staple line occlusion at the afferent jejunal loop with no evidence of biliary reflux in the stomach or its remnants. The average preoperative weight of the patient was 53.6kg±5.9 (mean+SD), dropped by 6.4%±2.8(mean+SD) by the 5<sup>th</sup> postoperative day. The average time taken to regain the lost weight was about 3 weeks. The percentage increase in body weight, on average, at final follow up was 6.7%±5.1 (mean+SD) (Fig 8). The study also showed a significant decrease in the average Visick Score

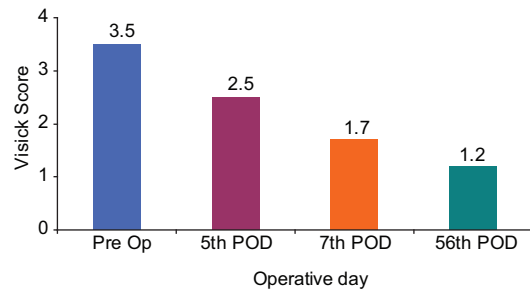


**Fig-7:** Frequency of Roux Stasis Syndrome in the pre and post-operative periods



**Fig-8:** Average post-operative change in weight expressed as a percentage of the pre-operative weight

postoperatively (p<0.0001), depicting significant increase in the overall quality of life. The average preoperative Visick Score was 3.5±0.6 (mean+SD), which improved postoperatively to 1.2±0.4 (mean+SD) by the time of final follow up after 8 weeks (Fig 9). There was no mortality in the study period (Table 1).



**Fig-9:** Average Visick Score in the preoperative and postoperative period.

**Discussion:**

The Roux-En-Y (REY) procedure has gained the broadest acceptance as the method of choice for upper GIT reconstruction mainly due to its perceived ability to prevent bile reflux into stomach/ esophagus. However, even longer segments of over 40cm of jejunal limb, as commonly practiced, is unable to completely prevent bile reflux induced gastro-oesophagitis<sup>1</sup>. Investigations like cholangioscintigraphy, confirmed and documented a 40% incidence of the retrograde flow of jejunal contents in the Roux loop<sup>2</sup>. In another study of 16 patients, with a mean roux limb length of 39.8 cm, who

underwent alimentary limb lengthening procedure for intractable bile reflux, responded favorably to limb lengthening to 100 cm<sup>3</sup>.

On the contrary, greater length of the Roux limb predisposes to the development of Roux stasis syndrome, a symptom complex, first coined by Mathias and colleagues followed by a Roux-en-Y bypass<sup>4</sup>. The overall incidence of RSS is 30% as per international literature published<sup>5</sup>.

Patho-physiology of RSS is variable. Experimental studies have accused a disrupted migratory motor complex (MMC) for the wrongdoing<sup>4,6</sup>. One observational study of 187 patients following Roux en Y bypass with a mean alimentary length of 41 cm, documented a 26.2% incidence of RSS in their study group, concluded that construction of roux limb greater than 40 cm in length may increase the incidence of RSS<sup>7</sup>.

The MURY reconstruction, pioneered by VanStiegman<sup>8</sup>, showed its potential in preventing RSS as small bowel escapes transection and myo-neural continuity is maintained. Results of an experimental study on canine model to analyze the effects of UREY and standard REY procedure on intestinal motility and gastric emptying, confirmed that the UREY procedure preserved normal gastric emptying and prevented the development of Roux stasis syndrome<sup>9</sup>. Another observational study of 15 patients underwent UREY gastrectomy with a 6 months follow-up period, showed excellent results with stable weight gain in 57% of patients<sup>10</sup>. RSS developed in one patient (7.1%) in this time span. 36% of the study population, however, experienced pain with reflux biliary gastro-esophagitis from staple line disruption. They concluded that the UREY procedure prevents RSS but is associated with an unacceptably high incidence of staple failure.

In our series, based on clinical criteria, there was two (4.3%) incidences of RSS after 8 weeks of follow-up ( $p < 0.001$ ). Initially, the incidence of any of the four clinical post-prandial symptoms of RSS among the patients was recorded preoperatively. There were a lot of symptoms preoperatively among the 47 patients, with an average of  $3.8 \pm 0.4$  (mean  $\pm$  SD) symptoms per patients. At the time of final follow-up, only two (2) patients complained of post-prandial pain, with the average being,  $0.1 \pm 0.2$  (mean  $\pm$  SD) symptoms per patient after 8 weeks (Fig 7).

Furthermore, our study shows 0% incidence of bilious vomiting following the “Modified Uncut” technique in this follow-up period. This finding was universal, except in the early studies where there was a high incidence of staple line dehiscence<sup>10</sup>. An extra layer of non-absorbable interrupted seromuscular sutures have been advocated to reinforce the staple line, hence called “Modified Uncut Roux -en-Y” (MUREY) procedure<sup>11</sup> (Fig 3). We randomly carried out endoscopic evaluation in 9 patients within 56<sup>th</sup> week of follow-up which revealed no staple line dehiscence in any of the patients examined suggested the possibility that MUREY technique reduces the dehiscence of enterically closed portion.

Our study also showed a significant increase in the body weight after MUREY procedure. On average, pre-operative body weight of our study population was 53.6 kg  $\pm$  5.9 SD. The average increase of body weight at the final follow up was  $6.7\% \pm 5.1$  SD (Fig 8).

The outcome of surgery in patients’ perspective can be assessed by using quality of life (QoL) indicator. Based on questionnaires, various scoring systems have been developed. The Visick scoring system<sup>12</sup>, in particular, correlates well to the heart burn and reflux related symptoms has been used to evaluate a patient appreciation of anti-reflux surgery (Fig 9).

Mon and Cullen<sup>13</sup> reviewed a matched cohort of patients undergoing the Uncut and standard REY gastro-jejunosotomy. Their cohort included cases of gastroparesis, gastric adenocarcinoma, bile reflux gastritis and peptic ulcer with gastric outlet obstruction. They compared the clinical results on Visick Grades and calculated the score. They found that patients undergoing UREY procedure showed significantly improved quality of life on Visick Grades in comparison with the standard Roux group, which showed little improvement. Their study also demonstrated that the UREY gastro-jejunosotomy can be performed safely in patients who would traditionally undergo a standard Roux-en-Y reconstruction for a variety of disorders.

Our study showed a very significant decrease in the average Visick score postoperatively ( $p < 0.001$ ) testifies the improvement in the QoL. The average preoperative Visick Score was  $3.5 \pm 0.6$  (SD), which improved postoperatively to  $1.2 \pm 0.4$  (SD) after 8 weeks of follow up (Fig 9).

In general, the Roux limb of the REY reconstruction acts as a functional obstruction resulting from transaction of jejunum and separation of the Roux limb from the intestinal pacemaker located in the proximal duodenum. Ectopic, retrograde propagating pacemakers, therefore, develops in the jejunum, distal to the site of transaction, leading to entero-gastric reflux, delayed gastric emptying, malabsorption syndrome and overall deterioration of the quality of life.

In the Uncut technique, stomach is not exposed to the irritating effects of bile and pancreatic secretion, unlike classical loop gastro-jejunostomy, as the content of the afferent limb is diverted into the efferent limb through a Braun entero-enterostomy. Moreover, the flow of bilio-pancreatic juice is blocked off from reaching the stomach by using a single, double-row non-cutting GI stapler. Unlike REY, the lack of division of small bowel, as a part of making the Roux-Y loop, the UREY maintains myoneural continuity of the gut, alleviating the potential of developing RSS. In addition, reinforcement of the staple line by seromuscular stitches prevents staple line dehiscence and its consequent alkaline-bilio-gastric reflux.

#### Limitations:

The weakness of our study is the small group of patients and short study period. The postoperative convalescence is affected by the form of surgery, laparoscopy or laparotomy; a variable which was ignored as both forms of the MUREY procedure were included in the study. Furthermore, patient's convalescence in the early weeks following surgery, is significantly affected by adjuvant chemotherapy, a confounder which was not assessed independently in this study.

#### Conclusion:

The Modified Uncut Roux-en-Y technique is not only is a simple upper GI reconstructive procedure but equally effective in preventing alkaline reflux gastritis and the Roux Stasis Syndrome resulting in reduced convalescence, better nutritional outcome and overall

improvement in the QoL. The technique of placing an additional layer of interrupted sutures over the occluding staple line also seems to have been effective in preventing staple line dehiscence, an important limiting factor of the original technique.

#### References:

1. Noh SM. Improvement of the roux limb function using a new type of "Uncut Roux Limb". *Am J Surg* 2000;180:37-40
2. Van der Mijle HCJ, Kleibeuker JH, et al. Manometric and scintigraphic studies of the relation between motility disturbances in the Roux limb and the Roux-en-Y syndrome. *Am J Surg*. 1993; 166:11-17.
3. Swartz D, Mobley E, Felix M. Bile reflux after Roux-en-Y gastric bypass; an unrecognized cause of post-partum pain. *Surgery for obesity related disease* 2009; 5:27-30.
4. Mathias JR, Fernandez A, Sninsky CA, Clench MH, Davis RH. Nausea, Vomiting and abdominal pain after Roux-en-Y anastomosis: motility of the jejunal
5. Mima T, Ninomiya M, Nishizaki M. Clinical study of Roux stasis syndrome after distal gastrectomy. *Jap J Surg* 2008; 41:1551-1556.
6. Fich A, Matteo N, Camilleri M. Stasis Syndromes following Gastric Surgery: Clinical and Motility Features of 60 Symptomatic Patients. *Journal of Clinical Gastroenterology* 1990.
7. Gustavsson S, Istrup DM, Morrison P, Kelly KA. Roux-en-Y stasis syndrome after gastrectomy. *Am J Surg* 1988;155:490-494.
8. Van Stiegmann G, Goff JS. An alternative to Roux-en-Y for treatment of bile reflux gastritis. *Surg Gynecol Obstet*. 1998; 166:69-70.
9. Miedema BW, Kelly KA. The Roux stasis syndrome: Treatment by pacing and prevention by use of an "uncut" Roux limb. *Arch Surg*. 1992; 127:295-300.
10. Baolien Tu, Sarr MG, Kelly KA. Early clinical results with the uncut Roux reconstruction after gastrectomy: limitations of the stapling technique. *Am J Surg* 1995;170:262-264.
11. Shibata, Chikashi, et al. Results of modified uncut Roux-en-Y reconstruction after distal gastrectomy for gastric cancer. *Hepato-gastrectomy* 2013; 60.127:1797-1799.
12. Velanovich V & Karmy-Jones R. Measuring gastro esophageal reflux diseases: Relationships between the Health-Related Quality of Life Score and physiologic parameters. *American Surgeons*, 1998;64:649-53.
13. Mon RA, Cullen JJ. Standard Roux-en-Y Gastrojejunostomy vs. "Uncut" Roux-en-Y Gastrojejunostomy: A Matched Cohort Study. *GASTROINTEST SURG* 2000; 4:298-303.