

## Caesarean Scar Pregnancy: A Case Series

L CHOWDHURY<sup>a</sup>, ANJANA<sup>b</sup>, I JAHAN<sup>c</sup>

### Summary:

Caesarean section rate is increasing day by day. Incidence of caesarean scar pregnancy (CSP) is also increasing. Prompt and multidisciplinary approach towards diagnosis of the condition is required to reduce associated morbidity. Major haemorrhage and hysterectomy are the main risks associated with CSP. Therefore, adequate counseling and availability of surgical expertise and blood transfusion should be part of a comprehensive management strategy. There are many single reports in literature but only few case series. In this paper, 10 cases of caesarean scar pregnancy treated in Obstetrics and Gynaecology department of CMH Dhaka, CMH Jashore and Hightech Multicare Hospital Private Limited over 10 years are analyzed. Three of 10 patients had mild pain in their lower abdomen and vaginal bleeding. Seven of them had profuse bleeding during D&C for miscarriage as they were not diagnosed at the time of admission. All patients

### Introduction:

Rate of caesarean section is increasing day by day. Along with this surgery its complications are also increasing with emergence of newer ones. Caesarean Scar Pregnancy (CSP) is one of those. It is a rare form of ectopic pregnancy where by the gestational sac is fully or partially implanted within the scar of previous caesarean section (CS). The first case was reported in 1978.<sup>1</sup> Its incidence ranges from 1/1800 to 1/2500 of all pregnancies.<sup>2,3</sup> 6.1% of pregnancies in women with at least one previous CS, a diagnosis of ectopic pregnancy will be CSP.<sup>4</sup> Only 19 cases of CSP were reported in the literature up to 2001 and by 2007, 161 cases had been reported.<sup>5,6</sup> This is attributable partly to the increasing number of CS performed and also to increasing awareness and better ultrasound diagnosis.

- a. Brig Gen Liza Chowdhury, Dept. of Obstetrics and Gynecology, Combined Military Hospital (CMH), Dhaka.
- b. Maj Anjana, Graded Specialist, Dept. of Obstetrics and Gynecology, Combined Military Hospital (CMH), Dhaka.
- c. Maj Ishrat Jahan, Classified Specialist, Dept. of Obstetrics and Gynecology, Combined Military Hospital (CMH), Dhaka.

**Address of Correspondence:** Brig Gen Liza Chowdhury, Dept. of Obstetrics and Gynecology, CMH Dhaka. Mobile: 01769014814, E-mail: dr.lizachy@gmail.com

**Received:** 4 Nov., 2018

**Accepted:** 6 August, 2019

had 1 or 2 caesarean sections. Gestational age of the pregnancy was estimated from 8 to 12 weeks by the last menstrual period. 9 patients were treated surgically. Eight of them had local resection of ectopic pregnancy mass with conservation of the uterus. One patient was treated with D&C followed by intrauterine balloon catheter insertion to control excessive bleeding. There was no total or subtotal hysterectomy. One patient was treated with Inj. Methotrexate. Common symptoms of caesarean scar pregnancy are pain in the lower abdomen and variable degree of vaginal bleeding. The treatment depends on severity of symptoms, gestational age and experience of the obstetrician dealing these cases.

**Keywords:** Caesarean section, Scar ectopic pregnancy, Maternal morbidity.

(J Bangladesh Coll Phys Surg 2019; 37: 191-195)

DOI: <http://dx.doi.org/10.3329/jbcps.v37i4.43349>

This study presents 10 cases of caesarean scar pregnancy treated over 10 years in department of Obstetrics and Gynaecology of CMH Dhaka, CMH Jashore and Hightech Multicare Hospital Private Limited, Dhaka.

### Case Series

This is a retrospective case series of 10 patients with caesarean scar pregnancy who reported to department of Obstetrics and Gynaecology for diagnosis and treatment between 2008 to 2018. The diagnosis was confirmed by both transabdominal, transvaginal ultrasound scan and MRI. Patients underwent both medical and surgical treatment. Clinical data and findings are presented in the Table 1.

Over 10 years, there were 10 patients with confirmed caesarean scar pregnancy in our gynecological departments. The maternal age was from 29 to 36 years. Presenting symptoms were amenorrhoea with per vaginal bleeding or pain abdomen or both. Duration of pregnancy was estimated to be from 8 to 12 weeks by the last menstrual period. Estimated gestational age by USG was from 6 to 10 weeks; no embryos had cardiac activity. Five patients had 1 previous caesarean section and five patients had 2. Almost all patients, except one, had previous abortions in their history.

Table-I

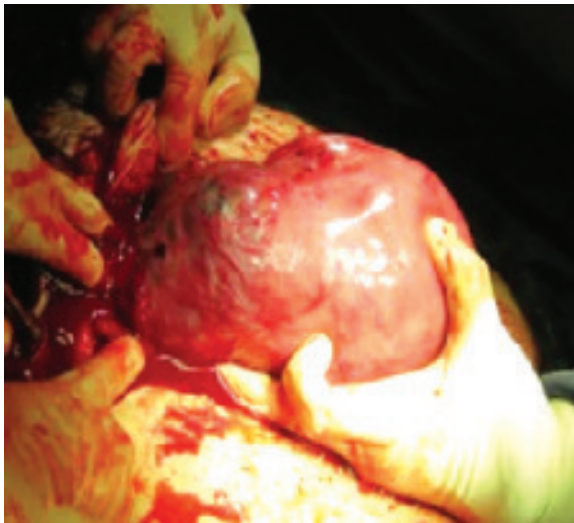*Characteristics of the ten patients with CSP*

| SL. | Maternal Age (Years) | Presenting Symptoms                            | Gestational Age in Weeks (by LMP) | Gestational Age in Weeks (by USG) | No. of Caesarean Section and Indication | Diagnosis on Admission | Treatment  | $\beta$ -hCGmIU/ml Pretreatment | Days in Hospital |
|-----|----------------------|--|-----------------------------------|-----------------------------------|---|------------------------|--|---------------------------------|------------------|
| 1   | 36                   | Vaginal bleeding and mild pain in abdomen      | 8                                 | 7                                 | 1 (CPD)                                 | CSP                    | D & C with intra uterine balloon catheter                              | 7,650                           | 7                |
| 2   | 32                   | Profuse vaginal bleeding during D,E& C         | 8                                 | 6                                 | 2                                       | Incomplete abortion    | Laparotomy followed by excision of scar pregnancy                      | 8,300                           | 8                |
| 3   | 30                   | Profuse vaginal bleeding during D,E&C          | 9                                 | 7                                 | 1 (foetal distress)                     | Missed abortion        | Laparotomy followed by excision of scar pregnancy                      | 20,608                          | 10               |
| 4   | 31                   | Profuse vaginal bleeding during D,E& C         | 11                                | 8                                 | 1 (breech presentation)                 | Incomplete abortion    | Laparotomy followed by excision of scar pregnancy                      | 19,780                          | 9                |
| 5   | 33                   | Profuse vaginal bleeding during D,E& C         | 10                                | 9                                 | 1(placenta praevia)                     | Missed abortion        | Laparotomy followed by excision of scar pregnancy                      | 20,580                          | 9                |
| 6   | 32                   | Profuse vaginal bleeding during D,E& C         | 9                                 | 8                                 | 2                                       | Incomplete abortion    | Laparotomy followed by excision of scar pregnancy                      | 15,756                          | 8                |
| 7   | 33                   | Profuse vaginal bleeding during D,E&C          | 8                                 | 7                                 | 2                                       | Incomplete abortion    | Laparotomy followed by excision of scar pregnancy                      | 9,159                           | 7                |
| 8   | 30                   | Profuse vaginal bleeding during D,E& C         | 12                                | 10                                | 2                                       | Missed abortion        | Laparotomy followed by excision of scar pregnancy with myometrial flap | 20,570                          | 9                |
| 9   | 31                   | Vaginal spotting and mild lower abdominal pain | 10                                | 9                                 | 2                                       | CSP                    | Laparotomy followed by excision of scar pregnancy with myometrial flap | 18,203                          | 10               |
| 10  | 29                   | Vaginal bleeding and pain in lower abdomen     | 8                                 | 6                                 | 1 (Breech presentation)                 | CSP                    | Inj. Methotrexate (50 mg) and Inj. Folinic acid 2 doses                | 16,427                          | 8                |

3 of 10 patients had scanty P/V bleeding at presentation. 7 patients were urgently hospitalized with profuse vaginal bleeding after attempt to curettage with initial diagnosis of either incomplete or missed miscarriages.

In 3 cases the diagnosis - caesarean scar pregnancy was mentioned at the first examination in the emergency room. In 3 cases missed abortion and in 4 cases incomplete abortion were suspected.

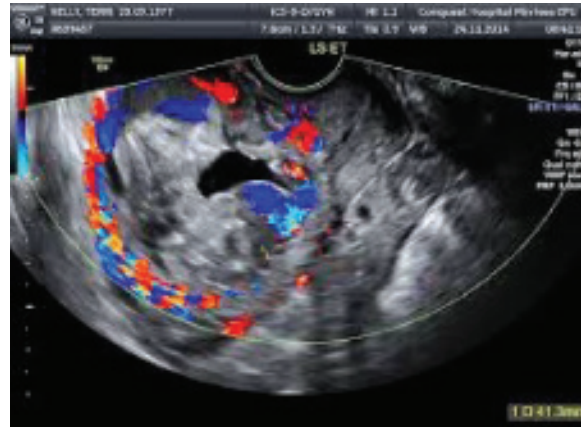
Eight patients were treated by emergency laparotomy. One patient underwent D&C and intrauterine balloon catheter insertion (case-1). This patient had recurrence of CSP in her next pregnancy that was treated by laparotomy. One patient was treated with 2 doses of Inj. Methotrexate (MTX, 50 mg) and Inj. Folinic acid at 7 days apart. In eight cases laparotomy was followed by excision of scar pregnancy (Fig-1) with conservation of uterus. In two patients, myometrial flap (case-8,case-9) was used to cover the gap created by excision.No total or subtotal hysterectomy was required.



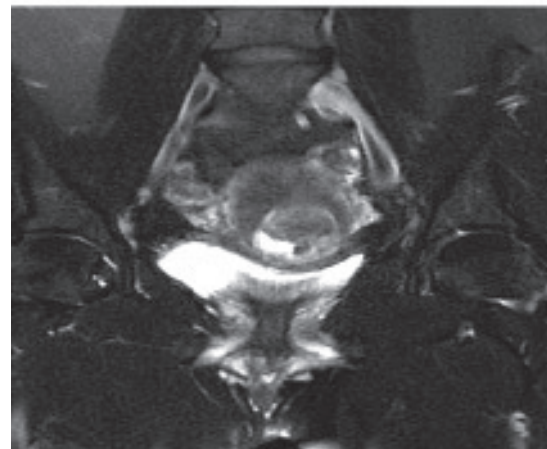
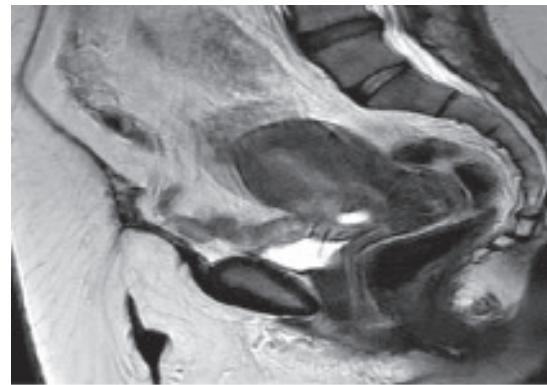
**Fig.-1:** *Peroperative finding of CSP*

On the day of admission, levels of beta-human chorionic gonadotropin ( $\beta$ -hCG) ranged from 7650 to 20608 mIU/ml. Average stay in hospital was 9 days, ranged from 7 to 10 days.

During follow up of the patients they found in good health. Only one patient developed CSP in her next pregnancy.



**Fig.-2:** *Transvaginal image of caesarean scar pregnancy.*



**Fig.-3:** *MRI Image of CSP*

#### **Discussion:**

Little is known about the etiopathology and mechanism of CSP. The most common mechanism is invasion by the implanting blastocyst through a microscopic tract

that develops from the trauma of an earlier caesarean section.<sup>7</sup> CS because of breech presentation in a previous pregnancy appears to be most frequently at risk of future CSP.<sup>8</sup> Risk of recurrence is 3.2% - 5.0% in women with previous CSP.<sup>9,10</sup> In our study one patient had recurrence. Common symptoms are slight vaginal bleeding and/or abdominal discomfort.<sup>11</sup> Rarely acute pain and profuse vaginal bleeding may occur. It is not uncommon to diagnose CSP during or after attempted surgical evacuation for miscarriage which has happened with 7 of 10 presented cases in this series. Hemodynamic instability and collapse in a suspected CSP strongly indicates rupture of caesarean scar with intra-abdominal bleeding.

In our study only three patients presented with slight P/V bleeding and abdominal discomfort. Seven patients presented with profuse P/V bleeding following attempt of D,E&C as they were diagnosed as miscarriage, either missed or incomplete and referred to tertiary centers in haemodynamically unstable condition.

A combined transabdominal and transvaginal ultrasound scan has a high accuracy rate in the diagnosis of CSP<sup>12</sup>. MRI is also a useful adjunct for the diagnosis of CSP.<sup>13</sup>

Ultrasound criteria for diagnosis of CSP are-(1) empty uterine cavity and closed and empty cervical canal;(2) placenta and/or a gestational sac embedded in the scar of a previous CS;(3) a triangular or round or oval shaped gestational sac that fills the niche of the scar;(4) a thin or absent myometrial layer between the gestational sac and the bladder;(5) evidence of functional trophoblastic or placental circulation on color flow on Doppler examination characterized by high velocity and low impedance blood flow;(9) negative sliding organs sign.

In principle pregnancy should be ended as soon as possible. It can be done both by medical and surgical methods. The medical methods are- (1) systemic MTX, (2) local administration of embryocides. Methotrexate is the commonest drug used for local administration as well. Potassium chloride, etoposide and hyperosmolar glucose have also been used for local administration in different studies. In a series of 11 cases treated by MTX injection, 54% women required further doses of systemic MTX with eventual complete resolution of the CSP mass<sup>14</sup>. In our series only one patient has been treated with 2 doses of intramuscular injection of MTX. For

intrasac application of embryocides transvaginal approach is the most suitable one. Combined local and systemic MTX, uterine artery chemoembolization, bilateral uterine artery chemoembolization with gel foams and MTX have also been used as treatment option.

Surgical management options are -(1) cervical dilatation and curettage; (2) abdominal or laparoscopic resection - preferred in cases of exogenous CSP with a thin overlying myometrium; (3) Hysteroscopic management- can be combined with laparoscopic excision for complete removal of the mass, particularly in exogenous CSP; (4) transvaginal resection - offers the advantage of removing the products of conception and scar tissue; (5) combined and sequential management - Uterine artery embolization/chemoembolization followed by D&C or surgical resection in 24 - 48 hours or MTX followed by surgical evacuation or resection after an interval.

Expectant management is used very rarely in selected cases, only endogenous type of CSP progressing towards the uterine cavity in patient who declines termination remaining asymptomatic with non-viable CSP and declining hCG level.

In our series one patient has been treated by D&C and intrauterine balloon catheter and eight patients have been treated with laparotomy with satisfactory outcomes. There is no specific guideline for treatment of CSP. Each particular patient is unique.

#### **Conclusion:**

Diagnosis and management of CSP needs expertise and multidisciplinary approach. Increase CS rate will increase CSP from time to time. CSP can be prevented by reducing the number of primary CS. Prompt and accurate diagnosis of CSP and individualized treatment plan and follow up are required to reduce overall morbidity. The risk of CSP and placenta accreta should be specifically emphasized when counseling woman requesting CS for nonmedical reasons.

#### **References:**

1. Larsen JV, Solomo MH. Pregnancy in uterine scar sacculus - an unusual cause of postabortalhaemorrhage. *S Afr Med J*. 1978; 53: 142-3.
2. Seow KM, Huang LW, Lin YH, Lin MY, Tsai YL, Hwang JL, Caesarean scar pregnancy: issues in management. *Ultrasound ObstetGynecolo* 2004; 23: 247-53.

3. Jurlovic D, hillaby K, Woelfer B, Lawrence A, Salim R, Elson CJ. First trimester diagnosis and management of pregnancies implanted into the lower uterine segment Caesarean section scar. *Ultrasound ObstetGynecol* 2003;21:220-7.
4. Roatas MA, Haberman S, Levigur m. Caesarean scar ectopic pregnancies aetiology, diagnosis, and management. *ObstetGynecol* 2006; 107: 1373-81.
5. Fylstra DL. Ectopic pregnancy within a caesarean scar: a review. *ObstetGynecol Survey* 2002; 57: 537-43.
6. Ash A, Smith A, Maxwell D. Caesarean scar pregnancy. *BJOG* 2007; 114: 253-63.
7. Qian ZD, GuoQY, Huang LL. Identifying risk factors for recurrent caesarean scar pregnancy a case – control study *Fertile Steril* 2014. 102: 129-134.e1
8. Naji O, Daemen A, Smith A, Abdallah Y, Bradburn E, Giggins R, et al. Does the presence of caesarean section scar influence the site of placental implantation and subsequent migration in future pregnancies: a prospective case-control study. *Ultrasound ObstetGynecol*2012; 40:557-61.
9. Ben Nagi J, Ofili-Yedovi D, Sawyer E, Aplin J, Jurkovic D. successful treatment of a recurrent caesarean scar ectopic pregnancy by surgical repair of the uterine defect. *Ultrasound ObstetGynecol* 2006; 28: 855-6
10. Ben Nagi J, Helmy S, Ofili-Yedovi D, Yazbek J, Sawyer E, Jurkovic D, Reproductive outcomes of women with a previous history of Caesarean scar ectopic pregnancies. *Hum Reprod*2007; 22:2012-5.
11. Zhang Y, Gu Y, Wang JM, Li Y. Analysis of cases with caesarean scar pregnancy. *J ObstetGynaecol Res* 2013; 39: 195-202.
12. Ash A, Smith A, Maxwell D. Caesarean scar pregnancy. *BJOG*. 2007; 114:253-63.
13. Aich R, Solanki N, Kakadiya K, Bansal A, Joshi M, Nawale A. Ectopic pregnancy in caesarean section scar: a case report. *Radiology Case Reports*. 2015;10:68-71.
14. Seow KM, Wang PH, Huang LW, Hwang JL. Transvaginal sono-guided aspiration of gestational sac concurrent with a local methotrexate injection for the treatment of unruptured caesarean scar pregnancy. *Arch GynecolObstet* 2013; 288: 361-6.