

# A Case Series of 100 COVID-19 Positive Patients Treated with Combination of Ivermectin and Doxycycline

MTALAM<sup>a</sup>, R MURSHED<sup>b</sup>, E BHIUYAN<sup>c</sup>, S SABER<sup>d</sup>, RF ALAM<sup>e</sup>, RC ROBIN<sup>f</sup>

## Abstract:

**Background:** A definitive treatment of SARS CoV-2 is yet to arrive and the human death toll rises exponentially globally. In this health emergency, it might be useful to look into the old therapies which could be effective against the virus. In vitro research showed Ivermectin could decrease the concentration of coronavirus 4000 to 5000 folds in living lung tissue.

**Aim:** In this prospective study a combination of Ivermectin and Doxycycline will be evaluated therapeutically to treat COVID-19 patients.

**Methods:** 100 COVID-19 patients were enrolled in this study with a predefined inclusion and exclusion criteria. RT-PCR of the SERS-CoV-2 will be done at designated government hospitals. The clinical features and response to treatment were noted according to a dedicated protocol.

## Background:

One hundred years after the Spanish flu pandemic in 1918-20, the whole world is again facing devastation due to the Covid-19 (SARS CoV-2) pandemic. This virulent virus SARS CoV-2 has high infectivity, morbidity and remarkable fatality rate. No specific treatment or vaccine has been invented to save mankind yet. Scientists, physicians and concerned multidisciplinary

- Prof. Mohammed Tarek Alam, Professor and Head of Department of Medicine, Bangladesh Medical College, House # 34, Road # 14/A, R/A, Dhaka-1209, Bangladesh
- Rubaiul Murshed, Chairperson, Shomman Foundation, House # 71/1, Road # 15/A, Dhanmondi R/A, Dhaka-1209, Bangladesh & Chief Consultant, Central Police Hospital, 2 DIT Ave, Dhaka 1000, Bangladesh
- Dr. Elias Bhiuyan, Assistant Professor, Department of Medicine Bangladesh Medical College, House # 34, Road # 14/A, R/A, Dhaka-1209, Bangladesh
- Dr. Sadia Saber, Medical Officer, Department of Medicine Bangladesh Medical College, House # 34, Road # 14/A, R/A, Dhaka-1209, Bangladesh
- Rafa Faaria Alam, Faculty Member, School of Public Health and Life Science, University of South Asia, Dhaka-1212, Bangladesh
- Rishad Choudhury Robin, Associate Project Lead, Shomman Foundation, House # 71/1, Road # 15/A, Dhanmondi R/A, Dhaka-1209, Bangladesh

**Address of Correspondence:** Dr. Mohammed Tarek Alam, Professor and Head of Department of Medicine, Bangladesh Medical College, House # 34, Road # 14/A, R/A, Dhaka-1209, Bangladesh. E-mail: mtarekalam16@gmail.com, Phone: +8801819-185449

**Results:** In this study male and female were 64 and 36 respectively, the age ranged between 8 to 84 years. Retesting was done between 4 and 18 days of starting medication. All patients tested negative and their symptoms improved within 72 hours. There were no noticeable side effects.

**Conclusion:** Combination of Ivermectin and doxycycline was found to be very effective in viral clearance in mild and moderately sick COVID-19 patients. Medical societies and institutions should undertake larger multi center studies to validate and recommend this combination therapy to include in national guidelines.

**Keywords:** Covid-19, Doxycycline, Ivermectin

Bangladesh Coll Phys Surg 2020; 38: 10-15  
DOI: <https://doi.org/10.3329/jbcps.v38i0.47512>

professional including political leaders are united to explore a quick effective treatment and vaccine before it is too late. Empirical applications of some drugs have been assumed to work with success, but without having a clinical trial, they cannot be validated. Until anything comes up, it might be useful to repurpose old therapies which could be effective against the virus.

In the beginning of April 2020, Caly et al. from Monash University, Australia published their research article stating that a single dose of Ivermectin (an anti-parasitic drug) could decrease the concentration of coronavirus in vitro. In the lab, Caly et al. bathed VerohSLAM cells with Ivermectin at a concentration of 5µM from 2 hours post-infection SARS-CoV-2 isolate Australia/VIC01/2020 until the conclusion of the experiment. SARS-CoV-2 RNA was determined by RT-PCR at days 0-3 in both supernatant and cell pellet experiments. The authors noted 93-99.8% reduction in viral RNA for Ivermectin versus DMSO control at 24h in the supernatant (released virions) and cell associated viral RNA (total virus) respectively. They also describe by 48 hours about 5000 fold reduction of viral RNA and maintenance of effect at 72 hours.<sup>1</sup>

They concluded that the human dose needed to be ascertained in further studies. In the current SARS-CoV-2 pandemic, this news was a ray of hope.

**Methodology:**

Study design

Observational /Cross-sectional study

*Study Population*

All RT-PCR SARS- CoV-2 positive patients fulfilling the selection criteria. Mild and moderate cases purposively selected from Bangladesh Medical College.

**Selection criteria****Inclusion Criteria**

- Subjects within age group 5 years and above
- With either sex, male or female
- Confirmed cases of Covid-19 by RT-PCR test
- Patients who are classified as asymptomatic,
- Mild and moderate cases with typical symptoms
- Patients who are not already treated with any other antiviral drugs

## Exclusion criteria

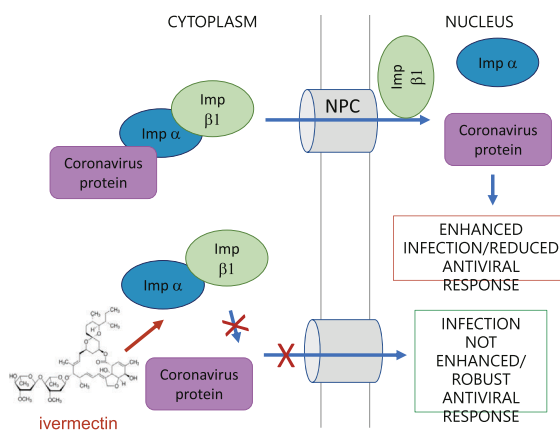
- Patients who are severe and critically ill.
- Patients with chronic liver diseases
- Patients with pregnancy and on lactation
- Children less than 5 years of age or less than 15kg weight.

**Procedure**

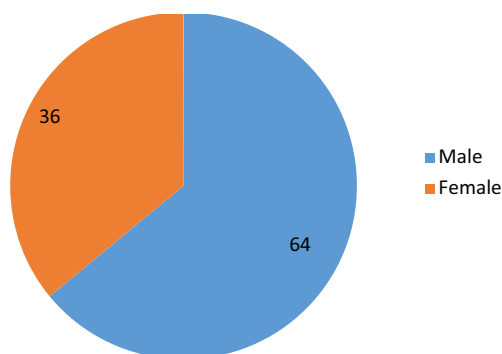
100 patients RT-PCR confirmed cases of SARS CoV-2 met the selection criteria and was enrolled in the study. They were given a combination treatment of Tab Ivermectin and Cap Doxycycline along with supportive treatment. The dose of ivermectin was 0.2 mg/kg single dose. Doxycycline 100 mg daily was given to patients aged 8 years and above for 10 days. Patients were given the choice to go to a COVID 19 designated hospital but they went home and continued treatment. Follow up was done every day for all symptomatic patients over telephone about remission of symptoms. RT-PCR test was repeated with sample of nasal swab for all patients according to availability of testing centers between 4 to 18 days. Six weeks after testing negative, we plan to follow up on the patient about their health conditions.

**Result:**

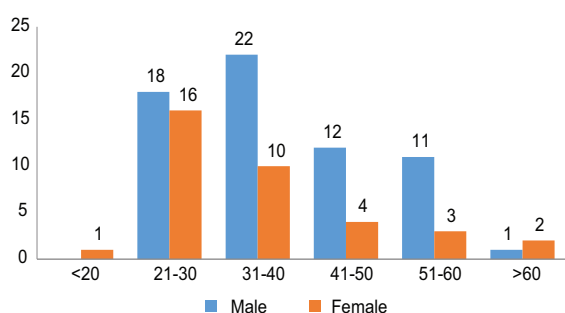
This observational study, consisting of 64 males and 36 females was conducted from April to May 2020 (Figure 2) in Bangladesh Medical College. The oldest patient was 84 years and the youngest one was 8 years with most patients between the ages of 21 to 40 years (Figure 3). Patients were divided in 3 groups: Mild (73), Moderate (20) and Severe (7), based on their symptoms. From the severe patients, three had fever more than 103 Fahrenheit for seven days with severe cough and lung infiltrates , three had severe loose motion and one had uncontrolled diabetes. Out of the rest, 20 patients had moderate symptoms of mild fever (100 Fahrenheit) and mild cough. Moreover, 73 had mild symptoms of malaise, sore throat, loss of smell, loss of taste, and body ache. Fifty percent symptomatic improvement of mild to moderate patients was seen between 3<sup>rd</sup> to 5<sup>th</sup> day after starting treatment. All 7 severe patients' symptoms subsided by 50 percent by 7<sup>th</sup> day of treatment. Retesting was done between 4 to 18 days of starting medication (Figure 4). Twenty five patients underwent retesting between 4<sup>th</sup> to 8<sup>th</sup> days, 51 between 9<sup>th</sup> to 13<sup>th</sup> days and 24 between 14<sup>th</sup> to 18<sup>th</sup> days from starting medication. All of the patients tested negative. None needed intensive care admission and no deaths were reported.



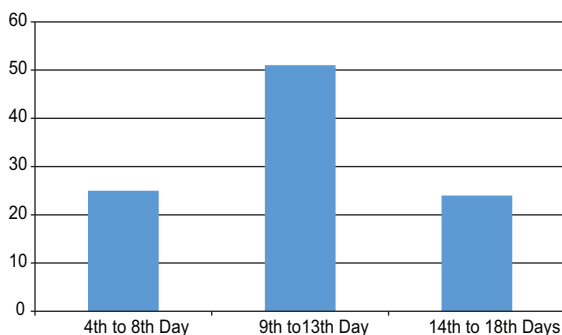
**Fig 1:** Schematic of Ivermectin's proposed antiviral action on coronavirus .



**Fig.-2:** Gender of Covid-19 Positive patients (N=100)



**Fig.- 3:** Male and female ratio in different age groups of Covid-19 positive patients (N=100)



**Fig.-4:** Number of Patients testing Negative on Days after Starting Treatment (N=100)

**Discussion:**

An elderly female colleague with co-morbidities, who tested positive for SARS-CoV2, was referred to the Medicine Out Patient Department. As she was asymptomatic, she was advised isolation but she wanted to be treated without Hydroxychloroquine and Azythromycin fearing cardiac toxicity.

She was informed about the recent findings on Ivermectin and agreed to take an oral combination of 200mcg/kg single dose of Ivermectin along with Doxycycline 100mg orally daily for 10 days. She tested negative in seven days.

This observation correlates with the findings of Caly et al.<sup>1</sup> We had given the standard single dose of Ivermectin that is normally given for the treatment of scabies and head lice although a very high dose was used in vitro. Doxycycline, a trusted antibiotic, anti-malarial, anti-typus, and anti-viral which also decreases cytokine production without any cardiac toxicity has been a good combination in our small observational study<sup>2</sup>. We only treated asymptomatic and mostly mildly symptomatic patients.

Ivermectin was discovered in 1975 and came into medical use in 1981.<sup>3,4</sup> It is on the World Health Organization’s List of Essential Medicines.<sup>5</sup> Ivermectin is a FDA approved drug, it is used for prevention, treatment, and control of river blindness (onchocerciasis) in populations where the disease is common. It is also used for treatment of Strongyloidosis, enterobiasis, Trichuris trichura, Loa Loa, Scabies, human lice, malaria and is also known to have wide-spectrum antiviral activity against number of viruses under in-vitro conditions.<sup>6,7,8,9</sup> SARS-CoV-2 is a single stranded RNA virus which is closely related to SARS coronavirus (SARS-CoV). Recent study on Ivermectin against SARS-CoV-2 under in-vitro conditions revealed that it can inhibit the viral replication. The single treatment of this drug was able to reduce the virus up to 5000-fold in Vero-hSLAM cells bathed with Ivermectin within 48 hours. However, no further reduction was reported with further increase in time period i.e up to 72 hours. Moreover, no toxicity was seen with the drug at any point of time<sup>10</sup>. Mechanism by which Ivermectin responded against the SARS CoV-2 virus is not known and was believed to be working similarly as it acted on other viruses. It was known to inhibit the nuclear import of viral and host proteins. Integrase protein of viruses and the importin IMPα/β1 heterodimer was responsible for IN nuclear import which further increases the infection. As most of the RNA viruses are dependent

upon IMP $\alpha$ / $\beta$ 1 during infection, Ivermectin acts on it and inhibits the import with the increase in antiviral response<sup>1,10</sup>.

Fig 1 shows a schematic of Ivermectin's proposed antiviral action on coronavirus. IMP $\alpha$ / $\beta$ 1 binds to the coronavirus cargo protein in the cytoplasm (top) and translocates it through the nuclear pore complex (NPC) into the nucleus where the complex falls apart and the viral cargo can reduce the host cell's antiviral response, leading to enhanced infection. Ivermectin binds to and destabilizes the IMP $\alpha$ / $\beta$ 1 heterodimer thereby preventing IMP $\alpha$ / $\beta$ 1 from binding to the viral protein (bottom) and preventing it from entering the nucleus. This, likely, results in reduced inhibition of the antiviral responses, leading to a normal, more efficient antiviral response<sup>1</sup>.

Ivermectin is well tolerated by uninfected humans. It is primarily metabolized in the liver by CYP450-3A47 and has a plasma half-life of 16 hours and is almost exclusively excreted in faeces with minimal clearance by the kidneys. Therefore, it does not require dose adjustment for people with renal failure. There have been some reports of a mild anticoagulation effect. However, this is usually not significant enough to alter coagulation parameters such as the prothrombin ratio.

Side effects of oral Ivermectin are rare and usually minor. These include transient tachycardia, flushing, nausea and lightheadedness. More severe neurological side effects are theoretically possible in rare susceptible individuals. Moreover, FDA describes some of the side-effects that may be associated with Ivermectin include skin rash, vomiting, diarrhea, stomach pain, facial or limb swelling, neurologic adverse events (dizziness, seizures, confusion), sudden drop in blood pressure, severe skin rash potentially requiring hospitalization and liver injury (hepatitis)<sup>11</sup>. The safety of Ivermectin in pregnant women has not been studied and such use is not recommended. Studies in animals have shown an increase in birth defects. Safety and effectiveness in children below 5 years and under 15 kg and pregnant women have not been established. Ivermectin passes into breast milk and use during

breast feeding is not recommended<sup>12</sup>. No significant drug interactions with Ivermectin are recognized.

In vitro studies showed Doxycycline to exert anti-inflammatory effects at low (20 - 40mg/day) and high (100 or 200mg/day) doses with inhibitory action on metalloproteases and modulating effects of pro-inflammatory cytokines IL 6, IL 8 and tumor necrosis factor alpha. The anti-inflammatory properties of Doxycycline and other components of tetracycline has been demonstrated for several inflammatory airway diseases, including, acute respiratory distress syndrome. Thereby, low Doxycycline doses have been shown to be more effective than high doses to prevent induction of pro-inflammatory cytokines (such as IL 6) in inflammatory diseases<sup>13</sup>. Doxycycline is rapidly and almost completely absorbed after oral administration and has half life of 16-18 hours. Based on the available evidence, we believe Tetracyclines may be effective agents in the treatment of Covid-19 due to their ability to chelate Zinc compounds on matrix metalloproteinases (MMP) on which coronaviruses rely heavily for survival, cell infiltration, cell to cell adhesion and replication, many of which has Zinc as part of their MMP complex.<sup>14</sup> It is a safe and inexpensive drug with a minimal toxicity<sup>14</sup>. Doxycycline is largely excreted unchanged both in the bile and urine and the dose does not require adjustment in patients with renal failure, because of their enterohepatic circulation this drug may remain in the body for a long time after cessation of therapy. Doxycycline can produce GI irritation most commonly after oral administration. Tolerability can be improved by administering it with food. Doxycycline can be safely used in children aged 8 years and above<sup>15</sup>. Currently global scenario is not stable as there is no effective drugs could be prescribed under sufficient evidence based clinical trials. Already efficacy and effectiveness of Hydroxychloroquine is questionable<sup>16,17,18</sup>. As Doxycycline is safe to use in treatment of ARDS it alone could be a better option for Covid-19 treatment.

**Conclusion:**

It is too early in this pandemic to claim major successes of the effectivity of our combination therapy (Ivermectin and Doxycycline) as our number is small and there is no control group. Nevertheless, the results encourage us to continue the clinical study for people of the world in this improbable crisis as each and every life counts.

We urge the different medical societies and International organizations to take up this unique observation and quickly give it a trial and clearance because these drugs are FDA approved for many years with excellent safety and efficacy reviews. At the very least, using them in the first few days of being positive with or without symptoms may save the admissions of those 20% who suffer and the unnecessary deaths on ventilators. We can also stop the community transmission by asymptomatic carriers by treating the asymptomatic COVID-19 positive patients. Above all it is a very cheap combination, and if fast tracked by a quick trial would cost pennies and save a lot of lives, specifically designed for resource-poor settings.

**References:**

1. Caly L., Druce J.D., Catton M.G., Jans D.A., Wagstaff K.M. The FDA-approved Drug Ivermectin inhibits the replication of SARS-CoV-2 in vitro. *Antivir Res.* 3 April 2020:104787. [PMC free article] [PubMed] [Google Scholar]
2. Holmes NE, Charles PGP. Safety and Efficacy Review of Doxycycline. *Clinical Medicine Therapeutics.* 2009;1:CMT.S2035.
3. Mehlhorn H (2008). *Encyclopedia of parasitology* (3rd ed.). Berlin: Springer. p. 646. ISBN 978-3-540-48994-8.
4. Verduyck J, Rew RS, eds. (2002). *Macrocyclic lactones in antiparasitic therapy.* Oxon, UK: CABI Pub. p. Preface. ISBN 978-0-85199-840-4.
5. World Health Organization (2019). *World Health Organization model list of essential medicines: 21st list 2019.* Geneva: World Health Organization. hdl:10665/325771. WHO/MVP/EMP/IAU/2019.06. License: CC BY-NC-SA 3.0 IGO.
6. Azeem S., Ashraf M., Rasheed M.A., Anjum A.A., Hameed R. Evaluation of cytotoxicity and antiviral activity of ivermectin against Newcastle disease virus. *Pak J Pharm Sci.* 2015;28(2):597–602. [PubMed] [Google Scholar]
7. Mastrangelo E., Pezzullo M., De Burghgraeve T., Kaptein S., Pastorino B., Dallmeier K. Ivermectin is a potent inhibitor of flavivirus replication specifically targeting NS3 helicase activity: new prospects for an old drug. *J Antimicrob Chemother.* 2012;67(8):1884–1894. doi: 10.1093/jac/dks147. [PMC free article] [PubMed] [CrossRef] [Google Scholar]
8. Götz V., Magar L., Dornfeld D., Giese S., Pohlmann A., Höper D. Influenza A viruses escape from MxA restriction at the expense of efficient nuclear vRNP import. *Sci Rep.* 2016;6:23138. doi: 10.1038/srep23138. [PMC free article] [PubMed] [CrossRef] [Google Scholar]
9. Lundberg L., Pinkham C., Baer A., Amaya M., Narayanan A., Wagstaff K.M. Nuclear import and export inhibitors alter capsid protein distribution in mammalian cells and reduce Venezuelan Equine Encephalitis Virus replication. *Antivir Res.* 2013;100(3):662–672. [PubMed] [Google Scholar]
10. R. Choudhary and A.K. Sharma. Potential use of hydroxychloroquine, ivermectin and azithromycin drugs in fighting COVID-19: trends, scope and relevance. *New Microbes New Infect.* 2020 May; 35: 100684. Published online 2020 Apr 22 doi: 10.1016/j.nmni.2020.100684
11. FDA. FAQ: COVID-19 and Ivermectin Intended for Animals 2020 [cited 2020 17 June]. Available from: <https://www.fda.gov/animal-veterinary/product-safety-information/faq-covid-19-and-ivermectin-intended-animals> <https://www.fda.gov/animal-veterinary/product-safety-information/faq-covid-19-and-ivermectin-intended-animals>
12. McCarthy J., Laukas A., Hotez P.J. Chemotherapy of Helminth infections (Chapter 51). *Goodman Gilman's The Pharmacological Basis of Therapeutics*, 12 ed. New York: McGraw-Hill Companies, Inc; 2011. pg- 1456 Goodman and Gilman's The Pharmacological Basis of Therapeutics 12th edition, pg-1456
13. Claudio Conforti, Roberta Giuffrida, Iris Zalaudek, and Nicola Di Meo. Doxycycline, a widely used antibiotic in dermatology with a possible anti-inflammatory action against IL 6 in COVID 19 outbreak. *Dermatol Ther.* 2020 May 15: e13437. doi: 10.1111/dth.13437 [Epub ahead of print]
14. Sodhi, M. and Etminan, M., 2020. Therapeutic Potential for Tetracyclines in the Treatment of COVID 19. *Pharmacotherapy: The Journal of Human Pharmacology and Drug Therapy*, 40(5), pp.487-488.



15. MacDougall C., Chambers H. F. Protein Synthesis Inhibitors and Miscellaneous Antibacterial Agents (Chapter 55). *Goodman Gilman's The Pharmacological Basis of Therapeutics*, 12 ed. New York: McGraw-Hill Companies, Inc; 2011. pg- 1524 Goodman and Gilman's The Pharmacological Basis of Therapeutics 12th edition, pg-1524
16. Mahévas M, Tran V-T, Roumier M, et al. Clinical efficacy of hydroxychloroquine in patients with COVID-19 pneumonia who require oxygen: observational comparative study using routine care data. *BMJ*. 2020;369:m1844.
17. Tang W, Cao Z, Han M, et al. Hydroxychloroquine in patients with mainly mild to moderate Coronavirus Disease 2019: open label, randomised controlled trial. *BMJ*. 2020;369:m1849.
18. Rosenberg ES, Dufort EM, M Udo T, et al. Treatment with hydroxychloroquine or azithromycin and in-hospital mortality in patients with COVID-19. *JAMA*. 2020; Epub ahead of print