

Outcome of Unstable Thoracolumbar Fracture Following Long Segment Posterior Fixation

AAM CHOUDHURY^a, MS ALAM^b, AK AZAD^c, K AKTER^d

Abstract:

Introduction: Fractures of the thoracolumbar region are the most common injuries of the vertebral column and burst fractures are the most frequent. The purpose of this study was to see the radiological and functional outcome after long segment posterior fixation in unstable thoracolumbar spine injury with incomplete neurological deficit.

Methods: A total of 146 cases were included in this prospective case series from January 2014 to December 2018 through non randomized purposive sampling. All the patients were operated with long segment posterior fixation and postero-lateral fusion by Autogenous cancellous bone graft. Postoperative functional outcome was assessed both clinically by ODI, VAS, ASIA and radiologically by

Bridwell criteria. Postoperative follow up was conducted at 2nd, 6th, 12th and finally 6 monthly.

Results: The mean Cobb angle at pre-operative was 21.5 ± 8.9 and at final follow-up was 11 ± 4.57 in this study (p -value < 0.05). At final follow up 1 grade improvement occurred in 116 (79.5%) patients and 2 grade improvement in 36 (20.5%). Regarding ODI and VAS, moderate disability (25%) with mild pain (16%) was found at final follow up with a Bridwell fusion grade II (48%).

Conclusion: Long segment transpedicular screw fixation in unstable thoracolumbar spine injury with incomplete neurological deficit is an effective method of treatment. This method enhances neurological and functional recovery with an acceptable fusion rate

(*J Bangladesh Coll Phys Surg* 2021; 39: 114-122)

DOI: <https://doi.org/10.3329/jbcps.v39i2.52410>

Introduction:

Thoracolumbar fracture is the commonest injury of the axial skeleton and accounts for around 90% of all spinal fractures. Due to the rigid costovertebral joints of the dorsal spine, it acts as a fulcrum of movement in dorsolumbar spine at the time of injury¹.

Thoracolumbar fractures are frequent in men and peak incidence is observed between 20 and 40 years.

65% of thoracolumbar fractures occur due to motor vehicle injuries and fall from height, with remainder contributed by sports injury and violence².

Due to the fulcrum of increased motion at dorsolumbar junction, collapse of the vertebral body with associated kyphotic deformity usually occurs. This vertebral collapse usually invades the spinal canal, which may cause neurological Deficit³.

Unstable fracture defined as failure of any two column injury including middle column which account for 25%-50% of all fractures in this region. They are very common in younger patients and could have a great impact on their daily physical activities⁴.

There are standard classification systems based on fracture pattern, mechanism of injury, neuro-deficit and posterior ligamentous complex (PLC) injury. Xrays are the main investigation while computed tomography (CT) scan delineates the extent on bony injury and magnetic resonance imaging (MRI) scan detects the spinal cord and soft tissue injury⁵.

- Dr. Abdullah Al Mamun Choudhury, Medical Officer, National Institute of Traumatology & Orthopaedic Rehabilitation, (NITOR) Dhaka
- Prof. Dr. Md. Shah Alam, Professor & Head of the Department, Orthopaedics & Spine Surgery, Dhaka Medical College Hospital, Dhaka
- Dr. Abul Kalam Azad Junior Consultant (Ortho), General Hospital Netrokona
- Dr. Kohinoor Akhter, MD Resident (Biochemistry & Molecular Biology), BSMMU

Address of Correspondence: Dr. Abdullah Al Mamun Choudhury, Medical Officer, National Institute of Traumatology & Orthopaedic Rehabilitation, (NITOR) Dhaka, E/3, 5th floor, Kalim Vila, 104/A/16/11, Sahid Buddhijibi Road, Jafraabad, Mohammadpur, Dhaka, Cell: +8801714575282, E-mail: mamuncomc@gmail.com

Received: 25 March, 2019

Accepted: 06 March, 2021

The assessment of neurological function is done by using the American Spinal Injury Association (ASIA) method and graded according to the ASIA Impairment scale. Examination of anal sensation and sphincter autonomic contraction should be performed to identify complete or incomplete neurological deficit as a standard protocol⁶.

The management of unstable thoracolumbar fractures remains challenging. Effective correction of the deformity, neurological recovery, early mobilization and return to work are the fundamentals of the management, and also minimize complication.

Absolute indication of early surgery is progressive neurological deficit⁷. Other indication for surgical intervention are incomplete neurological deficit, >25-30° angle of kyphotic deformity, >50% of loss of vertebral body height, and >40-50% of canal narrowing⁸.

The surgical treatment of unstable fracture and fracture-dislocations of thoracolumbar spine are still in debate. Conservative treatment might be an option, but surgery is the modern way of treatment. The goals of surgery are to restore the stability of the vertebral column and decompression of spinal canal (9). Posterior transpedicular fixation has been the choice for stabilizing acute unstable thoracolumbar fractures among all other methods¹⁰.

Either anterior or posterior or both approaches can be used to stabilize and achieve fusion but the efficacy of either approach is somewhat similar^{11,12}. Due to less extensile and hazardous approach, most of the spine surgeons advocate posterior fusion as the treatment of choice¹³⁻¹⁵.

Long-segment pedicle screw fixation (LSPF) usually involves inserting eight screws: two level above & below the fracture. Short-segment pedicle fixation (SSPF) involves inserting four screws: one level above & below the fracture¹⁶.

SSPF is the most common and simple treatment. It offers the advantage of incorporating fewer motion segments in the fusion^{17,18}, but may lead to implant failure and re-kyphosis (9-54%) and moderate-to-severe (50%) pain^{9,17}. To prevent this and augment the anterior column, placement of body augment¹⁹, polymethylmethacrylate injection³, transpedicular bone grafting²⁰, anterior instrumentation and strut grafting¹² or long-segment posterior fixation (LSPF)²¹ could be done.

The use of transpedicular fixation two levels above and below the fractured vertebra reduce the kyphosis, instrument failure and collapse of the vertebrae²². LSPF has gained popularity in the last decade as it has the aforementioned advantages as well as relieve pain sufficiently²³.

Methods:

146 patients (age range 15-60, mean 31.5±9.58 years) with thoracolumbar fracture (T10–L2) with incomplete neurological deficit from January 2014 to December 2018, studied in NITOR and private settings were included in this study. Inclusions criteria were: a) single-level fracture; b) neurologic function limited to ASIA Grades B, C, or D; c) limited involvement of T10–L2; d) <3 weeks from the time of injury, Exclusion criteria were: a) Complete spinal cord injury (ASIA Grades A) b) Associated cervical spine & head injury; c) Pathological fracture of spine. This was a prospective case series and cases were selected by purposive sampling.

Radiographic outcome was evaluated by measuring Cobb angle, kyphotic deformation and beck index (24). Figure 2 shows measurement of Cobb Angle and kyphotic deformation. Pain status was evaluated by a 100-point VAS scale. The functional outcome was assessed by Oswestry Disability Index (ODI). Neurological recovery was evaluated by ASIA grading. The investigation included X-ray, computed tomography (CT) scanning of the spine and magnetic resonance imaging (MRI).

Informed written consent was taken from all the patients mentioning the details of the procedure as well as modalities of treatment. An expert technologist was responsible for gathering the required information who is unaware of the objectives and surgical procedures of this study.

Long segment posterior fixation (LSPF) was done in every cases and performed by the same surgeon. Patients were placed in a prone position under general anesthesia with modified kneeling with two sand bags under each side of trunk which allowed the abdomen to hang free, minimizing epidural venous dilation and bleeding. Pedicle screw fixation and reduction were performed under C-arm guidance. Laminectomy to decompress spinal cord was carried out at the involved level and bone was saved to be used as bone graft. Screws were 40 or 45 mm long, depending on the level and size of the vertebra. At the 10th and 11th thoracic levels, 5.5 or 6.5-mm diameter multi-axial screws and at the 12th

thoracic level and caudally 6.5 mm diameter multiaxial screws were used. The instrumentation was applied bilaterally. Fracture reduction and indirect spinal canal decompression both could be accomplished by contouring the rod and applying compression-distraction forces before tightening the screws. Long segment posterior fixation was done with autogenous bone grafting from the spinous process and lamina in all patients and applied thoracolumbosacral orthosis (Taylor brace) postoperatively for 3 months. Figure 1 shows Burst # L2 in a 28 years' male, fixed with LSPF.

A fracture severity score was constructed using Thoracolumbar Injury Classification and Severity Score (TLICS). A comprehensive severity score of 3 or less suggests a non-operative injury, while a score of 5 or more suggests that surgical intervention may be considered. Injuries assigned a total score of 4 might be handled conservatively or surgically²⁵.

Correction loss was defined as progressive loss of Cobb angle in the latest follow-up radiographs compared to the initial post-operative radiographs. The fusion status of the patients was determined primarily with use of plain radiographs according to the classification system of Christensen et al. 2001²⁶ by two independent observers and finally by Bridwell fusion grading²⁷. The presence of screw breakage, screw pullout, peri-implant loosening, and rod breakage were considered as criteria for implant failure.

Data were collected concerning the age, sex, localization, type of injury, presence of neurological deficits, pain, work status, complications and radiologic parameters (Cobb angle, kyphotic deformation of vertebral body, vertebral height and posterolateral fusion). Clinical and radiographic follow-up were done immediately after the operation and at 2nd, 6th, 12th, 24th week & then 12 monthly. Statistical analysis was done using SPSS version 25.0 software. The level of statistical significance was set at $P < 0.05$.

Results:

There were 126 men and 20 women with male to female ratio were 6.3:1. Mean age was 31.5 years within the range of 31–45 years. Maximum 64 patients were manual worker. The majority of fractures were due to falls (106 cases). The remaining cases were due to car accidents (40 cases). The fractured vertebra body level was L1, L2, and

T12 in 82, 24, and 40 cases respectively. In this series maximum number of patients (92) operated within 15 to 21 days (63%) and maximum fractures were unstable burst in nature 102 (70%).

All the patients were decompressed posteriorly and long segment stabilization was done in each case by titanium pedicle screws and rods. Post-operative Xray showed good hardware position in all patients. Adequate decompression was achieved in all the cases.

The mean duration of surgery was 150 ± 21 min whereas the mean blood loss was 392.47 ml. The mean length of hospital stay was 28 days and all the patients were mobilized in the 1st or 2nd postoperative day. Radiological parameters are listed in Table-1.

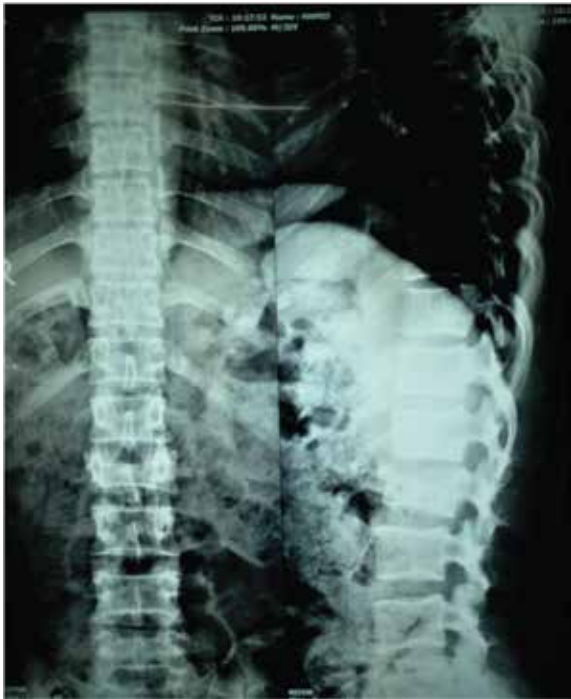A paired sample T-test was conducted to compare the means of radiological parameters which was found statically significant (p -value < 0.05)

The mean Pre and post op VAS is 57.57 ± 9.08 and 16.4 ± 8.9 (mild) respectively, 90% (131) of which end up with mild pain (p -value < 0.05). The mean ODI at final follow up was 25.27 ± 8.49 which was 67.68 ± 13.20 pre operatively with a p -value < 0.05 . Maximum patients (87) 59.6% end up with mild disability at final follow-up.

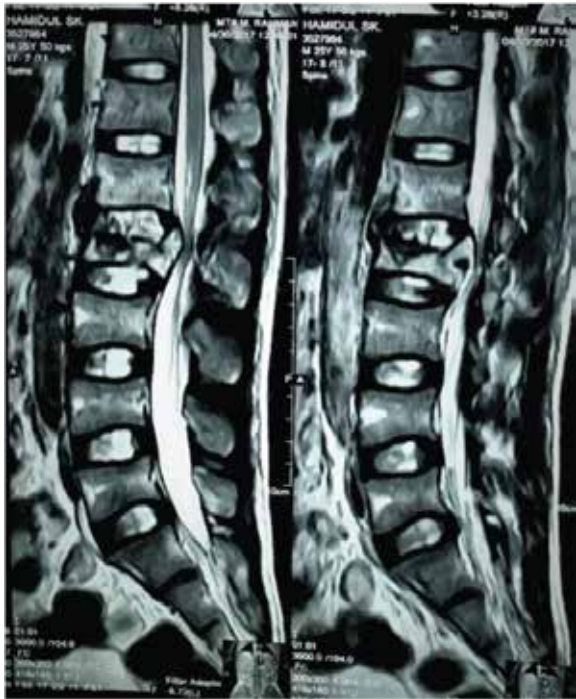In our series, pre-operative ASIA grade B was 30 (20.5%), C was 48 (36.9%) and D was 68 (46.6%). After final follow up 1 grade improvement occurred in 116 (79.5%) patients and 2 grade improvement in 36 (20.5%) patients. A cross-tab analysis was conducted to see the significance of status in Pre-operative and Post-operative ASIA grading with grade improvement. A Pearson chi-square value < 0.05 indicates significant improvement in terms of neurology post-operatively.

48% of cases (70) showed thick fusion mass on one side i.e. bridwell grade II, 60 patients (41%) showed grade I fusion and rest of patients' had doubtful fusion with lucency.

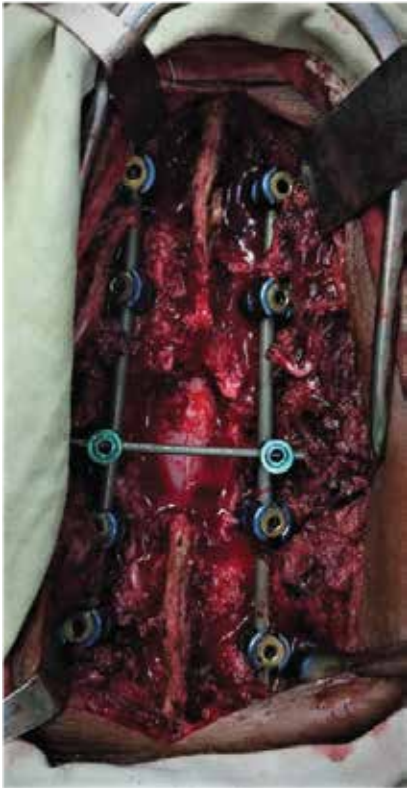A non-parametric Spearman correlation test was conducted among Bridwell fusion grade, Final ODI and ASIA grading. There is a significant positive strong correlation between Bridwell fusion grade and Final ODI exist ($r = 0.694$, p -value < 0.05 , $n = 146$). But final ASIA grading was not correlated with Bridwell fusion grade (p -value = 0.394). Also magnitude of curve correction is not related with Bridwell fusion grade, Final ODI and ASIA grading



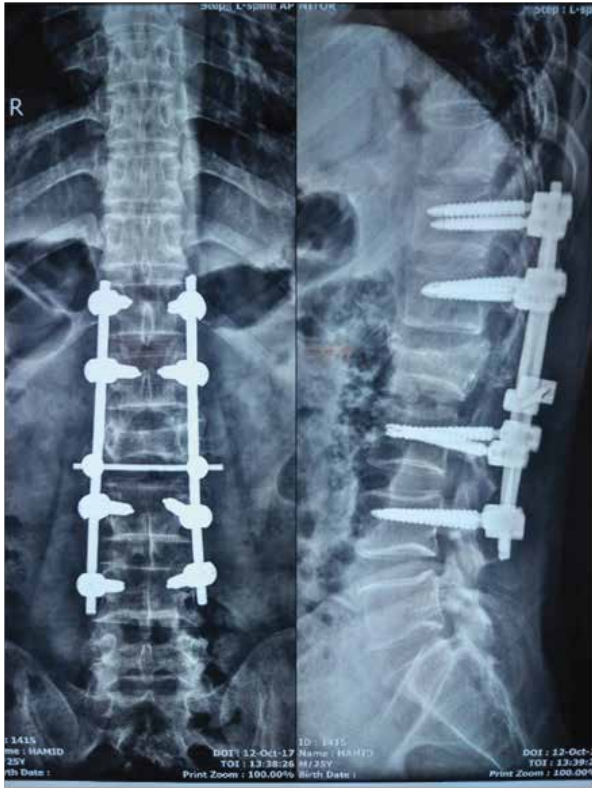
A



B



A



B

Figure-1:

- A. Pre-operative X-ray of LS spine AP & lateral view, T2 weighted sagittal section (MRI of LS spine) showing Burst # L2 in a 28 years' Male
- B. Per-operative image showing Long segment pedicle fixation with crosslink (same patient)
- C. X-ray of LS spine AP & lateral view at final follow-up (same patient)

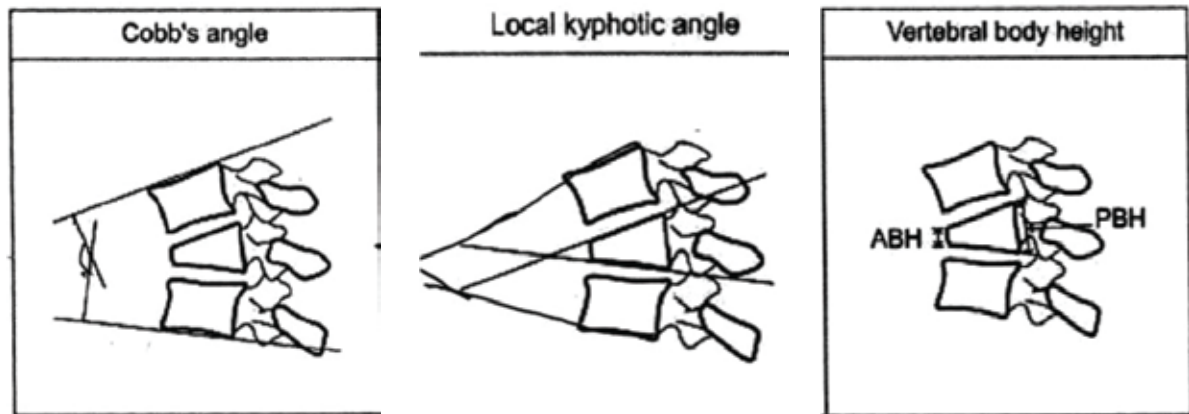


Figure-2: Measurement of Cobb's angle, kyphotic deformation/ local kyphotic angle, and Beck Index.

1. Kyphotic angle (Cobb angle) is the angle formed between a line drawn parallel to the superior endplate of upper vertebrae above fracture and inferior endplate of lower vertebra below the fracture.
2. Segmental kyphosis (kyphotic deformation) was measured as the angle between the inferior and superior endplate of fractured vertebra.
3. The ratio of anterior and posterior vertebral body height termed as Beck index.

ABH: anterior body height, PBH: posterior body height.

with a p-value of 0.150, 0.819 and 0.204 respectively.

During the follow-up hardware failure was detected in 3 cases. There were 9 cases of superficial wound infection and bed sore each which were responded to conservative treatment.

References:

Among all spinal injury thoracolumbar junction is the commonest and comprises > 50% of the cases of all spinal fractures (28).

Holdsworth, F. (1963) first described the burst fracture (29). The existence of the unstable burst fracture, with complete disruption of the posterior elements and increased potential for neural injury was described in Whitesides, 1977(30). It is estimated that approximately 75% of patients with

thoracolumbar injuries sustain some degree of neurological deficit. These types of injuries are best treated by vertebral column decompression and stabilization (31). The management plans differ among many of the researchers regarding operative (32) and non-operative approaches (33,34).

According to literature review the result of our study is almost similar to internationally published studies. It is observed that active age group was mostly affected with a male 126 (86.3%) dominancy. RA raja, (31) showed 86% male patients in his series. In this study, most common level injured was L1 (56.2%) and followed by D12 (27.4%). Altay (16) showed 51.6% involvement of L1 and 29% involvement of D12. Muralidhar (35) observed that 70% were at L1 level and 3 cases at D12 (10%).

Maximum injuries were due to fall from height 106 (72.6%) in this study which was 92% and 59.25% cases observed in some studies (31,36). But other study showed road traffic accident is the common cause of injury (37). Maximum fractures were burst in nature 102 (70%) which were reported 44% and 83.3%(31, 35) in other studies.

In our series, at final follow up 1 grade improvement occurred in 116(79.5%) patients and 2 grade improvement in 36 (20.5%). Butt et al., 2006 showed two grades of improvement in 40% (7/17) of the patients and one grade of improvement in 60%(38).

The mean Cobb angle at pre-operative was 21.5 ± 8.9 and at final follow-up was 11 ± 4.57 in this study. There was no correlation found between the final amount of Cobb angle and the degree of pain reported. Altay reported Cobb angle at preoperative and final follow up was 18.9 and 8.1 (39) which were near about my result. Similar results 11.9 ± 2.67 and 11.4 at final follow up showed by some studies (40,41). But Sapkas, 2010 (15) showed preoperative Cobb angle was 17.5 ± 6.8 which became 6.0 ± 4.0 degree at final follow up.

Gertzbein (2) noted that, more severe the canal compromise and kyphotic deformity, worse the neurological deficit. But Mumford and Cantor (33,34) stated that the relationship between these two is unclear. In this study the mean preoperative kyphotic deformation of vertebral body was around 21.80 and 14.50 at final follow-up. kyphotic deformation was observed 200 pre-operatively and 30 at final follow-up (42). Mean beck index was found 0.68 pre operatively and 0.80 at final follow up in this study. Sapkas (15) showed similar results where preoperative Beck index was 0.60 and 0.92 at final follow up.

According to functional outcome ODI was 67.68% (Crippled) pre operatively which became 25.6% (moderately disabled) at final follow up Aly (43) showed in a meta-analysis that Kim 2009, Canbeck 2014 and Azmiri (44) found similar result which were 30%, 29% and 25% at last follow up respectively (moderately disabled). In this series, Mean Pre op VAS (pain intensity) was 57mm (moderate) and at final follow up it was 17 mm (mild) Pain intensity according to VAS was pre op 40mm post op 4 mm observed by Yang (45).

Fusion rate with pedicular fixation (99%) were significantly higher than those for anterior instrumentation (46) In this series, 48% of cases

showed thick fusion mass on one side i.e. bridwell grade II and 41% shows solid fusion in both sides (grade I).

Regarding the postoperative complication, bed sore and wound infection was found in 9 (6.67%) patients each who were responded to antibiotic later. But Modi (47) reported 1 (3.22%) screw breakage, 2 (6.45%) screw loosening and 1(3.22%) superficial wound infection.

It was observed that, fusion rate was highest in minimally disabled group. There is a significant positive strong correlation between Bridwell fusion grade and Final ODI exist ($r = 0.694$, p -value < 0.05 , $n = 146$). But final ASIA grading was not correlated with Bridwell fusion grade (p -value = 0.394). Also magnitude of curve correction is not related with Bridwell fusion grade, Final ODI and ASIA grading with a p -value of 0.150, 0.819 and 0.204 respectively.

Conclusion

In countries like Bangladesh fractures of the thoracolumbar spine are increasing in frequency. As seen from the result of this study, Long segment transpedicular screw fixation in unstable thoracolumbar spine injury with incomplete neurological deficit is an effective method of treatment. This method markedly reduce the hospital stay and enhances neurological and functional recovery with an acceptable fusion rate.

Funding: No funding sources

Conflict of interest: None declared

References:

1. Avanzi O, Landim E, Meves R, Caffaro MF, de Albuquerque Araujo Luyten F, Faria AA. Thoracolumbar Burst Fracture: Load Sharing Classification and Posterior Instrumentation Failure. Rev Bras Ortop (English Ed [Internet]. 2010;45(3):236-40. Available from: [http://dx.doi.org/10.1016/S2255-4971\(15\)30363-3](http://dx.doi.org/10.1016/S2255-4971(15)30363-3) [https://doi.org/10.1016/S2255-4971\(15\)30363-3](https://doi.org/10.1016/S2255-4971(15)30363-3)
2. Gertzbein S.D., Court-brown, CM., Marks, P., Fazl, M., Schwartz, M., Jacobs RR. The Neurological Outcome following Surgery for Spinal Fractures. Spine (Phila Pa 1976) [Internet]. 1988;6(13):641-4. Available from: https://journals.lww.com/spinejournal/Abstract/1988/06000/The_Neurological_Outcome_following_Surgery_for.7.aspx <https://doi.org/10.1097/00007632-198806000-00007>, PMID:3175754

3. Ge CM, Wang YR, Jiang SD, Jiang LS. Thoracolumbar burst fractures with a neurological deficit treated with posterior decompression and interlaminar fusion. *Eur Spine J*. 2011;20(12):2195-201. <https://doi.org/10.1007/s00586-011-1875-6>, PMID:21688000 PMCid:PMC3229728
4. Tian NF, Wu Y Sen, Zhang XL, Wu XL, Chi YL, Mao FM. Fusion versus Nonfusion for Surgically Treated Thoracolumbar Burst Fractures: A Meta-Analysis. *PLoS One*. 2013;8(5):1-6. <https://doi.org/10.1371/journal.pone.0063995>, PMID:23704968 PMCid:PMC3660321
5. Rajasekaran S, Kanna RM, Shetty AP. Management of thoracolumbar spine trauma An overview. *Indian J Orthop*. 2015;49(1):72-82. <https://doi.org/10.4103/0019-5413.143914>, PMID:25593358 PMCid:PMC4292328
6. Zhang ZC, Li F, Sun TS. An expert consensus on the evaluation and treatment of acute thoracolumbar spine and spinal cord injury in China. *Neural Regen Res*. 2013;8(33):3077-86.
7. Bohlman HH. Treatment of fractures and dislocations of the thoracic and lumbar spine. *J Bone Jt Surg Am* [Internet]. 1985;67(1):165-9. Available from: http://www.ncbi.nlm.nih.gov/entrez/query.fcgi?cmd=Retrieve&db=PubMed&dopt=Citation&list_uids=381446, <https://doi.org/10.2106/00004623-198567010-00024>
8. Hur J-W. A Comparative Analysis of the Efficacy of Short-Segment Pedicle Screw Fixation with that of Long-Segment Pedicle Screw Fixation for Unstable Thoracolumbar Spinal Burst Fractures. *Clin Med Res*. 2015;4(1):1. <https://doi.org/10.11648/j.cmr.20150401.11>
9. Alvine GF, Swain JM, Asher MA, Burton DC. Treatment of thoracolumbar burst fractures with variable screw placement or Isola instrumentation and arthrodesis: Case series and literature review. *J Spinal Disord Tech*. 2004;17(4):251-64. <https://doi.org/10.1097/01.bsd.0000095827.98982.88> PMID:15280752
10. Liu L, Gan Y, Zhou Q, Wang H, Dai F, Luo F, et al. Improved monosegment pedicle instrumentation for treatment of thoracolumbar incomplete burst fractures. *Biomed Res Int*. 2015;2015. <https://doi.org/10.1155/2015/357206>, PMID:26097844 PMCid:PMC4434173
11. Danisa OA, Shaffrey CI, Jane JA, Whitehill R, Wang GJ, Szabo TA, et al. Surgical approaches for the correction of unstable thoracolumbar burst fractures: A retrospective analysis of treatment outcomes. *J Neurosurg*. 1995;83(6):977-83. <https://doi.org/10.3171/jns.1995.83.6.0977>, PMID:7490641
12. Kaneda K, Taneichi H, Abumi K, Hashimoto T, Satoh S, Fujiya M. Anterior decompression and stabilization with the Kaneda device for thoracolumbar burst fractures associated with neurological deficits. *J Bone Jt Surg - Ser A*. 1997;79(1):69-83. <https://doi.org/10.2106/00004623-199701000-00008> PMID:9010188
13. Roy-Camille R, Saillant G, Mazel C. Internal fixation of the lumbar spine with pedicle screw plating. *Clin Orthop Relat Res*. 1986;NO. 203(September):7-17. <https://doi.org/10.1097/00003086-198602000-00003>
14. Carl, Allen L., MD*; Tromanhauser, Scott G., MD†; Roger, Douglas J. M. Pedicle Screw Instrumentation for Thoracolumbar Burst Fractures and Fracture-Dislocations. *Spine (Phila Pa 1976)* [Internet]. 17(suppliment 8s):317-24. Available from: https://journals.lww.com/spinejournal/Abstract/1992/08001/Pedicle_Screw_Instrumentation_for_Thoracolumbar.18.aspx, <https://doi.org/10.1097/00007632-199208001-00018>, PMID:1523519
15. Sapkas G, Kateros K, Papadakis SA, Brilakis E, Macheras G, Katonis P. Treatment of Unstable Thoracolumbar Burst Fractures by Indirect Reduction and Posterior Stabilization: Short-Segment Versus Long-Segment Stabilization. *Open Orthop J*. 2010;4(1):7-13. <https://doi.org/10.2174/1874325001004010007>, PMID:20177428 PMCid:PMC2822149
16. Altay M, Ozkurt B, Aktekin CN, Ozturk AM, Dogan Ö, Tabak AY. Treatment of unstable thoracolumbar junction burst fractures with short- or long-segment posterior fixation in magerl type a fractures. *Eur Spine J*. 2007;16(8):1145-55. <https://doi.org/10.1007/s00586-007-0310-5>, PMID:17252216 PMCid:PMC2200786
17. Alanay A, Acaroglu E, Yazici M, Oznur A, Surat A. Short-Segment Pedicle Instrumentation of Thoracolumbar Burst Fractures. *Spine (Phila Pa 1976)*. 2001;26(2):213-7. <https://doi.org/10.1097/00007632-200101150-00017>, PMID:11154543
18. Knop C, Bastian L, Lange U, Oeser M, Zdichavsky M, Blauth M. Complications in surgical treatment of thoracolumbar injuries. *Eur Spine J*. 2002;11(3):214-26. <https://doi.org/10.1007/s00586-001-0382-6>, PMID:12107790 PMCid:PMC3610522
19. Chen HH, Wang WK, Li KC, Chen TH. Biomechanical effects of the body augmenter for reconstruction of the vertebral body. *Spine (Phila Pa*

- 1976). 2004;29(18):382-7. <https://doi.org/10.1097/01.brs.0000139308.65813.70>, PMID:15371717
20. Daniaux H1, Seykora P, Genelin A, Lang T KA. Application of posterior plating and modifications in thoracolumbar spine injuries. Indication, techniques, and results. *Spine (Phila Pa 1976)*. 1991;16(supp. 3):s:125-133. <https://doi.org/10.1097/00007632-199103001-00018>, PMID:2028327
 21. Akbarnia, B A; Crandall, D G; Burkus, K; Matthews T. Use of long rods and a short arthrodesis for burst fractures of the thoracolumbar spine. A long-term follow-up study. *JBJS [Internet]*. 1994;76(11):1629-35. Available from: https://journals.lww.com/jbjsjournal/Abstract/1994/11000/Use_of_long_rods_and_a_short_arthrodesis_for_burst.5.aspx <https://doi.org/10.2106/00004623-199411000-00005> PMID:7962022
 22. Aligizakis A, Katonis P, Stergiopoulos K, Galanakis I, Karabekios S, Hadjipavlou A. Functional outcome of burst fractures of the thoracolumbar spine managed non-operatively, with early ambulation, evaluated using the load sharing classification. *Acta Orthop Belg*. 2002;68(3):279-87.
 23. McLain RF. The biomechanics of long versus short fixation for thoracolumbar spine fractures. *Spine (Phila Pa 1976)*. 2006;31(11 SUPPL.):70-9. <https://doi.org/10.1097/01.brs.0000218221.47230.dd> PMID:16685240
 24. Kang S-K, Lee CW, Park NK, Kang T-W, Lim J-W, Cha KY, et al. Predictive Risk Factors for Refracture after Percutaneous Vertebroplasty. *Ann Rehabil Med*. 2011;35(6):844. <https://doi.org/10.5535/arm.2011.35.6.844>, PMID:22506213 PMID:PMCid:PMC3309392
 25. Vaccaro AR, Lehman RA, Hurlbert RJ, Anderson PA, Harris M, Hedlund R, et al. A New Classification of Thoracolumbar Injuries. *Spine (Phila Pa 1976)*. 2005;30(20):2325-33. <https://doi.org/10.1097/01.brs.0000182986.43345.cb> PMID:16227897
 26. Christensen FB, Laursen M, Gelineck J, Eiskjær SP, Thomsen K, Bünger CE. Interobserver and Intraobserver Agreement of Radiograph Interpretation With and Without Pedicle Screw Implants. *Spine (Phila Pa 1976)*. 2001;26(5):538-43. <https://doi.org/10.1097/00007632-200103010-00018>, PMID:11242382
 27. Bridwell, Keith H., MD*; Lenke, Lawrence G., MD*; McEnery, Kevin W., MD†; Baldus, Christy, LPN*; Blanke, Kathy R. Anterior Fresh Frozen Structural Allografts in the Thoracic and Lumbar Spine: Do They Work If Combined With Posterior Fusion and Instrumentation in Adult Patients With Kyphosis or Anterior Column Defects? Available from: https://journals.lww.com/spinejournal/Abstract/1995/06020/Anterior_Fresh_Frozen_Structural_Allografts_in_the.14.aspx, <https://doi.org/10.1097/00007632-199506020-00014>, PMID:7676341
 28. Dai LY, Jiang LS, Jiang SD. Posterior short-segment fixation with or without fusion for thoracolumbar burst fractures: A five to seven-year prospective randomized study. *J Bone Jt Surg - Ser A*. 2009;91(5):1033-41. <https://doi.org/10.2106/JBJS.H.00510>, PMID:19411450
 29. Denis F. Spinal instability as defined by the three-column spine concept in acute spinal trauma. *Clin Orthop Relat Res*. 1984;NO. 189:65-76. <https://doi.org/10.1097/00003086-198410000-00008>
 30. Jr TW. Traumatic kyphosis of the thoracolumbar spine. [Internet]. *Clinical orthopaedics and related research*. 1977. Available from: <http://ukpmc.ac.uk/abstract/MED/340100>
 31. Raja RA. Management of thoracolumbar spine injuries at a tertiary care hospital. *J Ayub Med Coll Abbottabad*. 2010;22(1):171-5.
 32. McCullen G, Vaccaro AR, Garfin SR. Thoracic and lumbar trauma: Rationale for selecting the appropriate fusion technique. *Orthop Clin North Am*. 1998;29(4):813-28. [https://doi.org/10.1016/S0030-5898\(05\)70050-X](https://doi.org/10.1016/S0030-5898(05)70050-X)
 33. Cantor, Jeffrey B., MD; Lebowhl, Nathan H., MD; Garvey, Timothy, MD; Eismont, Frank J. M. Nonoperative Management of Stable Thoracolumbar Burst Fractures With Early Ambulation and Bracing. *Spine (Phila Pa 1976) [Internet]*. 1993;18(8):971-6. Available from: https://journals.lww.com/spinejournal/Abstract/1993/06150/Nonoperative_Management_of_Stable_Thoracolumbar.4.aspx <https://doi.org/10.1097/00007632-199306150-00004> PMID:8367784
 34. Mumford, Joe, MD; Weinstein, James N., DO; Spratt, Kevin F., PhD; Goel, Vijay K. P. Thoracolumbar Burst Fractures: The Clinical Efficacy and Outcome of Nonoperative Management. *Spine (Phila Pa 1976)*. 1993;18(8):955-70. <https://doi.org/10.1097/00007632-199306150-00003>
 35. Muralidhar BM, Hegde D, Hussain PSB. Management of unstable thoracolumbar spinal fractures by pedicle screws and rods fixation. *J Clin Diagnostic Res*. 2014;

36. Lee GW, Jang SJ, Kim J Do, Son JH, Jang JH. The efficacy of percutaneous long-segmental posterior fixation of unstable thoracolumbar fracture with partial neurologic deficit. *Asian Spine J.* 2013;7(2):81-90. <https://doi.org/10.4184/asj.2013.7.2.81> PMID:23741544 PMCID:PMC3669707
37. Payer M. Implantation of a distractible titanium cage after cervical corpectomy: Technical experience in 20 consecutive cases. *Acta Neurochir (Wien).* 2006;148(11):1173-80. <https://doi.org/10.1007/s00701-006-0871-9> PMID:16927030
38. Butt MF, Farooq M, Mir B, Dhar AS, Hussain A, Mumtaz M. Management of unstable thoracolumbar spinal injuries by posterior short segment spinal fixation. *Int Orthop.* 2007;31(2):259-64. <https://doi.org/10.1007/s00264-006-0161-4> PMID:16783550 PMCID:PMC2267576
39. Altay M, Ozkurt B, Aktekin CN, Ozturk AM, Dogan Ö, Tabak AY. Treatment of unstable thoracolumbar junction burst fractures with short- or long-segment posterior fixation in magerl type a fractures. *Eur Spine J.* 2007 Aug;16(8):1145-55. <https://doi.org/10.1007/s00586-007-0310-5>, PMID:17252216 PMCID:PMC2200786
40. Moon MS, Choi WT, Moon YW, Kim YS, Moon JL. Stabilisation of fractured thoracic and lumbar spine with Cotrel-Dubousset instrument. *J Orthop Surg.* 2003;11(1):59-66. <https://doi.org/10.1177/230949900301100113>, PMID:12810974
41. Cho DY, Lee WY, Sheu PC, Sonntag VKH, Hitchon PW, Cooper PR, et al. Treatment of Thoracolumbar Burst Fractures with Polymethyl Methacrylate Vertebroplasty and Short-segment Pedicle Screw Fixation. *Neurosurgery.* 2003; <https://doi.org/10.1227/01.NEU.0000093200.74828.2F>, PMID:14633301
42. Jun DS, Yu CH, Ahn BG. Posterior direct decompression and fusion of the lower thoracic and lumbar fractures with neurological deficit. *Asian Spine J.* 2011;5(3):146-54. <https://doi.org/10.4184/asj.2011.5.3.146>, PMID:21892386 PMCID:PMC3159062
43. Aly TA. Short segment versus long segment pedicle screws fixation in management of thoracolumbar burst fractures: Meta-analysis. *Asian Spine J.* 2017;11(1):150-60. <https://doi.org/10.4184/asj.2017.11.1.150>, PMID:28243383 PMCID:PMC5326724
44. Azimi P, Shahzadi S, Mohammadi HR, Azhari S. Surgical outcomes and correlation ODI and ASIA scores in patients with thoracolumbar and lumbar burst fractures. *Int Clin Neurosci J.* 2015;2(1):12-5.
45. Yang WE, Ng ZX, Miang K, Koh R. Percutaneous pedicle screw fixation for thoracolumbar burst fracture: a Singapore experience. *singapur Med J.* 2012;53(9):3-7.
46. Boos N, Webb JK. Pedicle screw fixation in spinal disorders: A European view. *Eur Spine J.* 1997;6(1):2-18. <https://doi.org/10.1007/BF01676569> <https://doi.org/10.1007/BF00307823> PMCID:PMC3454634
47. Modi HN, Chung KJ, Seo IW, Yoon HS, Hwang JH, Kim HK, et al. Two levels above and one level below pedicle screw fixation for the treatment of unstable thoracolumbar fracture with partial or intact neurology. *J Orthop Surg Res.* 2009;4(1):1-6. <https://doi.org/10.1186/1749-799X-4-28> PMID:19635134 PMCID:PMC2724433