

Wilson's Disease in a Young Girl with Abnormal Behavior

R AMIN^a, R HASAN^b, A SAHA^b, AR HOSSAIN^c, MA KAHHAR^d

Abstract:

Wilson's disease is an inborn error of copper metabolism caused by a mutation to the copper-transporting gene ATP7B. Epidemiologic clustering of mutations to the ATP7B gene based on ethnicity has been observed. Diagnosis of the condition is made primarily on the basis of clinical findings, presence of the Kayser-Fleischer ring, and biochemical and radiological parameters. The young patient's usual presentation is through liver involvement. Uncommonly the young group can present with

neuropsychiatric manifestation. Behavior disorder like bizarre activity, personality change, affective or schizophrenic presentation may be the initial presentation of Wilson's disease. Choreoathetoid movement although not common can also be presented in such patient. A young girl with abnormal behavior with atypical presentation was recently observed in one of the medicine unit of Dhaka Medical College.

(J Bangladesh Coll Phys Surg 2011; 29: 170-173)

Introduction:

Wilson's disease (WD) is an inborn error of copper metabolism caused by a mutation to the copper-transporting gene *ATP7B*. The disease has an autosomal recessive mode of inheritance, and is characterized by excessive copper deposition, predominantly in the liver and brain¹. The majority of patients with WD present with either predominantly hepatic or neuro psychiatric symptoms, and with either clinically asymptomatic or symptomatic liver involvement². About half the patients with Wilson's disease have neurological or psychiatric problems. Most patients initially have mild cognitive deterioration and clumsiness, as well as changes in behavior. Specific neurological symptoms then follow, often in the form of parkinsonism (increased rigidity and slowing of routine movements) with or without a typical hand tremor, ataxia (lack of coordination) or dystonia (twisting and repetitive movements of part of the body) and or choreoathetoid movement^{1,2}. Psychiatric problems due to Wilson's disease may

include behavioral changes, depression, anxiety and psychosis^{1,2}. Psychiatric features include emotional lability, impulsiveness, disinhibition, and self-injurious behavior. Kayser-Fleischer rings are observed in up to 90% of individuals with symptomatic Wilson disease and are almost invariably present in those with neurologic manifestations^{1,3}. Kayser-Fleischer rings are a useful diagnostic sign and they are considered pathognomonic of Wilson's disease when accompanied by neuropsychiatric manifestations³. Here is a case report of a young girl with abnormal behavior who had multiple psychiatrist consultation before and ultimately confirmed as a case of Wilson's disease.

Case Report:

Miss. S. 13 year-old class VI student from Jinjira, Dhaka presented with complaints of progressive behavioral disorder for 8 months characterized by undue smile, recurrent transient mutism, self neglect, somnambulism and occasional cry. There was no prior psychiatric illness. Although she was euphoric and easy going child with normal upbringing and routine school activity, her academic success was not up to the mark. An episode of fever with complete recovery was observed at the initiation of her illness. There is consanguinity in her parents but no first-degree family members are having any physical or psychiatric illness. Her premorbid personality was normal except she was found introverted but elated and maintained disciplined life.

- a. Dr. Robed Amin, Assistant Professor, Department of Medicine, Dhaka Medical College, Dhaka-1000
- b. Dr. Rabiul Hasan, Dr. Amit Saha, Honorary Medical Officer, Department of Medicine, Dhaka Medical College, Dhaka-1000
- c. Dr. Ahmed Riyad Hossain, Assistant Registrar, Department of Medicine, Dhaka Medical College, Dhaka-1000
- d. Dr. M A Kahhar, Professor, Department of Medicine, Dhaka Medical College, Dhaka-1000

Address of Correspondence : Dr. Robed Amin, Assistant Professor, Department of Medicine, Dhaka Medical College, Dhaka-1000

Received: 16 January 2010

Accepted: 29 December 2010

Her home life, relations with peer, leisure activity were quite normal. On query there was no sexual abuse, conflict, illicit drug history or criminal act. Since the abnormal behavior started, she is reluctant to take food and start losing weight. There was no history of anorexia, abdominal pain, nausea, vomiting, diarrhoea during food withdrawal period. There was no dysphagia or regurgitation of food material. Her sleep pattern was normal except occasional somnambulism when she tried to get up from sleep and walk around home. She took advice from general practitioner and psychiatrists repeatedly for following 3 to 4 months and was treated with multiple antipsychotics and antidepressant drugs without any significant benefit. As there was no improvement, parents took her to a specialist private hospital where she was diagnosed as mental retardation and anticonvulsant was added with antipsychotics. Her status remains unchanged.

For the last 5 months she experienced intermittent purposeless, repetitive movements of limbs (more on left upper limb) and repeated scalp scratching

which fluctuates from time to time. There is no history of head or neck trauma, headache, convulsion, unconsciousness, jaundice, bony or joint pain or ENT ailments. There is also no history of alimentary, cardiovascular or respiratory symptoms during any period of her illness. On examination she is undernourished (BMI-14.78) with stable vital sign. She is well groomed, euphoric with undue smile. Occasional mutism with complete spontaneous recovery was observed. There was no abnormality like thought disorder, preoccupation, perception, cognitive difficulty. Although concentration was lacking, she is well oriented with a remarkable memory. Her mini mental state score was 9.

She had a clumsy gait with choreoathetoid form of abnormal movement and repeated scalp scratching. There was no dystonia, akathisia, tremor, rigidity or bradykinesia. There is Kayser–Fleischer (K-F) rings present in both eyes (Fig.-1). The naked eye finding was confirmed with slit lamp examination. Rest of neurological examination was unremarkable. Fundoscopic examination revealed no cataract and with high power, K-F ring was observed. All other systemic examination was normal.

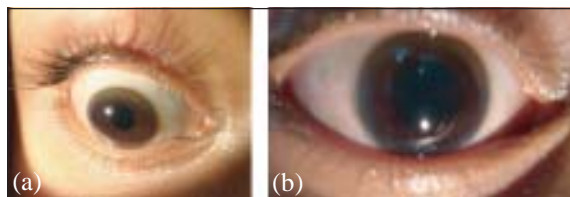


Fig-1 : a) The Kayser–Fleischer ring around the cornea b) This is a characteristic finding observed in most periphery of the cornea caused by deposition cases of neuropsychological Wilson's disease of copper in Descemet's membrane.

Investigations of the patient revealed Hb 10.3 gm/dl, ESR in first hour 8mm total count of WBC 3100/cmm, Poly 43%, Lympho 53%, Monocyte 03% Eosino 01%, Basophil 00%, Platelet count 1,20,000/cmm. Peripheral Blood film showed Leucopenia and thrombocytopenia. S.Creatinine 1.10 mg/dl.

Urine routine examination was Normal, Blood sugar (2 hrs ABF) was 7.06 mmol/L, SGPT- 27u/l, S albumin-36 gm/l, S Globulin-34gm/l, A:G ratio 1.05:1, Prothombin time was 18.8 sec(INR-1.53). Chest X ray revealed no abnormality, Upper GIT endoscopy was normal. USG of whole abdomen revealed Liver is normal in size with coarse hepatic parenchymal echotexture consisted with sonographic features of early change of chronic parenchymal liver disease. Serum ceruloplasmin was 0.02 g/L (normal range-0.2-0.6 g/L). Analysis of copper in urine- 197±1 pgm/24 hours (normal range<100 pgm/24 hours). MRI of brain shows in T2W and FLAIR images of hyperintense areas in pons, both basal ganglia regions and splenium of corpus callosum. There is distinct “the face of the miniature panda” and occasionally “the face of the panda” sign suggestive of Wilson's disease (Fig.-2). MRI of liver to estimate the copper content could not be done due to lack of facility. The diagnosis was confirmed as Wilson's disease’.

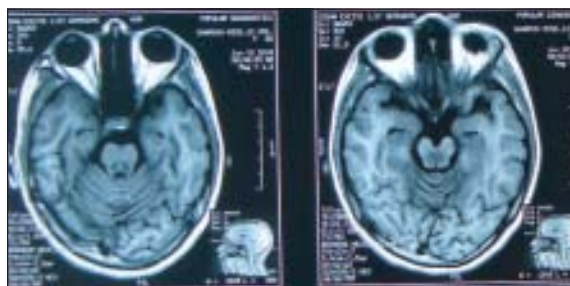


Fig-2 : MRI showing the distinct “the face of the miniature panda”

Case summary:

Characteristics and unusual features in this patient of Wilson's disease is her initial presentation of bizarre behavior and which let her to be consulted by half a dozen psychiatrist. The disease was not suspected as the common psychiatric manifestation of psychosis, depression or personality changes were not prominent rather somnambulism, mutism, undue smile and self neglect. These features are uncommon in Wilson's disease.

The common neurological manifestation of Wilson's disease like dystonia, parkinsonism, sclerotic type or cerebellar type was also not seen in this patient. Her choreoathetosis pattern of neurological sign are also an uncommon presentation and thus the suspicion was not sought for 8 months before she was seen comprehensively in medicine unit of DMCH. The patient was treated with Penicillamine (250 mg slowly escalating to maximum dose of 1000 to 1500 mg) and zinc acetate (75 mg/day) with pyridoxine and vitamin E. She was initially followed up on every two weeks for two months with partial recovery of her neuropsychiatric manifestations and plan to follow up to see the complete response. Her family screening was done and no presymptomatic patient was observed in the family.

Discussion:

The mean age of onset of 'neuropsychological WD' is in the second to third decade, although it has been reported as late as 72 years of age⁴. The majority of patients become symptomatic before the age of 50⁵. In the Indian subcontinent, the disorder tends to manifest one decade earlier, which is possibly related to the traditional practice of cooking and eating food using copper utensils⁶. The statement is characteristically seen in this young girl as she is only 13 yrs of age derived from lower middle class family and home environment of similar practice of cooking. The reported percentage of patients with psychiatric symptoms as the presenting clinical feature is 10-20%⁷. The range of psychiatric abnormalities associated with Wilson disease has been divided into 4 basic categories as behavioral, affective, schizophrenic like and cognitive.

About one-third of patients experience psychiatric disturbances⁸. These disturbances can manifest as changes in school-related or work-related performance, attention deficit hyper activity disorder, impulsivity, paranoid psychosis, obsessive behavior, depression,

suicidal tendencies or bizarre behavior, and can occur early or late in the disease course^{7,8}. In this case report the patient have transient mutism, undue smile, somnambulism, occasional cry and self neglect indicating the bizarre form of behavior as early presentation. In neurological presentation there may be variable of presentation in Wilson's disease. Patients commonly present with extrapyramidal, cerebellar and cerebral-related symptoms,^{5,9} in either a subacute or a chronic fashion. An acute presentation is seen in rare cases. The most common initial presentation is bulbar symptoms characterized by difficulties with speech and swallowing, and drooling⁹.

These symptoms are related to dystonia of the bulbar muscles, or pseudobulbar palsy. Abnormal posturing caused by limb dystonia interferes with writing and walking, and features of parkinsonism commonly occur in combination. A few patients present with cerebellar features such as unsteadiness of gait, and in coordination of speech and limbs¹⁰. Rarely, patients exhibit chorea or choreoathetoid movement (10% cases) of generalized or localized distribution over one half of the body¹¹. In this case report we observed choreoathetoid movement indicating a rare form of presentation.

The most important sign in Wilson's Disease is the KF ring (Fig.-1), which is best visualized with the use of a slit lamp. The presence of the KF ring reflects copper deposition in the brain. Wilson's Disease is also associated with sunflower cataract brown or green pigmentation of the anterior and posterior lens capsule. In our patient the K-F ring was obvious in naked eye; Slit lamp confirmed bilateral symmetrical K-F rings which is diagnostic in neuropsychiatric presentation of Wilson's Disease. There was no cataract. Levels of ceruloplasmin are abnormally low (<0.2 gram/liter) in 80-95% of cases². The Wilson's disease can be diagnosed confirmly in a patient with K-F ring when the ceruloplasmin level is <0.2 gram/liter when the patient present with neuropsychiatric manifestation^{1,2,7}. The diagnostic criteria fulfilled in this case report Urine copper are elevated in Wilson's disease and levels above 100 µg/24h (1.6 µmol/24h) confirm the diagnosis^{2,7}. The urinary copper in this case report was 197±1 pgm/L spot collection.

Most patients who present with neuropsychiatric manifestations have cirrhosis of liver which may or may not be clinically evident. Biochemical and radiological

evidence may be obvious in such cases. In our patient the prothombin time was 18 sec with INR 1.53 and ultasonography of hepatobilliary system revealed features of cirrhosis. Imaging plays an important role in both the diagnosis of Wilson's Disease and the monitoring of patients during therapy. MRI of brain is more sensitive and it shows hyperintensity in lentiform nuclei, pons, midbrain and occasionally in cerebral cortex. Some WD-related changes exhibit characteristic features on MRI, for instance 'face of the giant panda', which is seen in T2-weighted images of the midbrain¹², and 'face of the miniature panda' (Fig 2), which can be seen in the tegmentum region of the pons in the same sequence. In our patient MRI of brain revealed features of face of giant panda. MRI copper content estimation of liver could not be done due to lack of facility. Family screening was done and no presymptomatic patient was observed in the family. A possible new mutation related Wilson's diseases was thus observed in this case report.

Consent process: Written informed consent from the legal guardian was done for imprinting her case report including pictorials.

References:

1. Shyamal K Das, Kunal Ray: Wilson's disease, an update; *Nature Clinical Practice Neurology*, Sep 2006, 2 ; 9:482-493
2. Ala A, Walker AP, Ashkan K, Dooley JS, Schilsky ML (2007). "Wilson's disease". *Lancet* 369 (9559): 397–408.
3. Merle U, Schaefer M, Ferenci P, Stremmel W (2007). Clinical presentation, diagnosis, and long term outcome of Wilson's disease: a cohort study. *Gut* 56 (1): 115–20
4. Ala A et al. (2005) Wilson's disease in septuagenarian siblings: raising the bar for diagnosis. *Hepatology*, 41 : 668–670
5. Le Witt P and Pfeiffe R (2002) Neurologic aspects of Wilson's disease: clinical manifestations and treatment considerations. In *Parkinson's Disease and Movement Disorders*, edn 4, 240–255 (Eds Jankovic JJ and Tolosa E) Philadelphia: Lippincott Williams & Wilkins
6. V Kalra et al. (2000) Wilson's disease: early onset and lessons from a pediatric cohort in India. *Indian Pediatr*, 37: 595–601
7. Roberts EA, Schilsky ML (2003). "A practice guideline on Wilson's disease" (PDF). *Hepatology*, 37 (6): 1475–92.
8. Brewer GJ (2006) Wilson's disease. In *Neurogenetics—scientific and clinical advances*, 383–402 (Ed Lynch DR) New York: Taylor & Francis.
9. S. Starosta-Rubinstein et al. (1987) Clinical assessment of 31 patients with Wilson's disease: correlations with structural changes on magnetic resonance imaging. *Arch Neurol*, 44: 365–370
10. SK Jha et al. (1998) Wilson's disease: clinical and radiological features. *J Assoc Physicians India*. 46:602–605
11. N Kwamura et al. (2004) Serial diffusion weighted MRI in a case of Wilson's disease with acute onset of hemichorea. *J Neurol*, 251: 1413–1414
12. Kuruvilla A and Joseph S (2000) 'Face of the giant Panda' sign in Wilson's disease: revisited. *Neurol India*, 48: 395–396