

# Pseudohypoparathyroidism: A Case Report of a Rare Disease with Uncommon Presentation Producing Diagnostic Dilemma

MZ UDDIN<sup>a</sup>, MAR HOWLADER<sup>b</sup>, MR AMIN<sup>b</sup>, MG MORSHED<sup>c</sup>

### Summary

*Pseudohypoparathyroidism (PHP) is a rare hereditary disorder having the prevalence of 3.4 per million. It is characterized by symptoms and signs of hypoparathyroidism, typically in association with distinctive skeletal and developmental defects. The features of hypoparathyroidism are due to tissue resistance to the effect of parathyroid hormone (PTH). We will describe a 32-year-old woman who had recurrent convulsion for 16 years, infertility, cataract, psychosis, candidiasis and typical features of Albright's hereditary osteodystrophy (AHO), which include a round face, short neck, short stature and brachydactyly. Laboratory investigations showed hypocalcemia, hyperphosphatemia with high PTH level. Computed tomography scan of head revealed wide spread*

*calcification in basal ganglia and cerebral hemispheres. X ray of left foot showed short left 4<sup>th</sup> metatarsal bone. The patient was diagnosed as a case of PHP on the basis of somatic features of AHO with typical biochemical abnormalities and uncontrolled convulsion with combined antiepileptic drugs for 16 years. The unusual features in our case are long delay in clinical diagnosis and absence of family history. She was treated with calcium salt and vitamin D. With this treatment patient's condition was improved and she experiences no attack of convulsion and carpal spasm. Anticonvulsants were withdrawn gradually. We recommend that hypocalcaemia should be excluded before commencing anticonvulsant therapy in all epileptic patients and those patients whose seizures are refractory to anticonvulsant drugs.*

*(J Bangladesh Coll Phys Surg 2011; 29: 227-230)*

### Introduction:

Pseudohypoparathyroidism (PHP) is a hereditary disorder characterized by symptoms and signs of hypoparathyroidism, typically in association with distinctive skeletal and developmental defects. The features of hypoparathyroidism are due to resistance to the tissue response to parathyroid hormone (PTH)<sup>1</sup>. In 1942, Albright and his co-workers first described this condition resembling hypoparathyroidism, hypocalcaemia and hyperphosphataemia, are found together with various somatic abnormalities<sup>2</sup>. The

disorder is usually considered to be inherited as a sex-linked dominant trait and the diagnosis is made in the typical patient at the age of 5-10 years<sup>3</sup>. This is a rare disorder having the prevalence of 3.4 per million<sup>4</sup>. Hypocalcaemic convulsions may be the major practical problem for the patient. In this case report we describe a 32-year-old woman who has recurrent convulsion, tetanic spasm of hands, infertility, cataract, psychosis, candidiasis and typical features of Albright's hereditary osteodystrophy (AHO), which include a round face, short neck, short stature and brachydactyly.

### Case Report:

A 32-year-old woman got admitted to Dhaka Medical College Hospital in October 2009 with the complaints of repeated attack of generalized tonic clonic seizure for 16 years, occasional cramping pain and tingling sensation of both hands and feet for 10 years, gradual dimness of vision for 5 years and occasional carpal spasm of both hands for 3 weeks.

Her convulsion started at the age of sixteen years which was generalized tonic clonic type associated with tongue bite and involuntary voiding but not preceded by

a. Dr. Mohammad Zahir Uddin, Associate Professor, Department of Medicine, Dhaka Medical college.

b. Dr. Md. Anisur Rahman Howlader, Dr. Md. Robed Amin, Assistant Professor, Department of Medicine, Dhaka Medical college.

c. Dr. Md. Goalm Morshed, Assistant Registrar, Department of Medicine, Dhaka Medical college Hospital

**Address of correspondence:** Dr. Mohammad Zahir Uddin, Associate Professor, Department of Medicine, Dhaka Medical College.

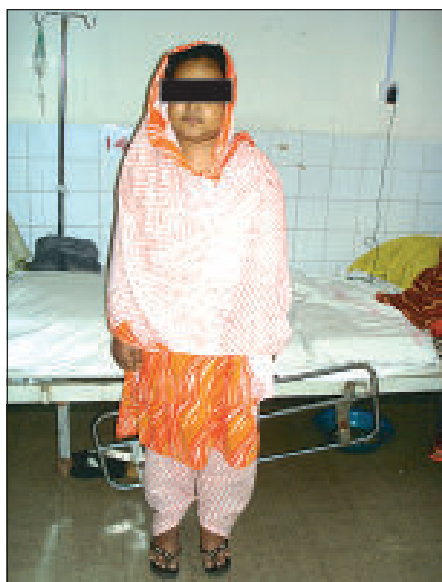**Received:** 31 January 2010

**Accepted:** 20 September 2011

headache, aura or visual disturbance. She consulted many physicians for several times and diagnosed as a case of epilepsy and treated initially with carbamazepine. As there was no improvement, phenobarbitone was added. Despite combination therapy and increment of the dosages of the anticonvulsant drugs her condition was not improved rather deteriorated.

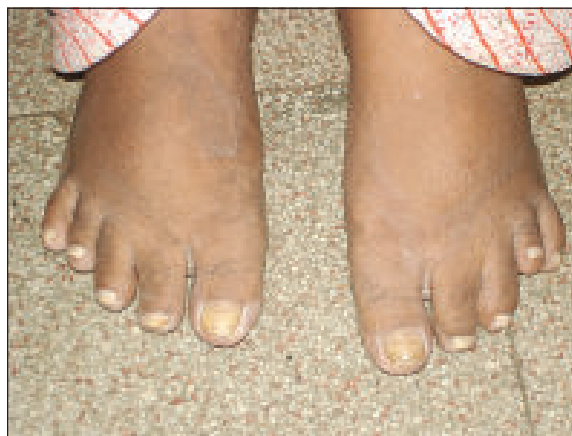At the age of 26 years, she developed occasional cramping pain and tingling sensation of both hands and feet. Considering patient's new symptoms, she was diagnosed as a case of carpal tunnel syndrome in 2002 and was treated surgically but there was no improvement. For the last 5 years she had complained of gradual dimness of vision and diagnosed as a case of bilateral cataract. Later surgical correction with intraocular lens implantation of left eye was done on 2006 with the plan of surgery for the other eye. One year back she developed frank psychosis for a brief period of time and treated accordingly. She developed carpal spasm with the aggravation of her previous symptoms like convulsion, cramping pain & tingling sensation of both hands & feet following vomiting and diarrhea for last 3 weeks. She was oligomenauric and infertile though she is married for 12 years.

On examination she was of short stature, being only 4' 6" and was depressed. She had rounded face, short neck (Fig-1), onychomycosis, and oral candidiasis. There was excessive pigmentation around pressure areas.



**Fig.-1:** the patient showing short stature, short neck & rounded face.

Chvostek's and Trousseau's signs were positive. She had papilloedema in the left eye and cataract in the right eye. The hands and feet were stubby and her left 4th toe was found short (Fig- 2).



**Fig.-2:** Showing short left 4<sup>th</sup> toe, onychomycosis, hyper pigmented & hyperkeratotic lesion over the dorsum of the foot.

Laboratory studies (Table-I) revealed hypocalcemia (1.4 mmol/l) and hyperphosphatemia (2.3 mmol/l) with normal serum albumin (42 g/l) and magnesium (0.78mmol/l) level. The parathyroid hormone (PTH) level was 7.3 pmol/l which was higher than normal. The thyroid function was normal. Her ultrasound of lower abdomen detected no abnormality. Semen analysis of her husband was normal.

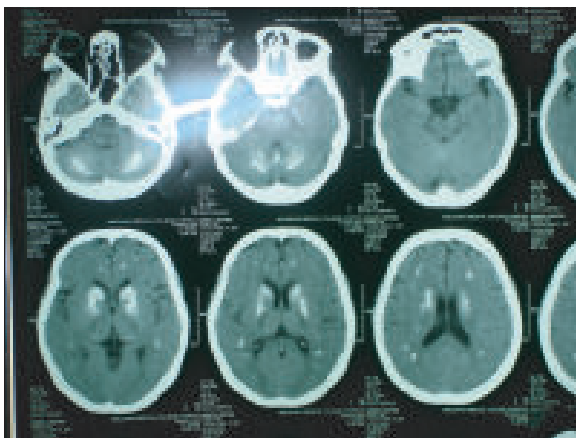
X-ray of the left foot (Fig-3) showed short 4th metatarsal. CT scan of head (Fig-4) showed widespread calcification in basal ganglia and cerebral hemispheres. An electroencephalogram (EEG) revealed presence of sharp and slow waves suggestive of seizure disorder.

**Table-I**

<i>Bio-chemical parameters</i>		
Bio-chemical parameters	Patient's level	Reference value <sup>5</sup>
S. calcium	1.4 mmol/l	2.12-2.62 mmol/l
S. inorganic phosphate	2.3 mmol/l	0.8-1.4 mmol/l
S. magnesium	0.78 mmol/l	0.75-1.0mmol
S. albumin	42 g/l	35-50 g/l
S.PTH	7.3 pmol/l	1.0-6.5 pmol/l
TSH	2.4 mU/L	0.15-3.5 mU/L



**Fig.- 3:** X-ray left foot showing short 4th metatarsal



**Fig.-4:** CT scan of head showing widespread calcification in basal ganglia & cerebral hemispheres.

Her clinical features, biochemical parameters and imaging study were consistent with the diagnosis of pseudohypoparathyroidism. She was put on calcium salts and vitamin D tablets. The anticonvulsants were gradually withdrawn and after correction of hypocalcemia, the convulsions ceases and for the last six months she had no such attack.

#### **Discussion:**

Pseudohypoparathyroidism (PHP) is a rare hereditary disorder characterized by symptoms and signs of hypoparathyroidism, typically in association with distinctive skeletal and developmental defects. In our case the combination of the various somatic, biochemical and radiological abnormalities suggested the diagnosis of pseudohypoparathyroidism, despite the apparent absence of family history<sup>6</sup>. The finding of a

raised plasma parathormone level in the presence of hypocalcaemia indicated active parathyroid glandular activity as is found in Pseudohypoparathyroidism.

Pseudopseudohypoparathyroidism differs from pseudohypoparathyroidism in patient with similar clinical features in whom serum calcium and PTH concentrations are normal. In fact they are considered as two forms of the same syndrome to which the name of Albright's Hereditary Osteodystrophy is applied<sup>7</sup>.

True or idiopathic hypoparathyroidism seems unlikely because of the patient habitus and calcification of the basal ganglia which is not a features of idiopathic hypoparathyroidism<sup>8</sup>.

Mechanism of development of calcification is unknown. Cerebral calcification would be caused by the concurrence of a systemic factor, a disturbance in calcium/ phosphate metabolism, and local factors such as previous inflammatory processes or anoxia or a vascular component<sup>9</sup>. Albright thought that it could be due to plasma super saturation with phosphorus<sup>10</sup>.

Certainly it is noteworthy that the patient was not diagnosed until the age of 32 years. Although the condition is rare, a young patient with cataract associated with recurrent epileptic fit should lead the clinician to suspect the possibility of a hypocalcaemic state<sup>3</sup>.

This patient was on anticonvulsant therapy for many years without any improvement. Paradoxically, her seizures increased gradually even after combination of anticonvulsant drugs. It virtually excluded epilepsy as there is no improvement of seizures even after combination anticonvulsant therapy. Recently it has been demonstrated that long-term anticonvulsant therapy, particularly when more than one drug is used, can precipitate hypocalcaemia<sup>11</sup>.

Almost all patients with hypoparathyroidism or pseudohypoparathyroidism can be effectively treated with calcium and vitamin D analogue and patients with PHP require lower doses than patients with true hypoparathyroidism. In this case report once correction of her hypocalcaemia was achieved with calcium salt and vitamin D therapy, she had no further convulsions and her anticonvulsant therapy was withdrawn gradually.

#### **Conclusion:**

The elevated serum concentration of PTH in a patient with chronic hypocalcemia, hyperphosphatemia, and

normal renal function exclude hypoparathyroidism and suggestive of pseudohypoparathyroidism. Often a definitive diagnosis requires examination of radiographs of the hands and feet. The careful history and physical examination made possible the diagnosis of this rare and unusual case. From this case report we recommend that hypocalcaemia should be excluded before commencing anticonvulsant therapy in an epileptic patient and those patients whose seizures are becoming more frequent despite an increase in anticonvulsant drugs.

### References

1. Fauci AS, Kasper DL, Longo DL, Braunwald E, Hauser SL, Jameson JL, Loscalzo J: Harrison's Principles of Internal Medicine, 17th ed, McGraw Hill 2008; 2357-2367.
2. Pseudohypoparathyroidism: report of a case with late manifestations. *J Clin Endo* 1949; 9(9): 862-873.
3. Glynne A, Iain P, John A: Pseudohypoparathyroidism with paradoxical increase in hypocalcaemic seizures due to long-term anticonvulsant therapy. *Post Med J* 1972; 48: 632-636.
4. Nakamura Y, Matsumoto T, Tamakoshi A, Kawamura T, Senio Y, Kasuga M, Yanagawa H, Ohno Y: Prevalence of idiopathic hypoparathyroidism and Pseudohypoparathyroidism in Japan. *J epidemiol* 2000; 10: 29-33
5. Colledge NR, Walker BR, Ralston SH: Biochemical values. Davidson's principles & practice of medicine, 20<sup>th</sup> ed, Churchill livingstone 2010; 1319-1320.
6. Albright F, Burnett CH., Smith PH: Pseudohypoparathyroidism and example of 'Seabright-Bantam syndrome'. *J Endocrinol* 1942; 30: 922-932.
7. Mann JB, Alterman S, Hill A G: Albright's hereditary osteodystrophy comprising Pseudohypoparathyroidism and pseudopseudohypoparathyroidism. *Ann Int Med* 1962; 56, 315-342.
8. Hastings J R: Lenticulodentate calcification. *J Radiology* 1970; 97: 571-576.
9. Manabe Y, Araki M, Takeda K, Yokota S: Pseudohypoparathyroidism with Striopallidodentate Calcification- A Case Report and Review of the Literature-*Jpn J Med* 1989; 28, 3.
10. Albuja P, Hunter R, Dynan A: The brain in pseudo hypothyroidism. *Rev neuro-psiquia* 2003; 66: 129-133.
11. Chen PL, Chen HL, and Wu DA: Pseudohypoparathyroidism. A Case Report. *J Endo Metabol* 1991; 94: 534-538.