

CASE REPORTS

Laparoscopic Management of Unruptured Interstitial Ectopic Pregnancy

S NAHAR

Summary:

A 27 years old women para -1 had a complaint of dull ache pain in right iliac fossa for 5 days with irregular spotting. Her previous menstrual cycle was normal but in last one month she had an irregular spotting. On examination she was normotensive. Hb% was 65%. there was no tenderness during per abdominal examination but tenderness during per vaginal examination on right side. Transvaginal ultrasonography (TUVS) detected a degenerative sub serous fibroid of 3.5 x 3 cm on the right

Introduction:

Ectopic pregnancy is a common life threatening condition affecting 1 in 100 pregnancy¹. Most ectopic pregnancy develops in the Fallopian tubes. Some times other site like ovary, rudimentary cornu and secondary abdominal pregnancy may happen. Ectopic pregnancy was first described in 11th century. Until 18th century, its out come was fatal and the leading cause of first trimester maternal mortality. The classic clinical triad of the ectopic pregnancy is pain, amenorrhea and vaginal bleeding. Unfortunately only 50% of patient presents typically. Forty to 50% of patients of ectopic pregnancy present with vaginal bleeding, 50% have a palpable mass at the adnexal region and 75% may have abdominal tenderness. Approximately 20% of the presenting patients will have unstable hemodynamic condition and is highly suggestive of ruptured ectopic pregnancy². Fortunately use of modern diagnostic tools are helping to diagnose an unruptured ectopic sac. In this article A case of unruptured interstitial ectopic pregnancy is presented with successful laparoscopic management.

Case report:

A 27 years old women, para one was consulted Victory Nursing & Infertility Management Center for the complaints of right sided lower abdominal dull ache for 5 days with irregular spotting for one month

Address of Correspondence: Dr. Shamsun Nahar, MS,FCPS, Associate Professor,(O & G), Khulna Medical College, Khulna, Bangladesh.

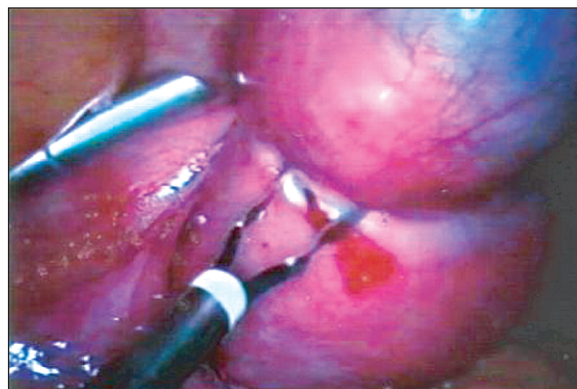
Received: 11 August, 2005

Accepted: 29 May, 2008

fundoanterior side, both adnexae were normal, no fluid was present in cul-de-sac. Her pregnancy test was positive but signs and symptoms of pregnancy were absent. Operative plan was intervention by laparoscope. An unruptured interstitial ectopic pregnancy was found at the anterolateral wall of the fundus. Laparoscopic excision was done and the uterine wall sutured with 2/0 polypropylin. Post operative outcome was good.

(J Bangladesh Coll Phys Surg 2008; 26: 147-148)

from her last menstrual period. General examination showed normal findings. Per-abdominal examination showed no tenderness in any area. Bimanual examination showed tenderness on right adnexal area. Ultrasonography suggests an ill defined degenerative mass attached to the right anterolateral surface of the uterus. Transvaginal ultrasonography confirms the degenerative mass was a fibroid measuring 3.5 x 3 cm at the mentioned site without any collection at the Cul-de-sac. Though the signs and symptoms of pregnancy were absent but pregnancy test was positive. Our finger was pointing to unruptured ectopic pregnancy and the patient prepared for laparoscopic evaluation. Under general anesthesia patients was placed in 15 degree trendelenberg position. The Veress needle was introduced just below the umbilicus. Pneumoperitonium was made by insuffating carbon dioxide at a maximum of 15 mmHg. An operating 10 mm



Unruptured Interstitial Ectopic Pregnancy

laparoscopic trocar inserted through the veress point. Two additional 5 mm trocars inserted one at the level of anterior superior iliac spine just lateral to the epigastric vessels on each side. A bulging reddish black mass detected at the right anterosuperior surface of the uterus. Both the Fallopian tubes and ovaries were healthy. No bleeding was found at the Cul-de-sac. The sac was confirmed as interstitial ectopic pregnancy at the uterine surface. Bipolar diathermy coagulation was done around the sac to reduce the vascularity followed by cutting the sac and removal of the old blood. Additional bleeding points were checked. Denuded surface of the uterus repaired with 2/0 polypropylin. Proper toileting of the peritoneal cavity and closure of the trocar points were done.

Discussion:

Clinical triad of presentation for ectopic pregnancy mostly points to confirmatory investigation with B-hCG and ultrasonography.

The diagnosis of ectopic pregnancy is easy and well established by use of ultrasonography and B-hCG³. Validity of current algorithm for diagnosis of ectopic pregnancy i.e. ultrasonography and B-hCG had decreased the incidence of ruptured ectopic and morbidity and mortality. Atypical presentation makes the diagnosis difficult. Our patient had atypical presentation. Use of transvaginal ultrasonography assures the tranabdominal views. In this case the ultrasonographic findings were not consistent a pregnancy sac. But B-hCG was positive for pregnancy confirmation. Some factors may reduce the sensitivity of ultrasonography. Obesity of the patients, uterine myoma, inconclusive ultrasound findings and definitely the experience of the operator add to the list⁴. laparoscopic surgery or key whole surgery is the gold standard for diagnosis and also treatment for hemodynamically stable cases. The modern treatment is dependent upon the expert surgical skills, good ultrasonic scanning and laboratory testing. Interstitial ectopic pregnancy is the rarest variety of ectopics⁵. Thick and vascular muscle bulk of uterus may maintain the pregnancy for 12 to 16 weeks. Rupture of ectopic pregnancy from the

uterine surface is more serious due to massive intraperitoneal hemorrhage that occur within very short time. Presented case was hemodynamically stable. For the last two decades, hemodynamically stable patients also have been managed with medical therapy. This group of patients must be put for methotrexate therapy⁶. Conservative surgery and methotrexate therapy group requires weekly follow up for B-hCG level monitoring till it become zero to ensure that treatment is complete, because 5-15% cases the trophoblastic activity is persisted⁷.

Conclusion:

It is very difficult to diagnose interstitial ectopic pregnancy before rupture. Asymmetric enlargement of uterus is confused with lateral flexion of gravid uterus, pregnancy associated with fibroid, pregnancy is bicornuate or angular pregnancy. B-hCG, transvaginal ultrasonography and laparoscopic intervention is helpful for confirmation of interstitial pregnancy. Laparotomy should be avoided as far as possible. Methotrexate is contraindicated for a good number of cases. Laparoscopic intervention & appropriate management gives rise maximum success with minimum complication.

Reference:

1. Gazvam MIR, Baruah DN, Alfirevic Z et al Mifepristone combination with methotrexate for the medical treatment of tubal pregnancy: A randomized controlled trial. Hum report 13: 7,1998.
2. Vicken Sepilian MD - Ectopic pregnancy www. emedicine.com/11 topic 3212.htm, nov 24, 2004, 1-16.
3. Herman, A. Weinraub, Z, Avrech, O et al. Follow-up and outcome of isthmic pregnancy located in a previous cesarean scar. Br. J. Obstet. 1995, 11-14.
4. Gracia CR, Bamhart KT Diagnosing ectopic pregnancy decision analysis comparing six strategies Obstet Gynecol 2001; 93: 464-70
5. Fyistra DL Tubal pregnancy a review of current diagnosis and treatment Obstet Gynecol surv 1998 May; 53(5): 3.
6. Ranson MX, Garcia AJ, Bohrer M et al: Serum progesterone as a predictor of methotrexate success in the treatment of ectopic pregnancy. Obstet Gynecol 1994 Jun; 83(6): 1033-7.
7. Nieuwesck PT, Hajenius Pj, Van der veen F et al: Systemic methotrexate therapy versus laparoscopic salpingostomy Fertil Steril 1998 Sep, 70(3): 518-22(Med line).