

## CASE REPORTS

# Metastatic Jaw Swelling as the First Manifestation of Adrenal Malignancy: A Case Report

SMA SADAT<sup>a</sup>, SN RITA<sup>b</sup>, M AHMED<sup>c</sup>

### Summary:

*This case report is of a 65-year-old man with two large soft tissue swellings in upper & lower jaws for 20 days. Incision biopsy revealed metastatic carcinoma with possible primaries was – adrenal gland and kidney. Metastatic adenocarcinoma in left lung and primary mass*

*in right adrenal gland were diagnosed by other relevant investigations. Due to unfavorable general condition, Chemotherapy could not be started. Patient died 20 days after the confirmation of diagnosis & during the course of radiotherapy.*

*(J Bangladesh Coll Phys Surg 2007; 25 : 153-156)*

### Introduction:

About 1% of the malignant tumors of the body metastasize to the oral cavity<sup>1</sup>. Metastatic tumors in jaws and oral soft tissues are very rare. They represent about 1% of all oral malignancies<sup>2,3,4</sup>. These tumors usually come from lung, breast, genital organs, thyroid, prostate, kidney, bone and adrenals. The following report describes a case of right adrenal tumor with metastasis to the oral soft tissues of both upper and lower jaws, which is very rare. Although most of the lesions of adrenal glands are benign adenomas, adrenocortical carcinomas and metastases constitute 5% to 10% of all tumors<sup>5</sup>. Sometimes they are incidentally detected and can be confirmed by abdominal ultrasonography, computed tomography, magnetic resonance imaging and core biopsy. The purpose of this article is to report an additional example, which was recognized as the first manifestation of adrenal malignancy.

### Case report:

A 65-year-old man was referred from Chittagong Medical College to the department of Oral & Maxillofacial Surgery, Dhaka Dental College & Hospital, Dhaka, Bangladesh on 4<sup>th</sup> August 2005 for evaluation of two rapidly progressive swelling in right maxillary and left mandibular soft tissue growth. The patient noticed two small painless swelling in his right upper and left lower jaw 20 days back. The swellings were very rapidly growing and were associated with mastication problem & general weakness. Patient had not given any history of bleeding from the mass. The past medical history did not reveal any significant disease with no history of chest discomfort or abdominal pain or mass. He had moderate hyperacidity and occasional cough. Patient was habituated with cigarette smoking for last 30 years.

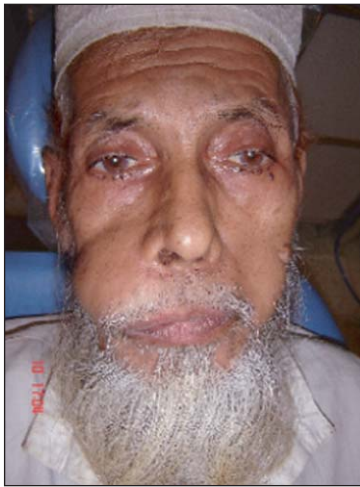Physical examination showed a lean and thin, malnourished, old man with emaciated facies. He was a febrile and recorded blood pressure and pulse rate were 140/90 mm of Hg and 82/min respectively. Facial asymmetry was evident owing to the swelling in both right upper and left lower face (Fig 1). Intra-orally, right maxillary soft tissue swelling was sessile, firm, non-tender, smooth surface, normal color, measuring 6x5 cm (Fig 2). On the left lower jaw another swelling of 5x4 cm was evident with the same features as above (Fig 3). Both masses were in the molar regions displacing the involved teeth. Both sub-mandibular lymph nodes were enlarged, non-tender, free, firm in consistency with 1 cm in diameter. Other cervical lymph nodes were normal. Clinical examination of chest and abdomen revealed normal findings.

- a. Dr. S. M. Anwar Sadat, BDS, BCS, MCPS, FCPS (OMS), OSD (DGHS) Deputed to DDCH, Dept of Oral & Maxillofacial Surgery, Dhaka Dental College & Hospital, Dhaka, Bangladesh.
- b. Dr. Sufia Nasrin Rita, BDS, Resident, Dhaka Dental College & Hospital, Dhaka, Bangladesh.
- c. Prof. Mohiuddin Ahmed. BDS, PhD, Head, Dept of Oral & Maxillofacial Surgery, Dhaka Dental College & Hospital, Dhaka, Bangladesh.

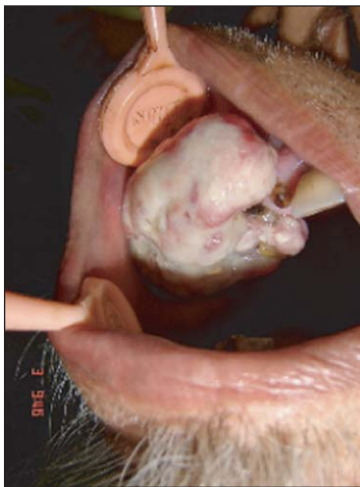**Address of correspondence:** Dr. S. M. Anwar Sadat, BDS, BCS, MCPS, FCPS (OMS), OSD (DGHS) Deputed to DDCH, Dept of Oral & Maxillofacial Surgery, Dhaka Dental College & Hospital, Dhaka, Bangladesh, Tel: 9672033, 01711156023, e-mail: an\_sadat@yahoo.com

**Received:** 9 October, 2006

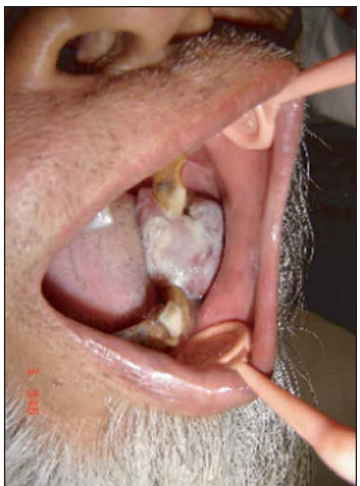**Accepted:** 6 January, 2007



**Fig 1:** Extra-oral Photograph



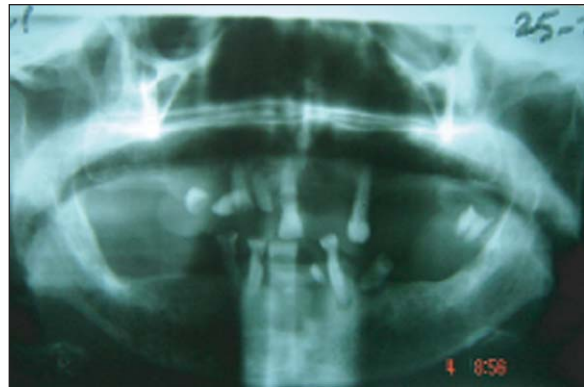
**Fig 2:** Intra-oral Photograph Rt maxillary mass



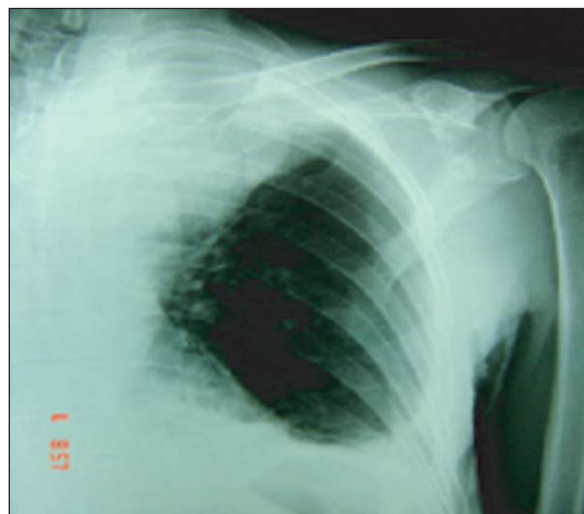**Fig 3:** Intra-oral Photograph Lt mandibular mass

Panoramic radiograph showed soft tissue swelling in the above-mentioned areas with some pressure erosion to the underlying bone (Fig 4). All relevant hematological values were within normal range except ESR 70 mm in 1<sup>st</sup> hour. Incision biopsy of both lesions reported poorly differentiated malignancy suggesting of metastatic carcinoma with possible primaries of adrenal gland and kidney (Fig 6,7).

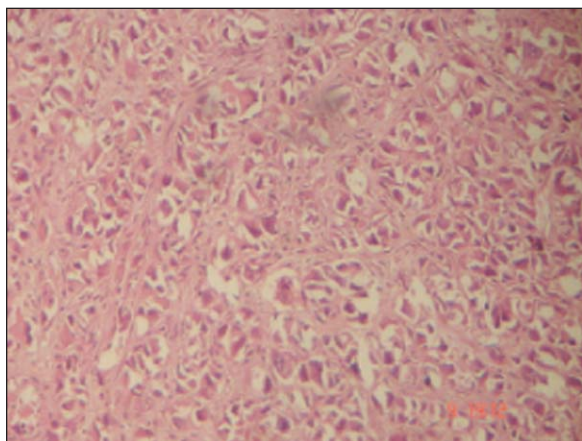
Ultra sonogram of whole abdomen revealed a fairly big (5.6x5.0 cm) solid mass above the right kidney well separated from kidney and appears to be an adrenal mass. Chest radiograph showed ill defined medium dense homogenous opacity in left upper and lower zones obliterating left costophrenic angle and left dome of diaphragm indicating the consolidation with pleural effusion due to bronchial neoplasm (Fig 5). CT guided FNAC of the bronchial mass reported metastatic adenocarcinoma. By this time patient was



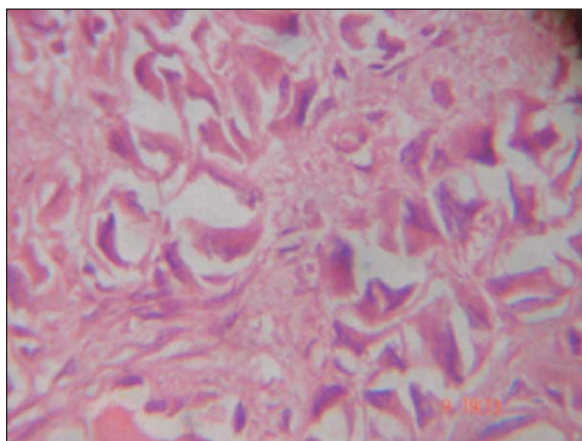
**Fig 4:** Orthopantomogram of jaws



**Fig 4:** Orthopantomogram of jaws



**Fig 6:** Low power microscopic view



**Fig 7:** High power microscopic view

very weak and debilitated and so analysis of adrenal mass and bone scan were not performed. With all documents patient was referred to oncology department where radiotherapy started. Chemotherapy could not be planned due to unfavorable general condition. Patient died 20 days after diagnosis (during the course of radiotherapy).

#### Discussion:

Tumors that metastasize to the oral soft tissues are very rare, comprising only 0.1% of oral malignancies<sup>6,7</sup>. The majority of the oral metastasis occur in jaws (90%), and only about 10% occur in the soft tissues<sup>1</sup>. Of the later, 5% are in the tongue, 4% in the gingiva and cheek and 1% in the elsewhere<sup>1</sup>. The most common sites of primary tumors in female are in breast (42%), adrenals (8.5%), genital organs (7.5%) and thyroid (6%)<sup>8,9</sup>. In men the most frequent sites are lung (22.3%), prostate (12%), kidney

(10.3%), bone (9.2%) and adrenals (9.2%)<sup>8,10</sup>. In most of the cases malignant cells disseminate mainly to the premolar and molar regions of the mandible where, in a significant number of cases, they can be recognized as the first manifestation of a yet undiagnosed malignant tumor<sup>4,11</sup>. The report describes a case of right adrenal tumor with metastasis to the oral soft tissues of both upper and lower jaws, which is very rare and the presentation was limited to the oral cavity only. Simultaneously metastasis occurred in left lung which was diagnosed by CT guided FNAC. After Ultrasonographic evaluation, the adrenal mass can be diagnosed properly by CT guided FNAC or core biopsy. Adrenal core biopsy is a useful method for identifying and classifying adrenal tumorous lesions if sufficient biopsy specimens can be obtained. However, in clinical practice it remains to be shown whether the benefits of biopsy outweigh the risks of the procedure<sup>5</sup>. In this reported case it was not practiced due to deterioration of patients general condition. Snyder MB et al. reported a case of similar adrenal tumor metastasized to jaw and pulpal tissue in 71/2 - year-old boy<sup>12</sup>. Most of the time, duration of survival of patient becomes short after diagnosis of secondary metastasis. In this case patient died 20 days after the diagnosis. Surgical treatment of metastatic mass is not recommended. Combination Chemotherapy and Radiotherapy can often increase the duration of survival of patient. Due to poor general health, Chemotherapy could not be started in this reported case. Only Radiotherapy to the jaw lesions was applied for controlling the rapid growth of lesion. From the reported case the maxillofacial surgeons should be reminded that 1% of oral cavity malignancies represent metastatic disease, and this reinforces the necessity of maintaining a high index of suspicion for metastatic lesions, even in the most unlikely locations.

#### References:

1. Bhaskar SN. Oral manifestation of metastatic tumors. *Postgraduate med*1971; 49:155-57.
2. Bertelli AP, Costa FA, Miziara JFA. Metastatic tumors of the mandible. *Oral Surg Oral Med Oral Pathol* 1970; 30:21-24.
3. Meyer I, Shklar G. Malignant tumors metastasis to the mouth and jaws. *Oral Surg Oral Med Oral Pathol* 1965; 20:350-54.

4. Stypulkowska J, Bartkowski S, Pana's M, et al. Metastatic tumors to the jaws and oral cavity. *J Oral Surg* 1979; 37:805-809.
5. Saeger W, Fassnacht M, Chita R, et al. High diagnostic accuracy of adrenal core biopsy: results of the German and Austrian adrenal network multicenter trial in 220 consecutive patients. *Hum Pathol* 2003; 34:180-6.
6. Shklar G. *Oral Cancer*. Philadelphia, PA. Saunders. 1984. pp-273-275.
7. van der Waal RIF, Buter J, van der Waal I. Oral metastases: report of 24 cases. *Br J Oral Maxillofac Surg* 2003; 41:3-6.
8. Hirshberg A, Leibovich P, Buchner A. Metastatic tumors to the jaw bones: analysis of 390 cases. *J Oral Pathol Med* 1994; 23: 337-341.
9. Adelson RT, DeFatta RJ, Miles BA, Hoblitt SL, Ducic Y. Metastatic breast cancer to the oral cavity. *American Journal of Otolaryngology-Head and Neck Medicine and Surgery* 2005; 26:279-281.
10. Zakaria M, Hock KLL. Renal Cell Carcinoma Metastasis to the Mandible. *Asian J Oral Maxillofac Surg* 2004; 16: 189-194.
11. Zachariades N. Neoplasm metastasis to the mouth, jaws and surrounding tissues. *J Craniomaxillofac Surg* 1989; 17:283-86.
12. Snyder MD, Cawson RA. Jaw and pulpal metastasis of an adrenal neuroblastoma. *Oral Surg Oral Med Oral Pathol*. 1975 ;40:775-84.