

Ladd's Band - A Case Report

MA JAIGIRDAR^a, A RAHMAN^b, MN HUQ^c, EUA CHOWDHURY^d, AK MASOOM^e, AA SHAIKH^f

Summary:

We present here a 7 years' old boy presented with recurrent abdominal pain and vomiting causing severe growth failure since 6 months of age. He had some dysmorphism including fish like mouth, upturned nostrils, hypertelorism, low set posteriorly rotated ears, absence of left kidney and closing

ventricular septal defect (VSD). Barium study revealed extrinsic obstruction in duodenal 3rd part with high up caecum. Laparotomy showed Ladd's band. Ladd's procedure was done upon this child, which led to resolution of his clinical abdominal problems.

(J Bangladesh Coll Phys Surg 2007; 25 :157-160)

Case Summary

Joy, a boy of 7, from Dhaka was admitted in Bangladesh Medical College Hospital on 02.07.2005 with recurrent upper abdominal pain and vomiting with severe wasting since 6 months of age. His grandmother said that he was growing almost uneventfully up to 6 months of age. Each attack of abdominal pain and vomiting usually lasted for 4-5 days. The problem recurred in an almost similar pattern once in every 2-3 weeks. The pain was localized, moderate to severe occurring around the umbilicus, comes and goes, and aggravated by food intake. Occasionally he feels a dull aching pain in both loins. During each attack he vomits several times mostly after meals. Vomiting is not projectile, and contained only food particles, no blood, and no bile.

He gets severely constipated during each episode. Joy did not have any urinary complaints. Parents were concerned, as their child was not growing rather getting stunted and wasted. He was admitted at least 20 times in different hospitals till to date. Once he was admitted in a hospital where he was investigated and suspected to be a syndromic child with congenital absence of left kidney, VSD and gastro-esophageal reflux disease (GERD). Joy was born full term normally at home. Mother had regular antenatal care and the pregnancy was uneventful. He cried just after birth and sucked breasts strongly. Feeding was otherwise normal. Joy was immunised. His growth was normal for the first 6 months. Developmental milestones were satisfactory.

- a. Dr. Mutaher Ahmed Jaigirdar, MBBS, DCH, MRCP (UK), Associate Professor; Department of Paediatrics, Bangladesh Medical College.
- b. Dr. Anisur Rahman, MBBS, FCPS, FRCS, FICS, MSc, Professor, Department of Surgery, Bangladesh Medical College
- c. Dr. Mohammad Nurul Huq, MBBS, DTCH, FCPS, Professor and Head; Department of Paediatrics, Bangladesh Medical College.
- d. Dr. Ehsaan - Ul - Alam Chowdhury, MBBS, Assistant Registrar; Department of Paediatrics, Bangladesh Medical College.
- e. Dr. Ahsan Kabir Masoom, MBBS, DCH, Registrar, Department of Paediatrics, Bangladesh Medical College.
- f. Dr. Ashraf Ali Shaikh, MBBS, DCH, MRCP, Assistant Professor, Department of Paediatrics, Bangladesh Medical College.

Address of Correspondence: Dr. Mutaher Ahmed Jaigirdar, MBBS, DCH, MRCP (UK), Associate Professor; Department of Paediatrics, Bangladesh Medical College, E-mail: - mnurulhuq@hotmail.com

Received: 6 December, 2005

Accepted: 24 January, 2007

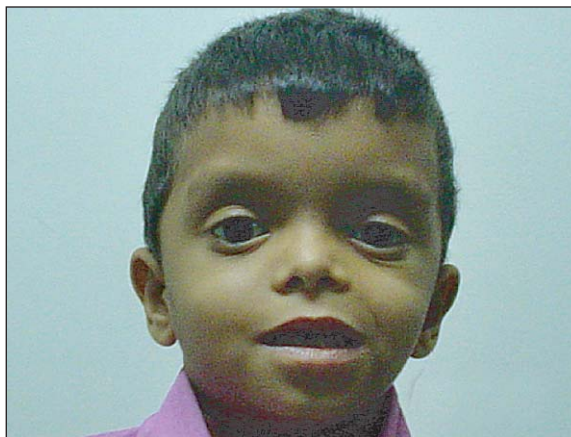

Fig 1: Joy with dysmorphic face

Joy is the only child of his nonconsanguineous parents. Other family members are reasonably well. Physically, Joy was looking grossly emaciated and stunted. His weight was 10 kg (35% of reference value of CDC; far

below the 3rd centile), height 95 cm (71.2% of reference value of CDC, far below the 3rd centile), Occipitofrontal Circumference (OFC) 44 cm (reference value for 6 and half months according to CDC); and Mid Arm Circumference 14 cm. His psychomotor, visual, hearing and speech development was absolutely normal. Joy was looking dysmorphic with fish like mouth, upturned nostrils, hypertelorism, low set posteriorly rotated ears, looking pale but no jaundice, oedema or enlarged lymph nodes. Pulse was 68/min, temperature 98°F and breathing 16. He was alert and cooperative. Heart showed normal S1 and S2 with no murmur. Chest was normal. There was no abdominal distension, tenderness, nor any organomegaly. CNS examination revealed normal findings. Laboratory data following admission shows normal peripheral blood count and film study; normal liver functions, and urinalysis. Electrolytes and renal functions were normal. USG revealed no abdominal organomegaly with absence of left kidney. DTPA shows absence of left kidney with normally functioning right kidney. IVU shows non-visible left kidney with normal right kidney. Color Doppler echocardiography done earlier (2004) showed two small perimembranous VSD (almost closing), mild Tricuspid Regurgitation with normal pulmonary arterial pressure. Barium meal and follow-through showed eccentric narrowing of 3rd part of duodenum from outside with thicker mucosal pattern of upper jejunum and high up caecum.

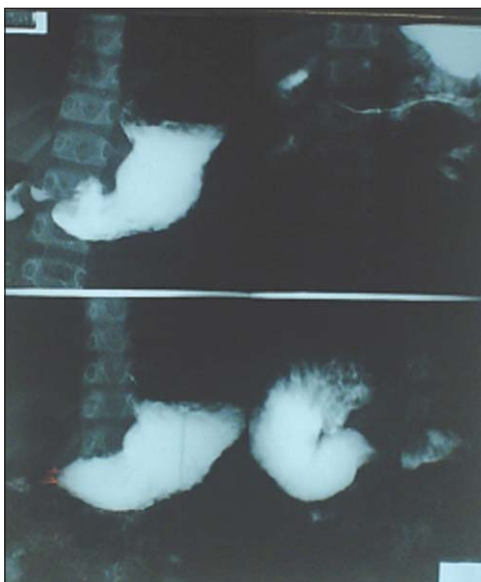


Fig-2: Barium meal of upper GIT shows narrowing of the 3rd part of duodenum.

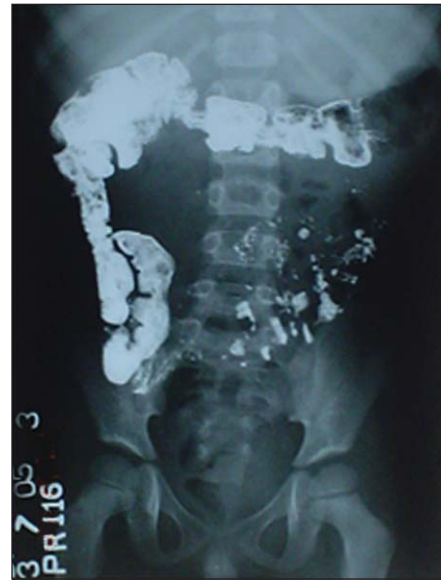

Fig-3: Ba-meal and follow-through of upper GIT shows high up caecum.

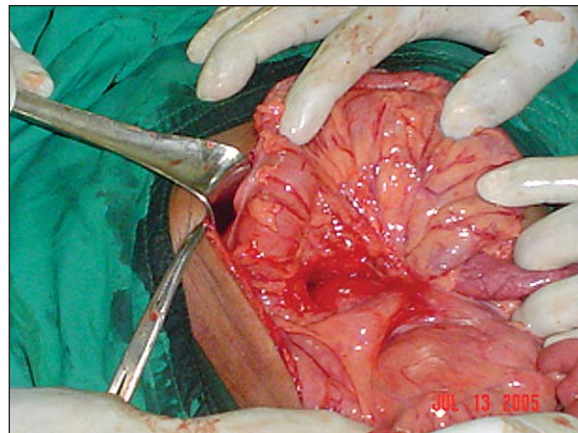


Fig-4: Shows peroperative view of Ladd's band.

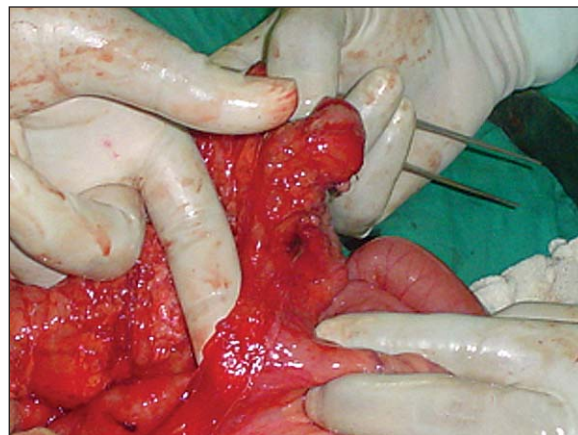


Fig-5: Shows Ladd's band

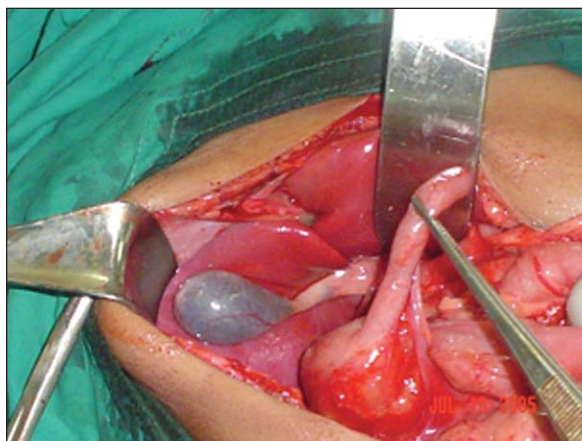


Fig-6: Shows high up caecum almost under the gall bladder

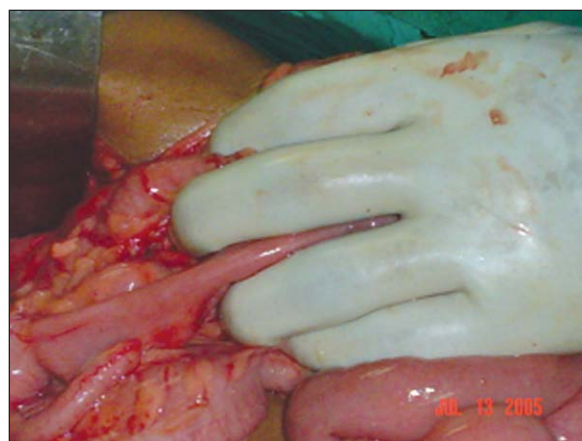


Fig-7: Ladd's procedure is being done

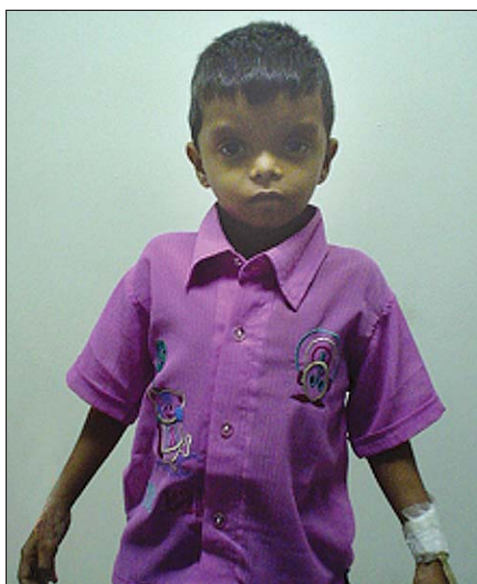

Fig-8: Joy after corrective surgery

Laparotomy was done and revealed normal stomach but dilated first and second duodenal parts. Caecum was high up, almost under the gallbladder. There were lot of bands between caecum and right paravertebral gutter. The band was carefully divided. Kocherization of duodenum done. The caecum was transferred to *left* iliac fossa and appendicectomy was carried out. Postoperative recovery was uneventful. He went back home with advice to take small frequent meals. Zinc, iron, and multivitamins were supplemented. Joy was advised to report after 2 weeks. Joy reported after 1 month with no abdominal complaints and gained a weight of 2 kilograms.

Discussion

Extrinsic obstruction of the duodenum may be caused by congenital peritoneal band, intestinal malrotation, annular pancreas, preduodenal portal vein and duodenal duplication.^{1,2,3} Peritoneal band is always associated with intestinal malrotation, which means an incomplete rotation of intestine during fetal development. There are 4 types of congenital peritoneal band. In type 1, caecum that lies abnormally in right upper quadrant of the abdomen, has a band, which extends across the 2nd and 3rd parts of the duodenum to the paravertebral gutter, this band is called Ladd's Band. Duodenal obstruction may result from either compression by Ladd's Band and/or from midgut volvulus. The type 2 band extends from the hepatic flexure of the colon across the 2nd part of duodenum to the right paravertebral gutter, causing duodenal compression at that site. The type 3 band is the hypertrophied hepatoduodenal ligament, which obstructs the duodenum at the junction of its 1st and 2nd parts. The type 4 band is a dense fibrous band which binds the distal portion of the 3rd part of the duodenum to the paravertebral fascia, causing extrinsic obstruction and is always associated with an incompletely rotated duodenum.⁴ It seems that this case falls in the type 1 category.

Clinical diagnosis of congenital band with malrotation in older child is not always easy because of its non-specific presentation. Commonest complaints are intermittent colicky abdominal pain (100%), recurrent vomiting (89%), haematemesis and constipation (55%). Repeated episodes of bloody stool, diarrhoea and failure to thrive (44%).⁵ In all cases of persistent vomiting specially biliary a contrast Ba-meal and

follow-through study should be done which is diagnostic if correctly interpreted.^{6,7} It should be remembered that congenital peritoneal band is always associated with malrotation and this can cause volvulus of the midgut. In one series 31 out of 219 children had volvulus, 7 needing resection with one death.^{8,9} Therefore, once band is diagnosed Ladd's procedure should be routinely done. Nowadays, it can be done by laparoscopy having the advantage of short convalescence and low morbidity.^{10, 12} The association between gastro-esophageal reflux (GER) and intestinal malrotation has well been described. Delayed or impaired gastric emptying is thought to be a contributing factor in the development of GER.¹¹ This child was having persistent periodic vomiting and got different brands of anti-reflux drugs with little benefit. This should have had raised the query to clinician's mind about the possibility of malrotation. Recurrent pancreatitis is also described in malrotation by some authors and this resolved spontaneously after Ladd's Procedure.¹² This child with some dysmorphic features having absent left kidney, closing VSD, recurrent abdominal pain and vomiting eventually developed severe growth failure and protein energy malnutrition. Single malformation in one system should warn the clinician to have a look for anomalies into other systems. A simple investigation like barium-meal and follow-through would have solved this child's problems much earlier. Any child with long standing periodic vomiting with recurrent abdominal pain causing growth failure an upper GIT barium study should be a routine procedure.

Acknowledgement

1. Dr. Moffakharul Ahmed, Registrar, Department of Surgery, Bangladesh Medical College Hospital
2. Dr. Sayed Khalid Hasan, Registrar, Department of Surgery, BMCH

3. Dr. Shahnewaz Kamal, interneer doctor, Department of Paediatrics, Bangladesh Medical College Hospital
4. Dr. Md.Ashraf Uddin Ahmed, interneer doctor, Department of Paediatrics, Bangladesh Medical College Hospital

References

1. Harberg FJ, Pokorny WJ, Hahn H. Congenital duodenal obstruction: a review of 65 cases *Am J Surg* 1979; 138:825-8
2. Tryfonas G, Young DG. Extrinsic duodenal obstruction in infants and children. *Br J Surg* 1975; 62:125-9
3. Wayne ER, Burrington JD. Extrinsic duodenal obstruction. *Surg Gynecol Obstet* 1973; 136:87-91
4. Akgur FM, Tanyel FC, Buyukpamukcu N, Hicsonmez A. Anomalous congenital bands causing intestinal obstruction in children. *J Pediatr Surg* 1982;27:471-3
5. Uba AF, Chirdan LB, Edino ST. Intestinal malrotation: presentation in the older child. *Niger J Medicine*. 2005; 14(1): 23-6
6. Millar AJ, Rode H, Cywes S. Malrotation and volvulus in infancy and childhood. *Semin Pediatr Surg*. 2003 Nov; 12(4): 229-36
7. Strouse PJ. Imaging and the child with abdominal pain. *Singapore Medicine J*. 2003; 44(6): 312-22.
8. Malek MM, Burd RS. Surgical treatment of malrotation after infancy: a population-based study. *J Pediatr Surg*. 2005; 40(1): 285-9.
9. Strouse PJ. Disorders of intestinal rotation and fixation ("malrotation"). *Pediatr Radiol*. 2004; 34(11): 837-51
10. Adrales GL, Gandsas A, Beales Disease, Draper K, George IM, Park AE. Laparoscopic Ladd's procedure in two adults: malrotation and the minimally invasive approach. *Surg Endosc*. 2004 Jan; 18(1): 161
11. Demirbilek S, Karaman A, Gurunluoglu K, Akin May, Tas E, Aksoy RT, Kekilli E. Delayed gastric emptying in gastro-oesophageal reflux disease: the role of malrotation. *Pediatr Surg Int*. 2005 Jun; 21(6): 423-7
12. Sasaki T, Soh H, Kimura T, Hasegawa T, Okada A, Fukuzawa M. Recurrent acute pancreatitis caused by malrotation of the intestine and effective treatment with laparoscopic Ladd's procedure. *Pediatr Surg Int*. 2005 Jun 17.