

CASE REPORT

Weber Christian Disease: A Case Report

MM HOSSAIN^a, S AFROZA^b, ARML KABIR^c, O HAQUE^d, M HOSSAIN^e

Summary:

A 9-year-old male child presented with fever, polyarthritis, cough and difficult breathing. He had characteristics skin lesion and reticulonodular shadows on chest X-ray.

Introduction

Weber-Christian disease is a rare and poorly understood disorder of the adipose tissue.^{1,2} The exact aetiopathogenesis of this condition is largely unknown and it is also called idiopathic lobular panniculitis.³ In 1892, Pfeifer first described the skin condition now known as Weber-Christian disease, or idiopathic lobular panniculitis.^{4,5} In 1925, Weber further depicted the syndrome as case of "relapsing non-suppurative nodular panniculitis".^{6,7} In 1928, Christian emphasized the significance of fever as a part of the syndrome.⁸ Henceforth, the syndrome is known as Weber-Christian disease. WCD may occur in young children, but it mostly affects people from fourth to seventh decades of life. The skin manifestation is reflected by recurrent crops of erythematous, sometimes tender and edematous subcutaneous nodules. The lesions are symmetric in distribution and predominantly involve the lower extremities but lesions can also occur on the trunk, upper extremities and rarely on the face.⁹ The lesions resolve in a couple of weeks, leaving an atrophic depressed scar.¹⁰ Malaise, fever, and arthralgia frequently occur. Nausea, vomiting, abdominal pain, weight loss, bone pain, myalgia, hepatomegaly and or splenomegaly may

Initially, it appeared to be a case of sarcoidosis but finally histologically proved to be a rare adipose tissue disorder - Weber Christian disease (WCD).

(J Bangladesh Coll Phys Surg 2007; 25 : 43-46)

also occur. WCD may involve the internal organs like lungs, heart, intestines, spleen, kidney, and adrenal glands. In patients with inflammation involving visceral organs, significant morbidity and mortality may occur.¹¹ WCD being a rare condition and our experience of good therapeutic response to corticosteroid prompted us to report this case and highlight the clinical and diagnostic features.

Case Report

A 9-year-old male child, 1st issue of a day-labourer, weighing 21.5 kg, immunized as per EPI schedule admitted into ICMH, Dhaka with the complaints of fever for two years, pain and swelling of multiple small and large joints for one and a half year, non-productive cough and difficult breathing for 10 days before admission. The joint pain was not migratory and there was no history of morning stiffness. He had been suffering from repeated attacks of common cold since 2 years of age. He denied any history of trauma or abdominal pain. There was no history of contact with a tubercular patient.

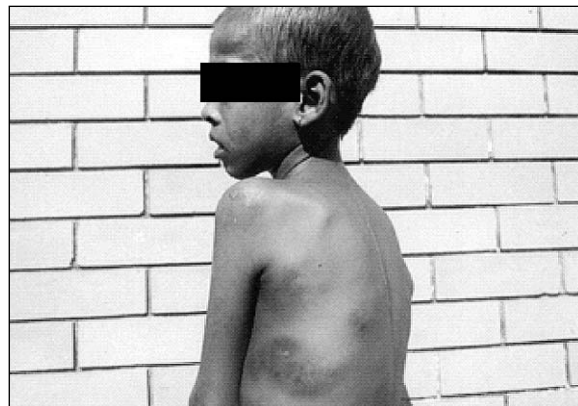

Fig-1: 9 years old boy with multiple erythematous nodules.

- a. Dr Mohammad Monir Hossain, Sadar Hospital, Brahmanbaria.
- b. Prof. Syeda Afroza, Professor of Paediatrics & Joint Director, Institute of Child and Mother Health (ICMH), Dhaka.
- c. Prof. ARML Luthful Kabir, ICMH.
- d. Dr. Obaidul Haque, Medical Officer, Companigonj, Sylhet.
- e. Dr. Monira Hossain, Assistant Registrar, ICMH

Address of Correspondence : Dr Mohammad Monir Hossain, Child Specialist, Sadar Hospital, Brahmanbaria, Email: monir91@yahoo.com, monir91@gmail.com

Received: 15 March, 2006

Accepted: 22 November, 2006

On examination, he was found dyspnoeic, mildly pale, febrile, tachypnoeic and had tachycardia. He had multiple erythematous nodules over the back of the trunk (Fig. 1) and dorsal aspect of hands (fig-2). The nodules had atrophic central area. Locomotor system examination revealed swollen and tender knees, ankles, elbows, wrists and small joints of hands. He had apex beat in the left 5th intercostal space just lateral to mid clavicular line, palpable P2 and gallop rhythm. Lungs were full of crackles and rhonchi. He also had hepato-splenomegaly with ascities. Other systemic examinations were normal.

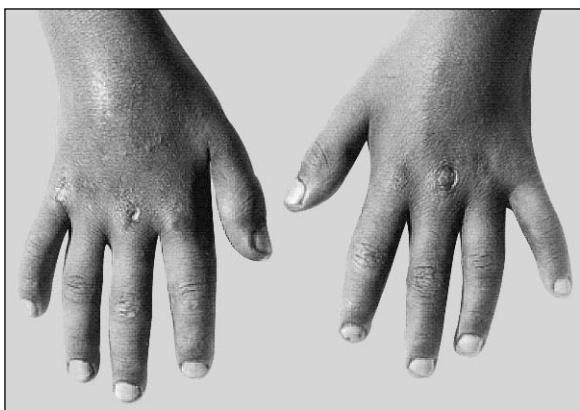

Fig-2: Erythematous nodules with atrophic central area and swollen small joints of hands.

Laboratory investigations showed Hb 10 gm/dl, total WBC counts 18,600/cmm with neutrophilic leukocytosis (P 77%) and raised ESR (43 mm in first hour). Urinalysis showed hematuria (15-20 RBC/HPF). Blood biochemistry was normal for renal and hepatic function. Immunological tests were negative: rheumatoid factor, L.E. cells, antinuclear antibody, p-ANCA and c-ANCA. There were bilateral reticulonodular shadows in the lungs on radiology (fig-3) and mild tricuspid regurgitation on echocardiography. USG showed organomegaly and ascitis but no evidence of pancreatitis. Skin biopsy showed subcutaneous fat lobules necrosis with massive infiltration of neutrophils, lymphocytes and histocytes.

There were good numbers of foamy macrophages. The epidermis was unremarkable. But dermis was replaced by fibrous tissue except for one focus which contained amorphous matrix having foam cells,

lymphocytes and neutrophils. No granuloma or malignancy was observed. These features were compatible with Weber - Christian disease (WCD).

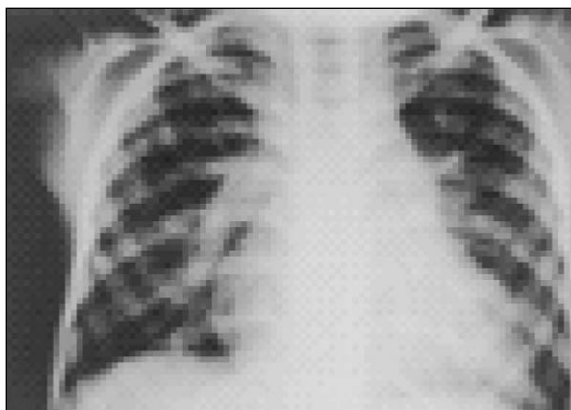


Fig-3: Showing multiple reticulo nodular shadow in both lungs.

The child had good therapeutic response with steroid and other supportive measures within two weeks of initiating therapy. He was on monthly follow-up. One year clinical, hematological and radiological follow-up revealed no relapse of the disease with disappearance of nodules, regression of hepatosplenomegaly, disappearance of ascitis, normal ESR (11mm), and marked improvement of reticulonodular shadows on lung fields.

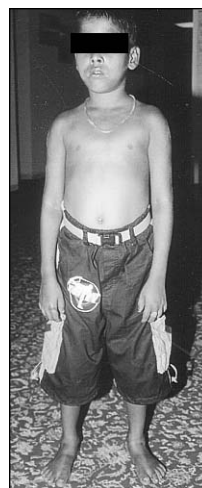

Fig-4: After remission from WCD.

Discussion

A child presenting with long term fever, cough, hepatosplenomegaly, arthritis with reticulonodular shadows on CXR should be considered for the

following differential diagnoses: Disseminated TB, sarcoidosis, mixed connective tissue disease and WCD. Weber-Christian disease is a rare disorder of adipose tissue. A number of cases have been reported with other disease processes like systemic lupus erythematosus.¹² Clinically, it is characterized by acute remittent febrile illness associated with recurrent crops of multiple, tender, subcutaneous nodules occurring most commonly on the thighs and legs but may involve the arms and sometimes the trunk. Usually over a period of few weeks the nodules subside leaving an atrophic depressed scar. Occasionally, the epidermis overlying the nodules breaks down, and the lesion discharges a brown liquid oil (liquefying panniculitis). In individuals with WCD with visceral involvement, hepatomegaly or splenomegaly may be present. Weber-Christian disease may involve the lungs, heart, intestines, liver, spleen and kidney as found in our case. WCD having visceral involvement, significant morbidity and mortality may occur. WCD with only cutaneous manifestations, the clinical course may be characterized by exacerbations and remissions of the cutaneous lesions for several years before the disorder subsides. No racial predilection appears to exist. Histopathological changes of subcutaneous nodules can be described in three stages: Weber-Christian disease Stage 1 - characterized by an acute inflammatory reaction, in which lobules of fat are replaced by neutrophils, lymphocytes and histiocytes. Stage 2 - macrophages migrate and phagocytose degenerated fat, forming characteristic foam cells. Stage 3 - the foam cells are replaced by fibroblasts, and the inflammatory reaction is replaced by fibrotic tissue.¹¹ The studied case conforms to WCD stage-2. However, there may be associated vasculitis in rare instances.¹³

Serum and urinary amylase, lipase and alpha-1-antitrypsin levels could not be measured due to limitations.

Good therapeutic response with corticosteroid has been reported by various workers which has been used in the present case.^{14,15} Present case also had favourable therapeutic response to corticosteroid and

had no recurrence of the disease over one year follow-up period. Individuals with WCD should be monitored and followed up for progression of the disease and adverse effects of medications. No effective methods of prevention have been discovered.

Therapeutic responses have been reported with the use of fibrinolytic agents, hydroxychloroquin, azathioprine, thalidomide, cyclophosphamide, tetracycline, cyclosporin and mycophenolate. Non-steroidal anti-inflammatory agents may reduce fever, arthralgia and other symptoms. Involvement of specific organs may require specific supportive drugs. No surgical treatment is indicated.

When the condition subsides prophylaxis may be unnecessary.

Conclusion: When a pediatrician comes across in clinical practice with a child having either polyarthritis or reticulonodular appearance of lungs on CXR or both associated with skin lesions, WCD should be in the differential diagnosis.

References

1. Inflammatory disorders of the subcutaneous fat. Rook's Text Book of Dermatology. In: Burn T, Breathnach S, Cox N and Griffiths C, editors. Vol. III, 17th edn. Oxford, London, Edinburgh and Melbourne: Blackwell Scientific Publications Ltd; 2004: 55.9 - 11.
2. Negalur VG, Negalur BV. Weber Christian Disease: a case report. JAPI. JULY 2003; 51: 724
3. MacDonald, A and Feiwel, M: A review of the concept of Weber-Christian panniculitis with a report of 5 cases. Brit J Dermatol. 1968; 80: 355-361.
4. Pfeifer V. Uber einen Fall von Herdweiser: atrophie des subcutanen Fettgewebes. Dtsch Arch Klin Med 1892; 50: 438 - 49.
5. Levy ML, Lifshitz O. Weber-Christian Disease. eMedicine Journal Specialties. Texas: October 2002.
6. Weber F P: Relapsing, non-suppurative, nodular, panniculitis showing phagocytosis of subcutaneous fat cells by macrophages. Brit J Dermatol. 1925; 37: 301-311.
7. Christain HA. Relapsing febrile nodular non-suppurative panniculitis. Arch Intern Med 1928; 42: 338 - 51.
8. Forstrom L and Winkelmann, R K: Acute panniculitis: A clinical and histopathological study of 34 cases. Arch. Dermatol. 1977; 113: 909-918.

9. Pambor M, Kemnitz P, Theuring F: Panniculities nodularies febriles "nonsuppurativa" (Morbus Pfeifer - Weber - Christian) mit foundroyant-letelem Verlauf nach langjahrigem afebrilem Be-stehen. *Dermatol Monatsschr*, 1969; 155: 330-339.
10. Oram S. and Cochrane, G. M.: Weber-Christian disease with visceral involvement. An example with hepatic involvemen. *Brit Med J*. 1958; 281-284.
11. Singh NK, Singh DS. Weber-Christian disease (febrile relapsing non-suppurative nodular panniculitis) (a case report). *J Postgrad Med* 1984; 30:49-50.
12. Winkelmann, R K: Panniculitis and systemic lupus erythematosus. *J Amer Med Assoc*. 1970; 211: 472-475.
13. Spain D M and Foley J M: Non-suppurative, nodular panniculitis (Weber-Christian disease). *Amer J Pathol*. 1944; 20: 783-787.
14. Crosbie S Treatment of a case of relapsing panniculitis with cortisone and A.C.T.H. *Ann Intern Med*. 1955; 43: 622 - 631.
15. Monga J N, Kawthekar P W, Monga S and Muzumdar D A: Weber-Christian disease. Report of a case and results of a trial with ACTH therapy. *Ind J Med Sci.*, 1958; 12: 165-169.