

Giant Scrotum – A Case Report

MS HOQUE^a, SMSA CHAUDHURY^b, ANM ILIAS^c, FS NUR^d

Summary:

A 45 years male beggar admitted to this hospital with a huge swelling of scrotum and penis and bipedal nonpitting edema. This swelling was gradually increasing which hampered his personal life. He was previously diagnosed as a case of filarial scrotum and penis. He took

diethylcarbamazine (DEC) for 4 years. CFT for filaria was strongly positive but microfilariae in the blood were not detected even after provocative test. Total 15 kg of scrotal penile skin was removed and reconstructed by trunk skin flaps.

(J Bangladesh Coll Phys Surg 2009; 27: 173-176)

Introduction

Massive scrotal lymphedema, also termed elephantiasis, can be caused by obstruction, aplasia or hypoplasia of lymphatic vessels¹. Lymphatic Filariasis is the leading type of lymphedema worldwide, affecting an estimated 120 million people. It is an endemic conditions located in the tropical regions of the world. These areas include SE Asia, the Indian sub-continent, Africa, and areas of South America. Infestations of infection by a microscopic threat like parasitic worm. The three main worms include *Wuchereria bancrofti*, *Brugia malayi*, and *B. timori*. The symptom of infections are swelling of an arm, leg or genital areas. Suspicion of lymphatic filariasis of course, may be made upon the appearance of the lymphedema.² The worst symptoms of the chronic disease generally appear in adults, and in men more often than in women. In endemic communities, some 10-50% of men suffer from genital damage, especially hydrocele (fluid-filled balloon-like enlargement of the sacs around the testes) and elephantiasis of the penis and scrotum.³ In longstanding cases, the enormously swollen scrotum may bury the penis.⁴ The diagnosis can be confirmed from microscopic examination of smears of blood or

hydrocele fluid. Complement fixation and skin tests are also useful.⁵ Treatment for the parasitic infection include the administration of drugs such as diethylcarbamazine (DEC), albendazole and ivermectin. Various surgical procedures have been developed to remove the edematous tissue in patients with genital elephantiasis. The principles of these operations follow general plastic surgery principles. The penile and scrotal skin and subcutaneous tissues can be excised and reconstructed using a partial-thickness graft from normal skin in the upper part of the body without lymphedema. Unmeshed grafts yield a better cosmetic appearance to the penis, while meshed grafts are preferred for scrotal reconstruction⁶. We are reporting a case of giant scrotum and penis which was managed by excision of the giant scrotum and penile skin, followed by reconstruction with local flaps.

The idea is to highlight the management of giant scrotum which is rare in southern area. Possibly this was the first case in this hospital. General surgeon can manage these patients by applying some basic plastic surgical principles. These encourage us to report this case.

Case report:

A 45 years male from Laksham, Comilla, street beggar by profession, weighing 55 kg, smoker, non-diabetic, was admitted in Comilla Medical College Hospital with the complaints of huge scrotal swelling and penis & bipedal nonpitting edema with tropic ulceration in legs for about 10 years. The swelling was gradually increasing in size & now so big that it is hampering in walking, sitting, and defecation & micturation. He is a known case of Filariasis for which he is taking Diethylcarbamazepine for last four years.

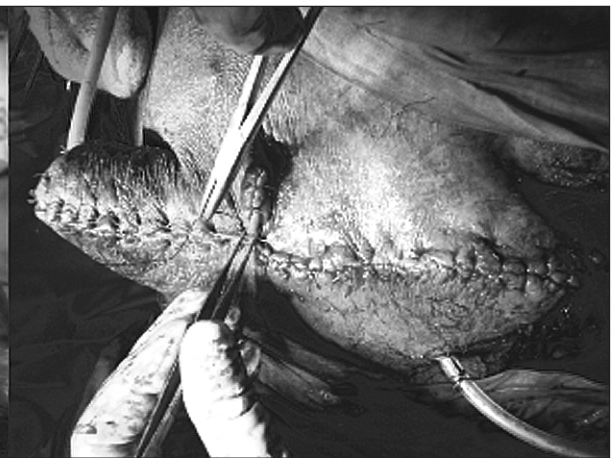
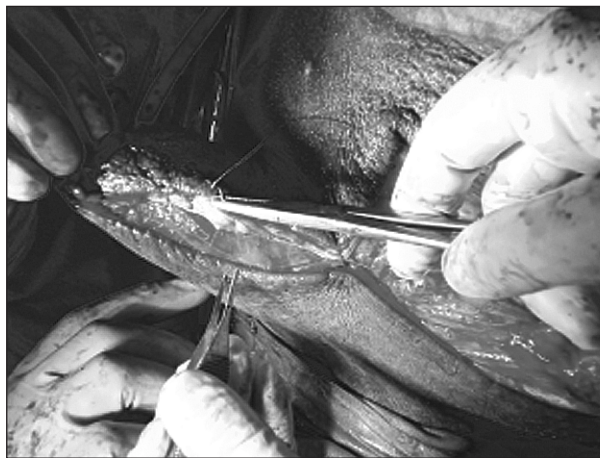
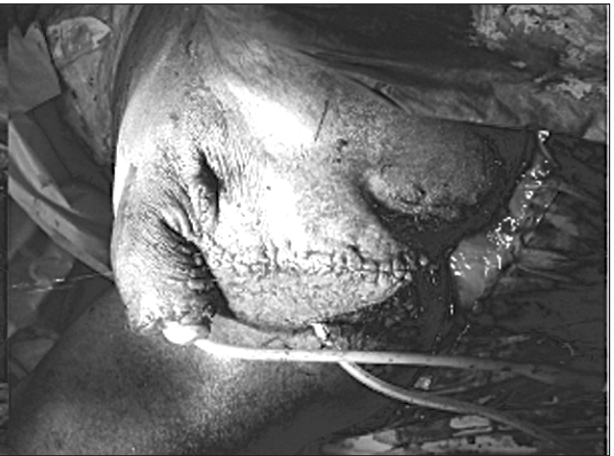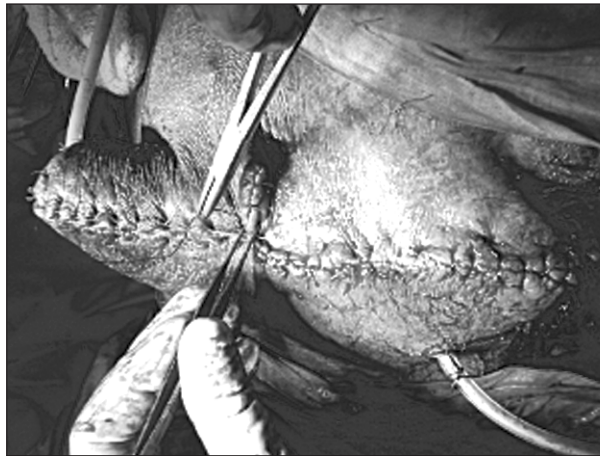
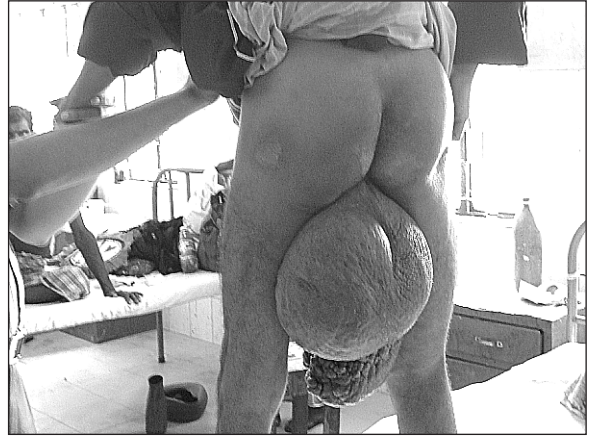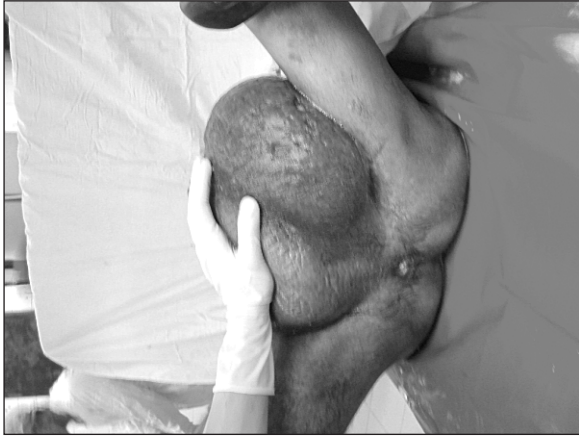- a. Dr. Md. Serajul Hoque, FCPS (Surgery) & MS (Urology), Department of Surgery, Comilla Medical College Hospital, Comilla
- b. Dr. SM Shafiul Azam Chaudhury, FCPS(Surgery), Department of Surgery, Comilla Medical College Hospital, Comilla
- c. Dr. ANM Ilias, MBBS, Department of Surgery, Comilla Medical College Hospital, Comilla
- d. Dr. Farjana Sultana Nur, MBBS. DDV, Department of Surgery, Comilla Medical College Hospital, Comilla

Address of Correspondence: Dr. Md. Serajul Hoque, Associate Professor, Comilla Medical College Hospital, Comilla.

Received: 8 October, 2007

Accepted: 14 July, 2008

Steps of Operation





On examination he is mildly anemic; there was bipedal non-pitting edema & some non healing tropic ulcer over both ankle joints. Local examination, there was huge scrotum and penis, skin of which shows eczematous changes, fissuring with verrucous & papilla were seen. The external urethral orifice was totally covered by tag of skin & very difficult to locate.

Laboratory investigation shows CFT for filarial was strongly positive; microfilaria in the blood was not detected even after provocative test. Histopathology was not done by omission. Under spinal anesthesia, we resected the whole scrotum & penile skin which weighs about 15 kg & scrotal & penile coverage by local whole trunk skin flaps. The patient recovers uneventfully. The postoperative morbidity was the delayed wound healing.

Discussion:

Elephantiasis of the penis and scrotum is the most common clinical problem encountered by urologists in patients with filariasis. Surgical treatment for genital filariasis is indicated in patients with significant cosmetic or functional morbidities. Various surgical procedures have been developed to remove the edematous tissue in patients with genital elephantiasis. The principles of these operations follow general plastic surgery principles. Wound healing is slow and complicated in patients with filariasis because of the lymphedema and chronic scarring. Patients who require excision and grafting of the scrotal or penile skin are at higher risk for graft

failure. Wound infections are also common in these patients.³ In extensive disease, complete excision of all elephantoid tissue, preferably saving the penis, spermatic cord and testes, is appropriate.^{7,8,9} In accordance with the desires of the patient we preserved the spermatic cords and both testes despite the extent of the disease. If available, scrotal flaps are most suitable for reconstruction of the scrotum. Medial thigh flaps can be used in the absence of adjacent scrotal tissue. Mesh skin graft is widely accepted for use in penile skin defects.¹⁰ In this case after complete excision & reconstruction, the patient gained considerable quality in life. The patient now is able to move himself. After a follow-up period of 3 months the patient's erectile function was re-established enabling sexual intercourse. This case shows that surgical therapy can provide good functional and cosmetic results even in massive scrotal & penile elephantiasis. It is the rare case in this zone so at present longer study can not be done.

Conclusion:

Giant Scrotal & penile lymphedema is a rare syndrome. *Wuchereria bancrofti* is the usual organism in Asia. Scrotal lymphedema in the western world is of variable origin. We present one Asian patient with giant scrotal & penile lymphedema and discuss the diagnostical and therapeutical approach. In the case presented here extensive excision of elephantoid tissue saving penis, spermatic cord and testes was performed with adequate cosmetic and functional results.

References:

1. Denzinger S, Watzlawek E, Burger M, Wieland WF and Otto W. Giant scrotal elephantiasis of inflammatory etiology: a case report; *Journal of Medical Case Reports* 2007, 1:23
2. <http://www.lymphedemapeople.com/>
3. <http://w3.whosea.org/lymphatic/>
4. Fowler CG, Testis and Scrotum, Russell RCG, Williams NS, Bulstrode CJK, editor in: *Bailey & Loves Short Practice of Surgery* ; 24th edition; Arnold 2004:1414.
5. Ritchie AWS, The Scrotum, Cuschieri SA, Steele RJC, Moossa AR, editor in: *Essential Surgical Practice, Higher Surgical Training in General Surgery*; 4th edition; vol.2; Arnold; 2002:1312.
6. Galley RE, Sabanegh E, Talavera F, Sant GR, Wolf JS, Leslie SW. Hydrocele, Filarial e-Medicine <http://www.emedicine.com/med/topic2755.htm>
7. Kuepper D. Giant scrotal elephantiasis. *Urology*. 2005; 65:389.
8. Apesos J, Anigian G. Reconstruction of penile and scrotal lymphedema. *Ann Plast Surg*. 1991; 27:570–573.
9. Slama A, Jaidane M, Elleuch A, Ben Sorba N, Yacoubi MT, Mosbah AF. Surgical treatment of penile-scrotal elephantiasis. *Prog Urol*. 2002;12:337–339.
10. Costa-Ferreira A, Martins A, Amarante J, Silva A, Reis J. Giant penoscrotal elephantiasis. *Eur J Plast Surg*. 1999;22:397–399.