

Femoral Hypoplasia-Unusual Facies Syndrome: A Case Report

M HOQUE^a, MM ALI^b, MAH MIA^c, S MALI^d

Summary:

The femoral hypoplasia-unusual facies syndrome (FH-UFS) is a very rare association of femoral and facial abnormalities. We report a 19 days old male baby with bilateral femoral hypoplasia and cranio-facial dysmorphism including low set ears, upslanted palpebral fissures, long philtrum with

thin upper lip, micrognathia, hypoplastic alae nasi, short broad tipped nose, and cleft palate. Tongue tie was also present as an additional feature.

Key words: Femoral hypoplasia-unusual facies syndrome, case report, Rare disease.

(J Bangladesh Coll Phys Surg 2015; 33: 229-231)

Introduction:

The femoral hypoplasia-unusual facies syndrome (FH-UFS) is a very rare association of femoral and facial abnormalities. It encompasses a spectrum of anomalies that include bilateral femoral hypoplasia/ aplasia and cranio-facial dysmorphism with cleft palate^{1,2}. The first case of FH-UFS was reported by Franz and O'Rahilly in 1961, but it was not recognized as a distinct entity until 1975 when Daentl et al reported their cases³. This syndrome is also known as femoral facial syndrome. Etio-pathogenesis of the syndrome remains unknown but some authors reported a link to maternal diabetes mellitus^{4,5}. Most cases have been found sporadic^{4,5}. There have been rare reports (three cases) describing a family with more than one affected member^{6,7}. Here we described a 19 days old male baby with many features of FH-UFS who was admitted into the neonatal unit of Sylhet MAG Osmani Medical College Hospital.

Case Report:

The 19 days old male baby hailing from Sunamgonj was admitted with the complaint of abnormality in

both lower limbs. The mother was 21 year old. The baby was the second child of healthy non-consanguineous parents. The first sibling was a normal full term baby, delivered by vaginal route, now 2 year old. The mother was on regular antenatal check up and had no history of gestational diabetes or any other significant illness during pregnancy. She also had no history of taking any teratogenic drug. The baby had a history of mild perinatal asphyxia after normal vaginal delivery at 36 weeks of gestation. The birth weight of the baby was 1600 gram, length 38 cm, occipito-frontal circumference 31cm and upper segment lower segment ratio was 2.45:1. Clinical findings include craniofacial dysmorphism like low set ears, upslanted palpebral fissures, long philtrum with thin upper lip, micrognathia, hypoplastic alae nasi, short broad tipped nose, (Fig-1) and cleft palate (Fig-2).

- Dr. Mujibul Hoque, Assistant Professor, Department of Paediatrics, Sylhet M.A.G. Osmani Medical College, Sylhet
- Prof. Md. Manajjir Ali, Professor, Department of Paediatrics, Sylhet M.A.G. Osmani Medical College, Sylhet
- Dr. Mohammed Abdul Hai Mia, Assistant Professor, Department of Neonatology, Sylhet M.A.G. Osmani Medical College, Sylhet
- Dr. Syed Mortaza Ali, Sylhet M.A.G. Osmani Medical College, Sylhet

Address of Correspondence: Dr. Mujibul Hoque, Assistant Professor, Department of Paediatrics, Sylhet M.A.G. Osmani Medical College, Sylhet, Mobile no: 01911-132026, E-mail: drmujib@gmail.com

Received: 9 June, 2014

Accepted: 12 August, 2015

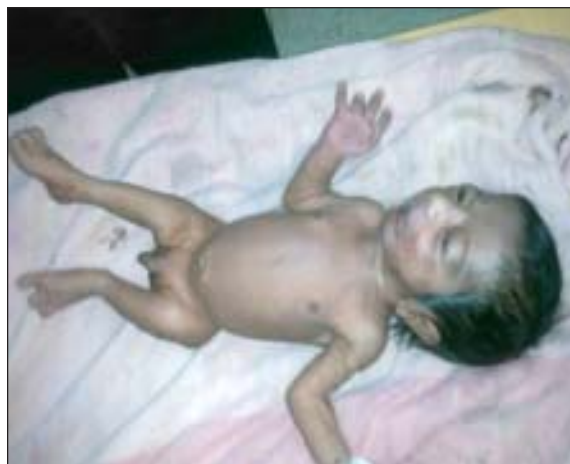

Fig.-1: Craniofacial dysmorphism

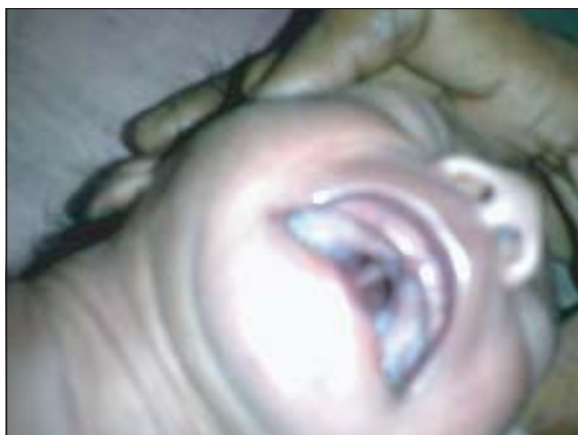


Fig.-2: Cleft palate

Tongue tie was also present. Upper limbs showed flexion deformity of both elbow with skin dimpling. Both thighs looked laterally rotated. Length of the thighs was very short compared to leg length, knee joint being rudimentary. There was spina bifida at the sacral region (Fig-3).

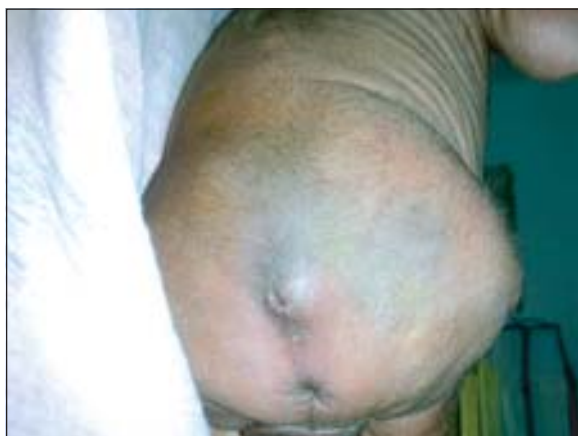

Fig.-3: Spina bifida

There were no clinically detectable cardiac or renal abnormalities.

X-ray of both lower limbs including the hip revealed bilateral femoral hypoplasia with dysplastic pelvis (Fig-4). X-ray of upper limbs showed no bony abnormality. Echocardiography revealed no cardiac anomaly and USG of genito-urinary system was normal. With these above mentioned clinical and radiological findings, the baby was diagnosed as a case of FH-UFS.

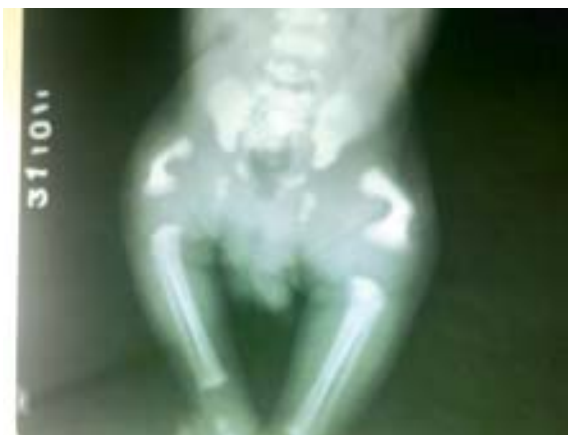

Fig.-4: X-ray showing femoral hypoplasia with dysplastic pelvis.

Discussion:

In 1975, Daentl et al delineate a distinctive pattern of malformation which includes femoral hypoplasia and unusual facies in four unrelated individuals^{2,3}. This disorder consists of hypoplasia or absence of the femurs bilaterally and distinguishing facial characteristics of a short nose with a broad tip, elongated philtrum, thin upper lip, cleft palate and micrognathia²⁻⁴. Many other associated abnormalities have been described which includes short or absent fibulas, clubfeet, shortening of humeri, restricted motion of elbows, constricted ilial base, vertical ischial axis, hypoplastic acetabulae, large obturator foramina, lower spine abnormalities and posterior tapering of the ribs¹⁻⁵. Aside from skeletal anomalies, these infants may have cardiac and genitourinary anomalies⁸. The present case fits into the classical clinical spectrum of FH-UFS. Among the associated anomalies the baby had spina bifida at the sacral region. The baby also had tongue tie which is not reported as a feature of FH-UFS previously.

The exact etiology and pathogenesis of this disorder is unknown. Burn et al¹ described three groups of FH-UFS: (a) cases secondary to fetal constraint or deformation, (b) cases resulting from maternal diabetes and (c) disruption and those of unknown etiology. The possible teratogenic potential of maternal diabetes has been ruled out in this case. There was no history of significant illness or taking any offending drug during pregnancy.

FH-UFS has many overlapping features with caudal regression syndrome which represents a continuum of

malformations ranging from agenesis of the lumbosacral spine to sirenomelia. But cranio-facial anomalies are always absent in caudal regression syndrome⁹. The presences of characteristic facial defects have sharply contrasted this case of FH-UFS from caudal regression syndrome or sirenomelia.

FH-UFS affected infants have normal to above normal intelligence²⁻⁴. Most complications arise from small stature and limited function of the lower limbs³, but most patients are ambulatory⁵. Problems with feeding and speech development may also arise due to facial anomalies^{4,5}. Other complications like recurrent urinary tract infection and incontinence have also been reported⁴. However, in cases without serious complications, the life span is usually normal²⁻⁴.

Before viability the option of pregnancy termination can be offered to the parents. The postnatal management is directed at the orthopedic, facial, cardiac and genitourinary complications.

Conclusion:

Though the prevalence of femoral hypoplasia-unusual facies syndrome is very rare, prenatal diagnosis is very important to offer the parents for termination of pregnancy. Early diagnosis at the neonatal period is necessary for orthopedic intervention and also for correction of other complications.

References:

1. Burn J, Winter RM, Baraitser M, Hall CM, Fixsen J. The femoral hypoplasia- unusual facies syndrome. *J Med Genet* 1984; 21(5): 331-40.
2. Chen H. *Atlas of Genetic Diagnosis and Counseling*. 1st ed. New Jersey: Humana Press; 2006.
3. Daentl DL, Smith DW, Scott CI, Hall BD, Gooding CA. Femoral hypoplasia-unusual facies syndrome. *J Pediatr* 1975; 86: 107-11.
4. Jones KL, Jones MC, del Campo M, editors. *Smith's Recognizable Patterns of Human Malformation*. 7th ed. Philadelphia: Saunders; 2013.
5. Say B. Femoral Hypoplasia-Unusual Facies Syndrome. In: Buyse ML, editor. *Birth Defect Encyclopedia*. Dover, MA: Blackwell Scientific Publication; 1990: 681-88.
6. Lampert RP. Dominant inheritance of femoral hypoplasia-unusual facies syndrome. *Clin Genet* 1980; 17: 255-8.
7. Lord J, Beighton P. The femoral hypoplasia-unusual facies syndrome: a genetic entity? *Clin Genet* 1981; 20: 267-75.
8. Nowaczyk MJ, Huggins MJ, Fleming A, Mohide PT. Femoral-facial syndrome: prenatal diagnosis and clinical features. Report of three cases. *Am J Med Genet* 2010; 152: 2029-33.
9. Riedel F, Froster-Iskenius U. Caudal dysplasia and femoral hypoplasia-unusual facies syndrome: different manifestations of the same disorders? *Eur J Pediatr* 1985; 144 (1): 80-2.