

Endometriosis at Cesarean Section Scar

QE FORHAD^a, K NAHAR^b, HA BABY^c

Summary:

Endometriosis may be defined as presence of functioning endometrium (glands and stroma) in sites other than uterine mucosa. The prevalence of endometriosis is about 10%. According to Nominato, cesarean section remains the most common surgical procedure related to the development of abdominal wall scar endometriosis¹. But endometriosis sometimes presented to general surgeons as a lump in the

abdomen. It can pose a diagnostic dilemma and should be in the differential diagnosis of lumps in the abdomen in females. Diagnosis is usually made following histological examination. This is a case report of abdominal wall endometriosis following cesarean section. This report discusses and evaluates the incidence, course, diagnosis, treatment and prevention of this condition.

(J Bangladesh Coll Phys Surg 2017; 35: 147-149)

Introduction:

Endometriosis was first described by Rokitansky in 1860 and was defined as the presence and proliferation of the endometrium outside the uterine cavity, commonest site being the pelvis. The actual incidence of abdominal wall endometriosis is unknown but one series reported that only 6% of cases were related to scars. In another series, the prevalence of surgically proven endometriosis in scars was 1.6%². The most common site is at a cesarean section scar. But there are case reports of involvement of the rectus abdominis muscle in a virgin abdomen³.

Endometriosis, in patients with scars, is more common in the abdominal skin and subcutaneous tissue compared to muscle and fascia. Endometriosis involving only the rectus muscle and sheath is very rare⁴. The simultaneous occurrence of pelvic endometriosis with scar endometriosis has been found to be infrequent. Scar endometriosis is rare and difficult to diagnose, often confused with other surgical conditions.

Case Report:

A 32 years old female patient presented with a painful lump on the lateral aspect of a pfannensteil incision 2 years after a cesarean section (Fig 1). The lump was

associated with pain and no history of any discharge. The pain was stabbing in nature and was increased during menstruation. Pain was not associated with fever, vomiting or any other associated symptoms. Abdominal examination revealed a lump about 3×3 cm, firm, tender and bluish in color. Ultrasound of the abdomen was performed and revealed a bright heteroechoic mass about 3×3 cm at lateral aspect of the abdominal wall scar. This was initially thought to be a stitch granuloma.

It was initially conservatively treated by oral contraceptive pill and pain killer like NSAID; however, the abdominal lump (Fig 2, 3) persisted and gradually enlarged in size. The patient was posted for a wide local excision of the abdominal wall lump. The lump was 3×3 cm, firm at the external oblique aponeurosis and extending to the abdominal wall muscle, wide excision with clear margins were performed. Post operative period was uneventful. Histopathology showed fibro adipose tissues with interspersed glands and stroma of endometriosis which confirmed the diagnosis of endometriosis of abdominal wall scar.

- Dr. Quorrata Eynul Forhad, Associate prof. Gynae and Obs., Shahabuddin Medical College Hospital.
- Dr. Kamrun Nahar, Assistant Prof. Gynae and Obs., Shahabuddin Medical College Hospital.
- Prof. Hosne Ara Baby, Prof & Head of dept. Gynae and Obs— Shahabuddin Medical college Hospital

Address of Correspondence: Dr. Quorrata Eynul Forhad, Associate prof. Gynae and Obs., Shahabuddin Medical College Hospital.

Received: 30 Nov. 2015

Accepted: 12 June 2017

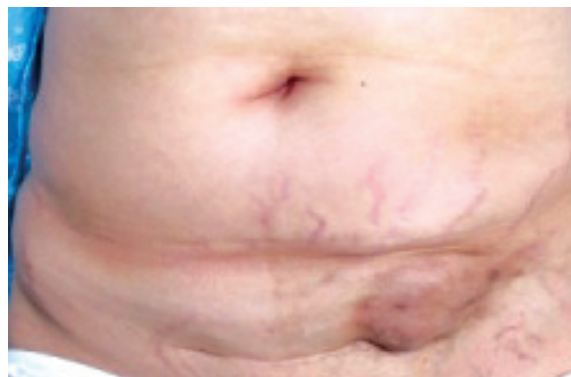

Fig.-1: Pre operative image of scar endometriosis

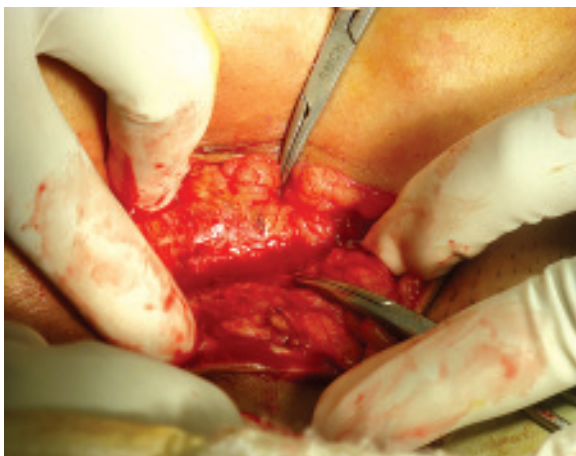

Fig.-2: *Per operative image of scar endometriosis*

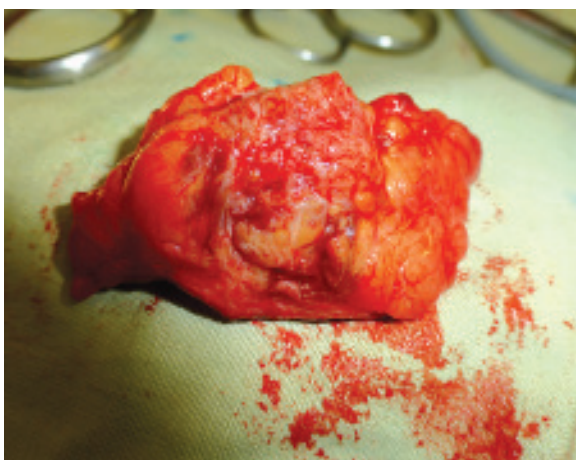


Fig.-3: *Per operative image of scar endometriosis*

Discussion:

Endometriosis is the presence of functioning endometrial tissue outside the uterine cavity, whereas endometrioma is a well-circumscribed mass. The various sites of extra pelvic endometriosis are bladder, kidney, bowel, omentum, lymph, nodes, lungs, pleura, extremities, umbilicus, hernial sacs, and abdominal wall⁵. Endometriosis involving the abdominal wall is an unusual phenomenon which should be considered in the differential diagnosis of abdominal wall masses in women. The usual clinic presentation is a painful nodule in a parous woman with a history of gynecological or obstetrical surgery. The intensity of pain and size of nodule vary with menstrual cycle.

The development of intrapelvic endometriosis may involve retrograde menstruation, maturation of extrauterine primordial cell remnants of embryogenesis and hematologic or lymphatic spread of endometrial cells. Extrapelvic endometriosis in the lung, skin and extremities not associated with surgical violation of the uterus is believed to be the result of hematogenous or lymphatic spread of endometrial tissue⁶.

Scar endometriomas are believed to be the result of direct inoculation of the abdominal fascia or subcutaneous tissue with endometrial cells during surgical intervention and subsequently stimulated by estrogen to produce endometriomas. This theory is convincingly demonstrated by experiments in which normal menstrual effluent transplanted to the abdominal wall resulted in subcutaneous endometriosis. In clinical practice, its occurrence has been well documented in incisions of any type where there has been possible contact with endometrial tissue, including episiotomy, hysterotomy, ectopic pregnancy, laparoscopy, tubal ligation, and cesarean section⁷. Time interval between operation and presentation has found to vary from 3 months to 10 years in different series⁵. In a study by Celik et al. a case was reported with a two year time interval³.

Diagnosis

Scar endometriosis is rare and difficult to diagnose. It is often misdiagnosed as stitch granuloma, inguinal hernia, lipoma, abscess, cyst, incisional hernia, desmoid tumor, sarcoma, lymphoma, or primary and metastatic cancer. Diagnosis is confirmed only by histopathology (Fig4)

A high index of suspicion is recommended when a woman is presented with a post operative abdominal lump. Good surgical and gynecological histories, as well as a thorough examination with appropriate imaging techniques (ultrasound, CT and MRI) usually lead to the correct diagnosis. With regard to imaging, ultrasound is the most accessible, reliable, and cost-effective imaging technique for the diagnosis of cesarean scar endometriosis (CSE) according to Hensen⁸. CT usually shows a solid, well-circumscribed mass whereas MRI may be more helpful when the lesion is small because of its high spatial resolution, furthermore it is better than CT scan in detecting the planes between muscles and abdominal subcutaneous tissue.

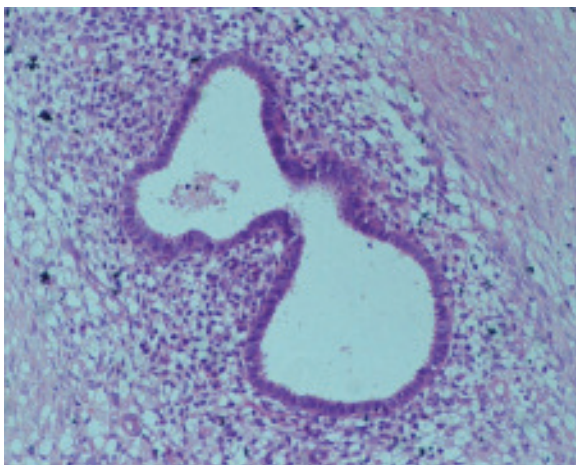


Fig-4 : Histopathology section of scar endometriosis

Management

Therapeutic management is essentially based on large surgical excision, with clear margins and reconstruction of damaged tissue. Medical treatment involving hormone suppression has been suggested to relieve clinical symptoms⁹. Most authors agreed that surgery is effective in preventing recurrence, as well as conversion to malignancy, which although quite rare—has been described in a few sporadic cases¹⁰. Medical treatment with the use of progestogens, oral contraceptive pills, and danazol is not effective and gives only partial relief in symptoms and does not ablate the lesion. Moreover due to side effects such as amenorrhea, weight gain, hirsutism, and acne, compliance is unlikely. Recently, there have been reports of the use of the gonadotrophin agonist (Leuprolide acetate), but it has been found to provide only prompt improvement in symptoms with no change in the lesion size¹¹.

Malignant Risk

Malignant change of endometriosis in a cesarean scar is rare¹². Long-standing recurrent scar endometriosis could undergo malignant changes and clinicians should be aware. Only 21.3 % of cases of malignant transformation of endometriosis occur at extragonadal pelvic sites and 4% of cases in scars after laparotomy.

Follow Up and Prevention

Follow up of endometriosis patients is important because of the chances of recurrence, which may require re-excision. So wide excision of the lump with clear margins should be done for prevention of further

recurrence. In cases of continual recurrence, possibility of malignancy should be ruled out. Hence, good technique and proper care during cesarean section may help in preventing scar endometriosis.

Conclusion:

We conclude that abdominal wall endometriosis, although a rare entity, can lead to significant morbidity and many diagnostic pitfalls. Like any other chronic disease, long-term misdiagnosis can lead to significant impairment of the quality of life, not only social and professional part, but psychosexual as well. Hence, one should consider it in all cases with unexplained pain, especially after previous cesarean delivery or history of endometriosis surgery.

Reference:

1. N. S. Nominato, L. F. V. S. Prates, I. Lauer, J. Morais, L. Maia, and S. Geber, "Caesarean section greatly increases risk of scar endometriosis," *European Journal of Obstetrics Gynecology and Reproductive Biology*, 2010;152(1):83–85.
2. Kantor WJ, Roberge RJ, Scorza L. Rectus abdominis endometrioma. *Am J Emerg Med* 1999; 17: 675-677.
3. Hashim H, Shami S: Abdominal Wall Endometriosis in General Surgery. *The Internet Journal of Surgery*. 2002;3.
4. Celik M, Bülbüloğlu E, Büyükbese MA, Cetinkaya A. Abdominal Wall Endometrioma: Localizing in Rectus Abdominal Sheath. *Turk J Med Sci*. 2004; 34: 341-343
5. Carpenter SE, Markham SM, Rock JA. Extra pelvic endometriosis. *Obstet Gynecol Clin North Am* 1989;16:193-219.
6. Brenner C, Wohlgemuth S. Scar endometriosis. *Surg Gynecol Obstet* 1990; 170: 538- 540.
7. Bumpers HL, Butler KL, Best IM. Endometrioma of the abdominal wall. *Am J Obstet Gynecol* 2002;187:1709-1710.
8. J.-H. J. Hensen, A. C. Van Breda Vriesman, and J. B. C. M. Puylaert, "Abdominal wall endometriosis: clinical presentation and imaging features with emphasis on sonography," *American Journal of Roentgenology*, 186(3):616–620.
9. E. M. Oh, W. Lee, J. M. Kang, S. T. Choi, K. K. Kim, and W. K. Lee, "A surgeon's perspective of abdominal wall endometriosis at a caesarean section incision: nine cases in a single institution," *Surgery Research and Practice*, 2014, 765372, 4 pages, 2014.
10. S. C. Shalin, A. L. Haws, D. G. Carter, and N. Zarrin-Khameh, "Clear cell adenocarcinoma arising from endometriosis in abdominal wall cesarean section scar: a case report and review of the literature," *Journal of Cutaneous Pathology*, 2012; 39(11):1035–1041.
11. Rivlin ME, Das SK, Patel RB, Meeks GR. Leuprolide acetate in the management of cesarean scar endometriosis. *Obstet Gynecol* 1995; 85: 838-839.
12. Sergent F, Baron M, Le Cornec JB, Scotte M, Mace P, Marpeau L. Malignant transformation of abdominal wall endometriosis: a new case report. *J Gynecol Obstet Biol Reprod (Paris)*. 2006;35:186-190.