

Dandy–Walker Malformation with Patent Ductus Arteriosus—A Case Report

MUH BEGUM^a; MA RAHMAN^b

Summary:

Dandy–Walker malformation (DWM) is a group of congenital human brain malformation with specific characteristics. It may be associated with a number of other organ malformation including heart, eye, and thyroid glands. In our case, DWM was associated with heart malformation in the form of patent ductus arteriosus (PDA)

and was complicated by atrial fibrillation. The case was established by computed tomography of brain, echocardiography and electrocardiography. The patient was asymptomatic until 7 years of age.

(J Bangladesh Coll Phys Surg 2018; 36: 128-131)

DOI: <http://dx.doi.org/10.3329/jbcps.v36i2.36082>

Introduction:

Dandy–Walker malformation (DWM) is a rare group of congenital human brain malformation.¹ It is the most common posterior fossa malformation and characterized by the triad of: hypoplasia of cerebellar vermis and cephalad rotation of the vermian remnant; cystic dilation of the fourth ventricle extending posteriorly; enlarged posterior fossa with torcula-lamboid inversion.²

The association of hydrocephalus, hypoplasia of the cerebellar vermis, and posterior fossa cyst was first described by Sutton in 1887 and the triad was later confirmed by Dandy and Blackfan in 1914 followed by Tagart and Walker in 1942. Benda finally introduced the eponym ‘Dandy walker syndrome’ in 1954.³

Infants with DWM may present with early signs such as vomiting, sleepiness, irritability, convulsions, unsteadiness and lack of muscle co-ordination.⁴

The clinical manifestations of DWM include psychomotor and growth retardation, hypotonia, strabismus, myopia, a short neck, microcephaly, brachycephaly, hypertelorism, antimongoloid slant of palpebral fissures, globulus large nose, large mouth with down turned corners, poorly lobulated ears, high

arched palate, cleft palate, small hands and feet, clinodactily, and the brachymesophalangy of the little fingers;⁵ later on spasticity, poor co-ordination and ataxia; mental retardation occurs in fewer than half, most often in those with severe hydrocephalus, chromosome abnormalities or other birth defects. The age at diagnosis varies depending on the onset and severity of hydrocephalus and presence of other birth defects.⁶ Literature suggests that 40% individuals with DWM were normal intellectuals while 40% had mental retardation and 20% were borderline.⁷

It is said that clinical examination cannot replace any modalities of investigation. In DWM, there are many signs or symptoms, none of these are characteristic to diagnose individual as DWM and diagnosis is solely based on imaging techniques, usually computed tomography (CT scan) or magnetic resonance imaging (MRI) of brain. The present manuscript reports a case encountered in Rangpur Community Medical College Hospital which was revealed as Dandy–Walker malformation with patent ductus arteriosus by CT scan of brain and echocardiography.

Dandy–Walker Malformation is generally treated surgically, although medical management may be required for symptoms, such as seizure or vomiting. The ventriculoperitoneal (VP) shunt surgery is often performed in cases complicated by hydrocephalus or combined VP and cystoperitoneal (CP) shunts may be needed.⁸

Case Report:

An 11 years old boy was presented with a history of generalized convulsion on two occasions during preceding one month. He also gave history of generalized weakness and palpitation since 7 years of age, for which he took some drugs advised by local

a. Dr. Most. Umme Habiba Begum, Associate Prof of Paediatrics, Rangpur Community Medical, College, Rangpur.

b. Dr. Lt. Col Md Anisur Rahman, Classified Medicine Specialist, Combined Military, Hospital (CMH) Dhaka, Cantonment, Dhaka.

Address of Correspondence: Dr. Most. Umme Habiba Begum, Associate Prof of Paediatrics, Rangpur Community Medical, College, Rangpur. Mobile: 01521-248085, 01712-546647, email: arafanis@gmail.com, uhabibar27@gmail.com

Received: 23 Sept. 2017

Accepted: 13 March 2018

doctors but parents could not mention name of medicines. His antenatal and post natal periods were uneventful and mile stones of development were age appropriate. He was vaccinated as per EPI schedule. He read in class four and academic performance was average. He had no history of such illness in his family. There was no maternal history suggesting Rubella infection during pregnancy. Clinically he was ill-looking, body weight 32 Kg, pulse 88 beats/min irregularly irregular, respiration 28/min, blood pressure 130/60 mmHg, visible impulses in apical area with continuous machinery murmur in precordium that clinically consistent with patent ductus arteriosus (PDA). He had prominent occiput with occipitofrontal circumference measuring 53 cm; Investigation was done and, CT scan of brain showed a fairly large cystic structure in the posterior fossa which communicates with the 4th ventricle with hypoplastic cerebellum and vermis; both the lateral ventricles were widely apart, their occipital horns were moderately dilated and having ‘Tear drop’ appearance, suggesting agenesis of corpus callosum- finding consistent with Dandy-Walker malformation. Electroencephalogram (EEG) report was normal. Electrocardiogram (ECG) showed

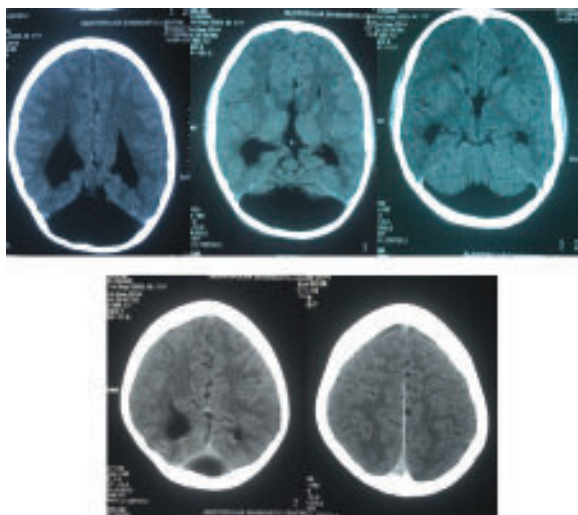


Fig.-1: Dandy-Walker malformation, showing fairly large cystic structure in the posterior fossa which communicates with the 4th ventricle with hypoplastic cerebellum and vermis; both the lateral ventricles are widely apart, their occipital horns are moderately dilated and having ‘Tear drop’ appearance, suggesting agenesis of corpus callosum.

atrial fibrillation with Left ventricular hypertrophy (LVH) and chest X-ray was normal; Echocardiography showed patent ductus arteriosus (PDA) with left to right shunt with dilated left ventricle with good left and right ventricular systolic function. He was diagnosed as Dandy-Walker Malformation (DWM) with patent ductus arteriosus (PDA) with atrial fibrillation (AF). He was consulted with paediatric cardiologist and paediatric neurosurgeon. He was treated by operative surgery-multiple ligation and transfixation of PDA to aortic and pulmonary end along with antiepileptic drug.

Discussion:

Dandy –Walker Malformation is a sporadic disorder with the estimated prevalence rate is about 1 in 30,000 live births, and accounts for approximately 7.5% cases of infantile hydrocephalus.⁹ It is more common in females than males. The pathogenesis of DWM is poorly understood and is likely to be heterogeneous. Heterozygous loss of Zinc finger genes and mutations affecting FOXC1 and FGF17 genes may be responsible for DWM. Mutations in NID1 and LAMC1 genes may be also related.¹⁰ Associated environmental factors include first-trimester exposure to rubella, cytomegalovirus, toxoplasmosis, or warfarin. Maternal diabetes during pregnancy is also associated with increased risk of DWM.¹¹ In our case we could not identified any causal association.

Dandy –Walker Malformation has its ‘classic’ or ‘variant presentation’ or presented as ‘Dandy Walker complex’. A classic DWM is associated with cystic dilatation of the fourth ventricle, complete or partial agenesis of cerebellar vermis and enlarged posterior fossa and patients usually manifest in the first year of life with symptoms of hydrocephalus and associated neurological symptoms. Macrocephaly is the most common manifestation and in 80% of cases the diagnosis is made by the first year of life.¹² Our case was symptomatic since 7 years of age most likely due to cardiac abnormality (PDA) and neurological symptoms (headache and convulsion) developed at 11 years of age. There are few case reports of DWM where patients were asymptomatic until death (died due to breast cancer at 52 years of age) or upto the age of 59 years when patient presented with headache and computed tomography and MRI of those patients

revealed DWM¹³. Dandy–Walker variant comprises cystic posterior mass with variable hypoplasia of the cerebellar vermis like our case and no enlargement of the posterior fossa. However, the third variant megacisterna magna comprises enlarged cistern magna with normal cerebellar vermis and fourth ventricle.¹⁴

The Dandy –Walker Malformation is frequently associated with other central nervous system abnormalities including dysgenesis of corpus callosum like our case, ectopic brain tissue, holoprosencephaly, and neural tube defects.¹⁵ Other associated extra cranial birth defects in DWM includes cardiac defects- patent ductus arteriosus (PDA) like our case; atrial septal defects(ASD), tetralogy of fallot (TOP), and eye or thyroid dysfunctions.¹⁶ The presence of multiple congenital defects associated with DWM may shorten life span.¹⁷

There are some well defined syndromes associated with DWM which include “PHACE syndrome” (posterior fossa brain malformations, haemangiomas, arterial anomalies, coarctation of aorta and cardiac defects and eye abnormalities.¹⁸ and Ehlers Danlos syndrome (loose joints, stretchy skin, and abnormal scar formation), Coffin Siris syndrome (developmental delays, absent fifth finger and toe nails).¹⁹ Recognized chromosomal abnormalities in association with DWM includes trisomy 18, 13, 21 or 9 and triploidy. A large number of associated problems may also be present, such as hydrocephalus, atresia of the foramen of Magendie and atresia of the foramen of Luschka, syringomyelia, spina bifida, and microcephaly.

Some individuals with malformations characteristic of DWM have no symptoms and the diagnosis may be made incidentally because of neuroimaging done for another reason.²⁰ Introduction of modern imaging techniques (MRI, CT scan, or ultrasound) has radically changed the evaluation of symptoms related to posterior fossa. MRI is usually performed for detailed evaluation of DWM lesions and complications after the diagnosis is suspected using computed tomography and ultrasound.

Prenatal diagnosis of DWM is still a challenge. Technical developments in imaging, such as three dimensional sonography and magnetic resonance, allow higher resolution and multiplanar images for an easier diagnosis. Antenatal sonographic features

that would suggest the diagnosis include the combination of:²¹ marked enlargement of the cistern magna (e”10 mm), complete aplasia of the vermis, and a trapezoid-shaped gap between the cerebellar hemispheres. Antenatal ultrasound may falsely over diagnose the condition if scanned before 18 weeks of gestation due to the vermis not being properly formed before that.

With our best knowledge, there is very few case reports of DWM published in Bangladesh, but probably this is the first published case report of DWM with patent ductus arteriosus (PDA) with atrial fibrillation (AF) in our country. High index of suspicion, through clinical examination and appropriate imaging of brain and other suspected organ including antenatal screening can help early diagnosis of DWM and associated other organ malformation.

References:

1. National Institute of Neurological Disorders and Stroke (NINDS) Dandy-Walker Syndrome information page; September 16, 2008, retrieved June 26, 2016.
2. Mark Thurston, Frank Gaillard. Dandy Walker malformations. <https://radiopaedia.org>; 27 Aug 2015.
3. Eugen J Boltshauser, Peter G Barth. Dandy–Walker syndrome. Medlink. 1998; updated November 2016.
4. Simpkins CJ. Ventriculoperitoneal shunt infections in patients with hydrocephalus. *Pediatr Nurs*.2005; 31:457–62.
5. Baburao V, Kerketta L, Seema K, Ghosh K. Dandy Walker malformations in the case of Partial Trisomy 9p due to maternal translocation (9;12) (p12.1; p13.3) *Indian J Hum Genet*. 2007; 13:33–5.
6. William B. Dobyns. Dandy –Walker Malformation. National Organization for Rare Disorders (NORD); <https://rarediseases/dandy-walker-malformation>. August 2017.
7. Cardoso J, Lange MC, Lorenzoni PJ, ScolaRH, Werneck LC. Dandy –Walker syndrome in adult mimicking myasthenia gravis. *Arq Neuropsiquiatre* 2007; 65(1):173-5.
8. Bindal AK, StorrsBB, MacLone DG. Management of the Dandy –Walker syndrome. *Pediatr Neurosurg* 1990-1991; 16(3):163-9.
9. Luijckx T, Gaillard F. Dandy walker continuum. *Radiopaedia Blog RSS*; 2008. Accessed 5 Nov 2014.
10. Eugen J Boltshauser, Peter G Barth. Dandy–Walker syndrome. Medlink. 1998; updated Nov 2016.
11. Harmandeep S Jabbal, Dharendra Dwagh. Dandy –Walker Malformation: management at a tertiary care hospital. *Int journal of recent surgical and medical sciences*, 2017;3(1)20-24.
12. Boseman T, Orman G, Boltshauser. Congenital abnormalities of the posterior fossa. *Radiographics* 2015; 35(10): 200-20.

13. Li Jianru, Hu Qiang, Yan Feng, Shrestha, Sudeep, Chen Gao: An asymptomatic Dandy – Walker Malformation- a case report and literature review; *Neurosurgery Quarterly* 2016; 26(1); 87-89(3).
14. Alam A, Chander BN, Bhatia M. Dandy walker variant: Prenatal diagnosis by ultrasonography. *Med J Armed Forces India.* 2004;60:287–9.
15. Correa GG, Amarat LF, Velodin LM. Neuroimaging of Dandy – Walker Malformation: new concepts. *Top Magn Reson imaging* 2011;22(6):303-12.
16. Ozdemir O, Polat A, Cinbis M, Kurt F, Kucuktasci K, Kiroglu Y. Dandy –Walker’s variant and Teratology of Fallot with atrial septal defect and patent ductus arteriosus and primary hypothyroidism- a new association. *Indian j of paediatr* Apr 2009;76(4):433-5.
17. National Institute of Neurological Disorders and Stroke(NINDS) Dandy-Walker Syndrome information page; Feb 2005 available from :[http:// www.ninds.gov/disorders/dandywalker](http://www.ninds.gov/disorders/dandywalker).
18. Lin MC, Chen CH, Chi CS. PHACE syndrome: Report of one case. *Acta Paediatr Taiwan.* 2003;44:379–82.
19. Imai T, Hattori H, Miyazaki M, Higuchi Y, Adachi S, Nikahata T. Dandy–Walker variants in Coffin Siris syndrome. *AmJ Med Genet* 2001; 100: 152-5.
20. Belquih H, Elmostarchid B. Asymptomatic Dandy–Walker syndrome in adult. *Pan AFR Med J* 2014; 19:15;published online 2014 Sep 8.
21. Phillips JJ, Mahony BS, Siebert JR Lalani T, Fligner CL, Kapur RP. Dandy–Walker complex: correlation between ultrasonographic diagnosis and postmortem neuropathology. *Obstet Gynecol.* 2006;107(3): 685-93.