

Skin Erosion and Exteriorisation of a Cardiac Implantable Electronic Device: Modified Surgical Approach

MF SAZZAD^a, FB IBRAHIM^b, MSR KHAN^c

Summary:

Skin erosion and exteriorization of the commonest cardiac implantable electronic device (CIED) is usually caused by localized infection as a result of “pocket” infection. But, there are other recognized factors including an advanced age with thin, fragile skin with precarious subcutaneous fat. So, exteriorisation of a generator, and/or a lead, is not always associated with bacterial contamination followed by antibiotic therapy and contra-lateral re-implantation strategy. Hence, it does not always make the removal of the material an obligation. Our notable findings in a rare case of such

exteriorization stimulate us to look for and implement a modified surgical technique. This 93-year-old extremely aged wonderfully co-operative, multi-morbid woman had multiple episodes of skin erosion and fixation, re-fixation surgery till the best result achieved. We present a new technique for cardiac pacing allowing for full patient recovery via an alternative surgical way of CIED relocation.

Key Words: Cardiac implantable electronic device, Permanent Pacemaker, Exteriorization

(*J Bangladesh Coll Phys Surg 2020; 38: 155-157*)
DOI: <https://doi.org/10.3329/jbcps.v38i3.47064>

Introduction:

Prevalence of CIED exteriorization of cardiac pacemakers is about 2.6%¹. Skin erosion is the earliest sign detected before exteriorisation. This early complication is also rare and incidence is estimated to be 1%². There are several patient and procedure-related factors that have been reported to increase the risk of permanent pacemaker (PPM) exteriorization.

The commonest cause of such complication is localized infection at the pacemaker implantation pocket. Other factors make the scenario worse are fragile skin with loss of subcutaneous fat in elderly patient, mismatched pocket size to the generator, patients on steroids therapy, uncontrolled diabetes, precarious subcutaneous fat and use of abrasive disinfectants³.

The usual mode of treatment for this group of patients is a staged concept with intermediate temporary pacing with complete and specific antibiotic treatment under strict aseptic technique. The next stage is usually to remove the device and relocate it to the contralateral site. However, conventional temporary pacing is associated with significant complications as lead dislocation, infection and right ventricular perforation⁴⁻⁶. Noticeably, there are no consensus about the treatment options for non-infected CIED exteriorisation and are less reported.

Case Report:

A 93-year-old female patient was admitted for skin erosion and PPM exteriorization to our facility. She was underweight, short statured and cachectic with multiple co-morbidities. She had a PPM implanted two years ago for a symptomatic bradyarrhythmia including sinus node dysfunction. She was also suffering from diabetes, hypertension and bronchial asthma; later was treated regularly with β_2 -mimetic bronchodilators and steroid aerosols. Her Transthoracic echocardiography revealed no vegetation and all other haematological and biochemical parameters were normal. Culture swab from the pacemaker pocket was negative. She was on prophylactic antibiotics for 3 days and a repeated blood cultures and local tissue cultures were sterile. She was managed with a reposition of the PPM in the same pocket with a GORE-TEX® soft tissue patch covering under local anesthesia.

- Md. Faizus Sazzad, Research Fellow & Cardiac Surgeon, Department of Surgery (CTVS), Yong Loo Lin School of Medicine, National University of Singapore, Singapore.
- Farzana B Ibrahim, Assistant Professor, Department of Plastic & Reconstructive Surgery, BIRDEM General Hospital, Dhaka
- Md. Saidur Rahman Khan, Professor & Senior Consultant, Department of Cardiology, Ibrahim Cardiac Hospital & Research Institute, Dhaka

Address of Correspondence: Md. Faizus Sazzad, Research Fellow/Cardiac Surgeon, Department of Surgery (CTVS), Yong Loo Lin School of Medicine, National University of Singapore, MD-6 Building, Level-08 #South, 14, Medical Drive, Singapore 117599, (Off) +65-66011434, (Fax) +65-6775 8538, Email: mfsazzad@gmail.com

Received: 18 June, 2019

Accepted: 1 March, 2020

Six months later she came back to surgical outpatient department with the repeat aforementioned problem. She was admitted under the plastic surgery department with a view to deeper re-positioning of the PPM generator. Extensive infective workout was done and her cultures were all sterile and haematological and biochemical parameters were normal. It is worth mentionable that the family had economic constraints for a leadless pacemaker and she was vulnerable candidate for a staged temporary pacemaker. An elective reposition of the PPM generator was done and it was positioned under the pectoralis major muscle flap of the ipsilateral side. She recovered well from the short general anesthesia and discharged home. Very unluckily, she came back to the surgical outpatient clinic again four months later with PPM generator with leads exteriorization though medially which was a different site from the previous episodes (Figure-1). In view of increase complexity of cardiac intervention, a “Heart Team” approach decided to go for a further surgical relocation in the ipsilateral side.

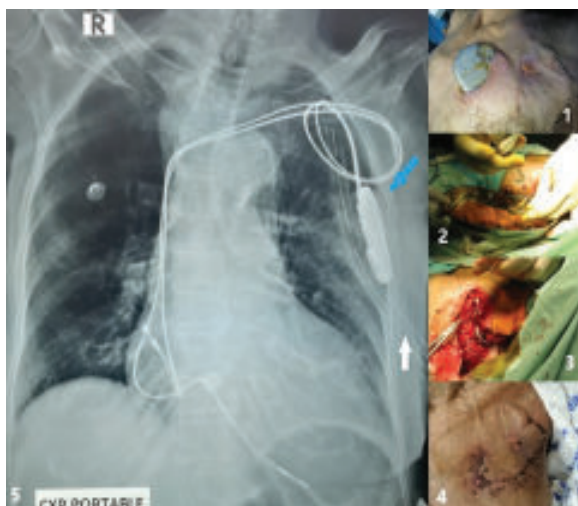


Fig.-1: Figure panel showing 1- Skin erosion and exteriorization of the CIED generator and leads. 2- Cleansing of the pacing generator, leads and surrounding area. 3- Generator and leads pushed inside the pleural space and suture used to fix the generator to the left 3rd rib. 4- Two weeks follow up scar after all stitch removal. 5- Immediate postoperative portable X-ray Chest showing pacing generator inside the chest wall (blue arrow) and a chest drain (white arrow) in situ.

Surgical Technique:

After a thorough asepsis workout (reported sterile as well) and with a high risk-bond the involved area was dissected extensively. All the involved area was resected to make the whole PPM generator and lead free. The area and the materials were washed with hydrogen peroxide and gentamycin solution (Figure-2). A small thoracotomy created in the left 3rd interspace approximately to the size of CIED. The generator was pushed inside the pleural space and fixed with the 3rd rib with a non-absorbable suture (Figure-3). Thoracotomy closed in layers and a 32Fr chest drain was kept in situ. The most part of the lead wire also coiled inside the pleural space and remaining part buried under the pectoralis muscle. Myocutaneous tissue closed in layers. No complaints noted during hospital stay. All stiches were removed on 14th postoperative day (Figure-4). Postoperative X-ray chest showed CIED placed and fixed inside the pleural space (Figure-5) and at six week follow up the cardiologist found a normal functioning CIED.

Discussion:

Skin erosion in elderly patient due to cachexia is a rare complication and reported to be about 1% of cases of CIED exteriorization.² Apart from the infective aetiology this rare complication is difficult to handle with. Our case was a multi-morbid lady with such rare characterization. The association of infection with this complication in our case although sought but could not be established. All cultures, including blood and tissue culture during her hospital admission did not show any growth of organism. Which may be due to prophylactic antibiotic therapy during her year long treatment phase or the resultant scenario due to mechanical effect of the generator aggravated but repeated abrasions (finger nail scratches).

Most commonly the staged approach of treatment protocol is usually followed in such cases. Ardawan and colleagues from Leipzig, Germany described the staged approach.⁷ But putting a temporary pacemaker in this old frail lady was not a valid option to the “Heart Team” discussion in view of impending invitation for further complication. A suitable alternative was a leadless pacemaker. Micra transcatheter Pacing system (Medtronic) and the Nanostim Leadless Cardiac Pacemaker (St. Jude Medical) both are delivered via

femoral venous access through a catheter delivery system, they differ with respect to size, fixation to the myocardium, and responsiveness.⁸ As this device was expensive family declined the choice due to financial constraints.

A different translocation of PPM generator has been tried and reported i.e. placing it in contralateral site⁹ or abdomen and iliac area.¹⁰ In our view, creating another wound in elderly does not potentially decrease the chance of similar repeated incidence. Hence, our cardiothoracic team decided for a simpler technique and opted to make a thoracotomy and place the non-infected generator and leads in the pleural space, which has never been reported in the literature. A successful outcome was achieved with this modified surgical technique. Few considerations to note: firstly, the PPM generator needs to be fixed in stable location; otherwise it may fall in the pleural cavity and give rise to Twiddler's Syndrome.¹¹ This fixation will allow future evaluation and control of pacemaker function as well. Secondly, a left pleural effusion needs to be identified and treated early which may result from a pleural space invasion. Lastly, identification of candidates for potential risk of skin erosion and/or exteriorization can be done as described by Sohail et al.¹² Risk factor analysis for a pacemaker should always be worked out before any intervention.

Conclusion:

Exteriorization of a CIED can be successfully treated by a mini-thoracotomy and relocation of the generator and lead in the intra-pleural space is a suitable alternative in a multi-morbid elderly patient.

Acknowledgement:

We acknowledge the valuable help of Dr. AKM Akram, Thoracic Surgeon, Bangladesh Specialized Hospital for his enormous help in patient management.

Patient Consent: Obtained

Contributors: All authors were involved in the clinical management of the patient and contributed preparing the manuscript.

References:

1. Argüello-Hurtado M¹, Guevara-Valdivia ME, Aranda-Ayala ZL, Hernández-Lara J. Prevalence and implicated risk

factors associated with the exteriorization of cardiac pacemakers: 5 year follow-up. *Rev Med Inst Mex Seguro Soc.* 2015;53 Suppl1:S104-8

2. Kabayadondo MG, de Meester A. Early complications after pacemaker implantations, cardiac pacemakers—biological aspects, clinical applications and possible complications, Edited by Mart M; 2011:161–80. InTech, doi:10.5772/20091. Available from: <http://www.intechopen.com/books/cardiac-pacemakersbiological-aspects-clinical-applications-and-possible-complications/>
3. Kiviniemi, Pirnes, Eranen, HJ et al. (1999). Complications related to permanent pacemaker therapy. *Pacing Clin Electrophysiol*, 22: 711
4. Austin JL, Preis LK, Crampton RS, Beller GA, Martin RP. Analysis of pacemaker malfunction and complications of temporary pacing in the coronary care unit. *Am J Cardiol* 1982;49:301–6
5. Betts TR. Regional survey of temporary transvenous pacing procedures and omplications. *Postgrad Med J* 2003;79:463–5
6. Byrd CL. Management of implant complications. In: Ellenbogen KA, Wilkoff BL, Kay GN, editors. *Clinical cardiac pacing and defibrillation*. London: W.B. Saunders; 2000. p. 677
7. Ardawan Julian Rastan, Nicolas Doll, Thomas Walther, Friedrich Wilhelm Mohr. Pacemaker dependent patients with device infection—a modified approach. *European Journal of Cardio-thoracic Surgery* 27 (2005) 1116–1118
8. Neal Bhatia and Mikhael El-Chami. Leadless pacemakers: a contemporary review. *J Geriatr Cardiol*. 2018 Apr; 15(4): 249–253. doi: 10.11909/j.issn.1671-5411.2018.04.002
9. Yanamandra U, Yanamandra S, Singh N, et al. Infectious pacemaker exteriorisation *BMJ Case Rep* Published online: [10 February 2014] doi:10.1136/bcr-2013-202893
10. Tetsuo Yamaguchi, Takamichi Miyamoto, Yasuteru Yamauchi, Tohru Obayashi. A case report of successful permanent pacemaker implantation via the iliac vein. *Journal of Arrhythmia* 32(2016)151–153
11. T. Fahraeus, C. J. Höijer. Early pacemaker twiddler syndrome. *EP Europace*, Volume 5, Issue 3, July 2003, Pages 279–281, [https://doi.org/10.1016/S1099-5129\(03\)00032-1](https://doi.org/10.1016/S1099-5129(03)00032-1)
12. Muhammad R. Sohail, Daniel Z. Uslan, Akbar H. Khan, Paul A. Friedman, David L. Hayes, Walter R. Wilson, James M. Steckelberg, Sarah M. Stoner and Larry M. Baddour. Risk Factor Analysis of Permanent Pacemaker Infection. *Clinical Infectious Diseases* 2007; 45:166–73. DOI: 10.1086/518889