

Epidermal Inclusion Cyst of Male Breast Following Traumatic Implantation

MM HAQUE^a, MA MAMUN^b, MA RAHMAN^c,
MEHERUNNESA^d, SM BADRUDDOZA^e

Summary:

Epidermal Inclusion cyst of male breast is a rare condition as reported in the literatures.

We had a young male patient who presented with a recurrent breast lump. This case had a number of conflicting

diagnostic movements before being confirmed by histopathological examination of the excised lump to be Epidermal Inclusion cyst. The patient was found to be healthy at follow up after three months.

(J Bangladesh Coll Phys Surg 2012; 30: 96-97)

Introduction:

Epidermal inclusion cysts (EIC) with their consequences are uncommon in the breast ¹

Epidermal inclusion cyst refers to those cysts that are the result of the implantation of epidermal elements in the dermis. However, many cysts originate from the infundibular portion of the hair follicle. They commonly occur in the face, neck, trunk and extremities ². However epidermal inclusion cyst of male breast is not that common. We have a case of epidermal inclusion cyst of male breast with definite history of epidermal implantation.

Case Report:

A 30-year-old male patient was admitted into the surgery unit III of Rajshahi Medical college Hospital on 3rd May

2009 with a lump in the left breast for two years and occasional discharge of a cheesy material through nipple one year back. Initially the lump was small and painless. It gradually increased in size. Six months back the patient had been treated by a local doctor and the lump was drained as an abscess. The nipple discharge ceased after the operation and the lump started to increase in size again. The patient had a history of trauma to the anterior chest wall by accidental falling over a heavy rough wooden board with a definite injury on the left breast areola three years back.

On examination, the non tender lump over the left breast was 4.0 x 3.5 cm in size, firm in consistency, mobile in nature, with a regular margin (Fig: 1). There was a faint scar of previous operation. Underlying structures and overlying skin were free. Fluctuation was negative. No significant changes were elicited in the axillary lymph nodes. The liver was not palpable. The testes were normal. Systemic examination yielded no significant information. Provisional diagnosis was Chronic granulomatous mastitis (left breast). Differential diagnoses were sebaceous cyst of left breast and carcinoma of left breast. FNAC from the breast lump yielded plenty of neutrophils, fair number of macrophages, occasional giant cells. No malignant cell was found. Cytological diagnosis was chronic mastitis with an advice to exclude tuberculosis.

Total count of WBC was 7.4×10^9 /L with 56% neutrophils, 38% lymphocytes, 4% eosinophils and

- Dr. M. Manzurul Haque MBBS, Ph D (Surgery) Associate Professor of Surgery, Rajshahi Medical College, Rajshahi.
- Dr. Md. Abdullah Al Mamun MBBS; Assistant Registrar, Department of Surgery, Rajshahi Medical College, Rajshahi.
- Dr. Md. Atiqur Rahman MBBS; Assistant Registrar, Department of Surgery, Rajshahi Medical College, Rajshahi.
- Dr. Meherunnesa MBBS; M.D. (Pathology); Assistant Professor of Pathology, Rajshahi Medical College, Rajshahi.
- Dr. S.M. Badruddoza MBBS; FCPS(Histopathology) Professor of Pathology, Rajshahi Medical College, Rajshahi.

Address of Correspondence: Dr. M. Manzurul Haque, Associate Professor of Surgery, Rajshahi Medical College, Rajshahi 6000. Bangladesh, Cell: +88 01711 815827, E-mail: drmanzur07@yahoo.com

Received: 17 December, 2009

Accepted: 28 March, 2012

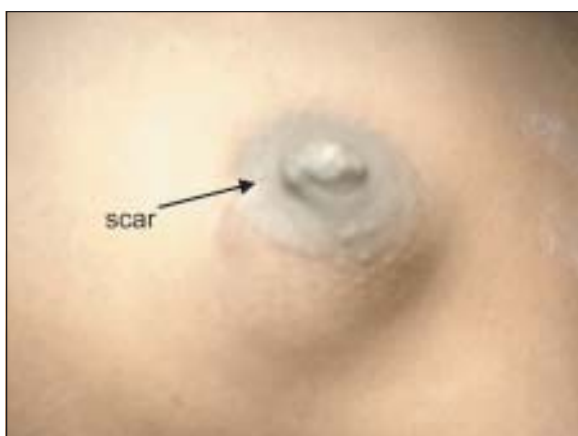

Fig. 1. Photograph of left male breast with epidermal inclusion cyst

2% monocytes. Haemoglobin (Hb) was 108gm/L, ESR 05 mm, RBS: 5.5 mmol/L and S. Creatinine 72.6 μ mol/L. Plain radiograph of chest and USG scanning of abdominal organs were normal. The patient had been subjected to elective surgical intervention. on 14.05.2009. The lump was removed by submammary periareolar incision under GA. The lump was cystic in nature with cheesy material inside (?Granuloma), per operative diagnosis being tuberculosis of breast. Per operative diagnosis was definitely influenced by the cytological findings on FNAC. Histopathological examination of submitted specimen showed breast tissue associated with a cyst wall lined by stratified squamous epithelium filled with keratin materials (Fig.2). Histological diagnosis was Epidermal inclusion cyst of the breast.

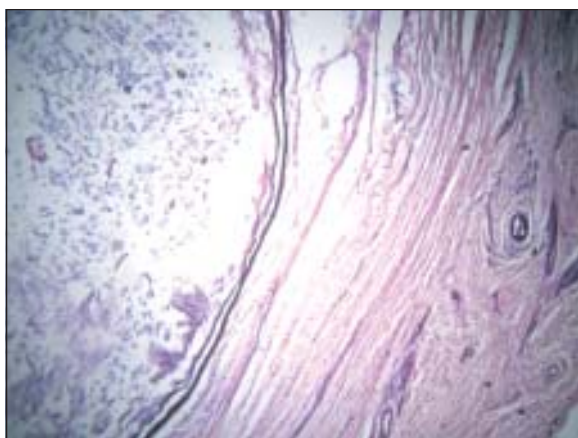


Fig 2. Photomicrograph of histological section of the epidermal inclusion cyst of male breast

Discussion:

Epidermal inclusion cysts in many cases result from implantation of epidermal elements into the dermis. Rare cases of male breast lump include some secondary carcinoma, some haematological malignancies including lymphoma, Hodgkin's disease, plasmacytoma and some benign conditions like myofibroblastoma, papillary hyperplasia, lupus mastitis, haemangioma, hamartoma and granulomatous mastitis³. Epidermal inclusion cyst of the male breast is a rare benign inflammatory lesion with only three cases being reported till 1996². In another series five cases of epidermal inclusion cyst of male breast was reported in a study over a period of 22 years⁴. The diagnosis in all these five cases was based on FNAC only and tissue for histopathological support was not available in any of these cases. True epidermal inclusion cysts result from the implantation of epithelial elements into the dermis frequently associated with injuries. Even apparently minor procedures, such as FNAC of the breast, have been reported to induce epidermal cysts⁵. Our patient had a history of trauma to the chest wall with an inflicting injury to the left breast areola and that might be an inducing factor. Mammographic and sonographic features for epidermal inclusion cyst are not conclusive and leads to confusion³. Interesting to note that FNAC from breast lump of our patient was not supportive of epidermal inclusion cyst and only histopathology could confirm the diagnosis. So an epidermal inclusion cyst may occur even in the male breast and confirmation of diagnosis is difficult without histopathological support.

References:

1. Naruto Taira, Kenjiro Aogi, Shozo Ohsumi, Shigemitsu Takashima, Susumu Kawamura and Rieko Nishimura. Epidermal Inclusion Cyst of the Breast. *Breast Cancer*: 2007; 14:434-437
2. Claudia U. Bergmann-Koester, Hans C. Kolberg, Isabel Rudolf, Stefan Krueger, Joerg Gellissen, Beate M. Stoeckelhuber. Epidermal cyst of the breast mimicking malignancy: clinical, radiological and histological correlation. *Arch. Gynecol Obstet* : 2006; 273: 312-314
3. Catherine B Niewoehner, Anna E Schorer. Gynaecomastia and breast cancer in men. *BMJ* 2008;336: 709-713
4. Kusum Kapila and Kusum Verma. Fine needle aspiration cytology of epidermal inclusion cyst in the male breast – letters to the editor. *Acta Cytology* 2003; 47: 315-317.
5. Davies JD, Nonni A, D'Costa HF. Mammary epidermoid inclusion cysts after wide-core needle biopsies. *Histopathology*. 1997;31(6):549-51.