

# Wegener's Granulomatosis Mimicking Pulmonary Tuberculosis

ABMS ALAM<sup>a</sup>, R DASTIDER<sup>b</sup>, Z AHMED<sup>c</sup>, R RABBANI<sup>d</sup>,

## Summary:

*Wegener's Granulomatosis (WG) is a rare type of multi-system small to medium vessel vasculitis with necrotizing granulomatous inflammation involving the upper airway, lungs and the kidneys. In generalized WG, patient invariably dies within few months if left untreated. The key to better prognosis is early treatment once the diagnosis is made.*

*Our patient is a 21yr young lady who was initially diagnosed as nasal septal abscess and later as pulmonary tuberculosis. She was treated accordingly but did not improve.*

*When presented to us, she had asymmetric polyarthritis, cough with mucoid expectoration, intermittent mild haemoptysis as well as fever with bilateral nasal obstruction*

*and epistaxis of about 2 months duration. She was found to have saddle nose deformity with blocked nasal passage and easily bleeding nasal crusts. Bilateral episcleritis and oral aphthous ulceration were also present. Chest X-Ray showed bilateral consolidations and infiltrates. Her hemoglobin was 6.42 gm% with high ESR and CRP. Microscopic haematuria with high serum creatinine and strongly positive C-ANCA were also found. MRI showed rt maxillary sinusitis and right mastoiditis.*

*Finally she was diagnosed as diffuse Wegener's Granulomatosis according to ACR criteria. She was put on oral cyclophosphamide and prednisolone with satisfactory response on follow up.*

*(J Bangladesh Coll Phys Surg 2012; 30: 98-104)*

## Introduction :

Wegener's Granulomatosis (WG) is a rare multi systemic autoimmune disease characterized by necrotizing granulomatous inflammation of the upper and lower respiratory tracts and the kidneys<sup>1</sup>. It causes classically disseminated small to medium vessel necrotizing vasculitis. It is associated with C-ANCA (Cytoplasmic antineutrophil cytoplasmic antibody) in almost all (90%) during active disease<sup>2,3</sup>. It has a

spectrum of clinical presentations and may be divided broadly into limited and diffuse variety. The limited variety of WG may be the early feature of severe diffuse disease or runs in relapse & remission course that causes more damage to the organs involved threatening patient's life. This limited variety is more common in woman involving only upper or lower respiratory tract or kidney without systemic vasculitis and so may remain undiagnosed<sup>2,3,4</sup>. Both cellular and humoral immunity are thought to be involved in the pathogenesis of Wegener's granulomatosis. The initial pathologic lesion is granuloma believed to be caused by cellular immune processes. The strong association of C-ANCA with this disease suggests the role of humoral immunity<sup>5</sup>.

WG is a worldwide disease. In USA, the prevalence of the disease is estimated to be 3 cases whereas in Europe 5 cases per 100000 population. Internationally the incidence is estimated to be 10.2 cases per million population. WG affects a wide age range (8-99 years) but typically affects at age 30-50 years with almost equal sex ratio (M:F= 1.5:1).

In 1931, Klinger first classified WG as a variant of polyarteritis nodosa. In 1936, the German pathologist Friedrich Wegener first described the disease as a distinct entity with specific clinical and histopathological

- Dr. A B M Sarwar-e-Alam, FCPS (Medicine), Consultant Physician, Department of Internal Medicine, Square Hospitals Limited, Dhaka.
- Dr. Rishin Dastider, DTC, Clinical Staff, Department of Internal Medicine, Square Hospitals Limited, Dhaka.
- Dr. Zubayer Ahmed, MD (Internal Medicine), Clinical Fellow – Rheumatology (Singapore), Associate Consultant, Internal Medicine & Rheumatology, Square Hospitals Limited, Dhaka.
- Dr. Raihan Rabbani, FCPS (Medicine), MD (USA), Board Certified-American Board of Internal Medicine, Associate Consultant, Internal Medicine and Critical Care Medicine, Square Hospitals Limited, Dhaka.

**Address of Correspondence:** Dr. A B M Sarwar-e-Alam, FCPS (Internal Medicine), Consultant Physician, Department of Internal Medicine, Square Hospitals Limited, Dhaka, Mobile : 01712941697, E-mail: drsarwaralam@hotmail.com drsarwaralam@squarehospital.com

**Received:** 02 January, 2011

**Accepted:** 12 October, 2011

criteria. In 1954, Goodman and Churg more fully delineated the clinical and pathological features of the disease and established the three main clinical criteria of WG (systemic necrotizing vasculitis, necrotizing granulomatous inflammation of the respiratory tract, and necrotizing glomerulonephritis). This disease also involves skin, eyes, nervous system and joints at some stage of the disease course<sup>6</sup>.

With current treatment, mortality has improved and morbidity remains considerable. Untreated diffuse WG is associated with high mortality > 90% within 2 years because of respiratory or renal failure (most dies within 5 months). According to a meta-analysis, the 5- years survival rate ranges from 74% - 79%<sup>7</sup> with current treatment. The following table 1 shows ACR classification criteria of Wegener's granulomatosis<sup>8</sup>.

**Table-I**

The American College of Rheumatology 1990 classification criteria of Wegener's Granulomatosis – diagnosis requires 2 or more of

- painful or painless oral ulcer ± a purulent/bloody nasal discharge,
- the chest radiograph may show nodules, cavities or infiltrate,
- microscopic haematuria or red cell casts may be found in urine sediment
- histological changes of granulomatous inflammation within arterial walls is seen on biopsy of the involved tissue.

The presence of 2 or more of this criteria has a sensitivity of 88% and a specificity of 99%.

The American College of Rheumatology 1990 classification criteria of Wegener's Granulomatosis – diagnosis requires 2 or more of — painful or painless oral ulcer ± a purulent/bloody nasal discharge, - the chest radiograph may show nodules, cavities or infiltrate, - microscopic haematuria or red cell casts may be found in urine sediment- histological changes of granulomatous inflammation within arterial walls is seen on biopsy of the involved tissue. The presence of 2 or more of this criteria has a sensitivity of 88% and a specificity of 99%.

### Case Report:

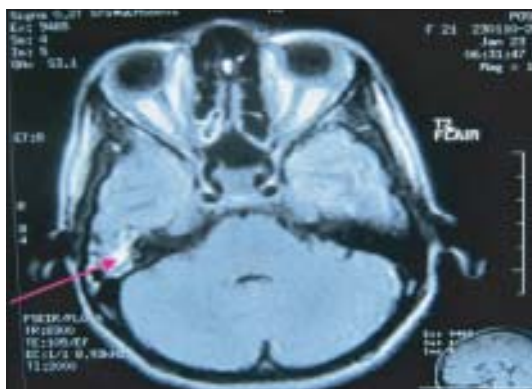
This 21 years old Bangladeshi housewife & mother of one child from Chittagong was admitted to Square Hospital with the complaints of pain in multiple joints of both upper and lower limbs, cough with scanty expectoration occasionally blood stained and nasal obstruction with intermittent epistaxis for 2 months.

Her joint pain started insidiously from the right knee that became swollen with restriction of movement and later on, the pain progressed to the left knee, left elbow, left wrist, small joints of both hands and feet without significant morning stiffness. About 10 days prior to admission, she developed painful swelling of both ankle joints which was severe enough to make her walking difficult. She complained of low grade fever with evening rise and the highest recorded temperature was 101°F. There was no chill or rigor but marked malaise and generalized weakness. She also had paroxysmal shortness of breath and coughing out of scanty whitish sputum with occasional blood stain. Her food intake was low because of anorexia for 3 weeks which worsened as she developed painful tongue ulcers and vomiting. She complained of nasal bleed for 2 months. She also had painless red eyes with watering for the same duration.

There was no antecedent history of diarrhea, urinary symptoms, tuberculosis or contact with active tuberculosis patient. She did not have any other concomitant general illness or any symptoms referable to any other system or connective tissue disease. No family history of a similar or related illness was reported. Her menstrual history was normal.

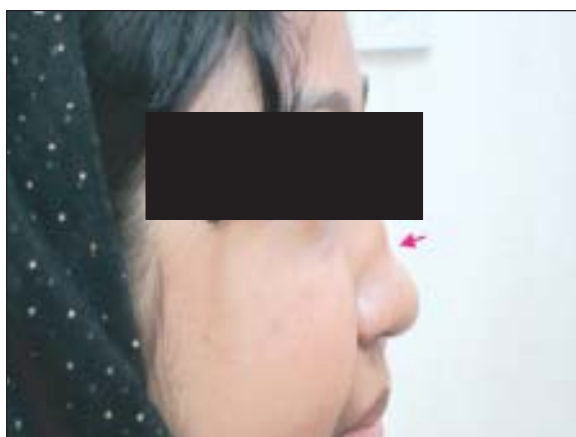Prior to admission in Square hospital, she was assessed by an ENT Surgeon in a local hospital of Chittagong for nasal septal abscess. After incision and drainage it revealed sterile pus. She continued to have nasal obstruction with occasional epistaxis. She was also diagnosed as having pulmonary tuberculosis on the basis of prolonged fever, cough with hemoptysis, radiologically pulmonary consolidation and infiltrates in right mid-zone and left apical area respectively, although negative consecutive three sputum samples for acid-fast bacilli and negative Montoux test. She was started on Category-I anti tubercular therapy 2 weeks prior to admission here. Her clinical status did not improve on anti-tubercular drugs rather her vomiting and anorexia worsened. Pre-admission investigations revealed normocytic moderate anemia (Hb 7.2gm%), Leucocytosis (11.2k/μL) and very high ESR (125mm/hr), normal liver function test and negative blood culture. MRI scan of the Brain on T2 weighted & Flair images

showed hyper-intensities in right mastoid, right middle ear and right maxillary sinus but on T1 weighted image the same areas showed iso-intensity to brain grey matter suggestive of inflammatory changes. MRI of the brain findings are shown in the figure 1.



**Fig-1:** MRI T2FLAIR image showing Right Mastoiditis as showed in arrow head area.

On examination, she was ill looking and markedly pallor with depressed nasal bridge as shown in figure 2, thin emaciated with 40 Kg weight.



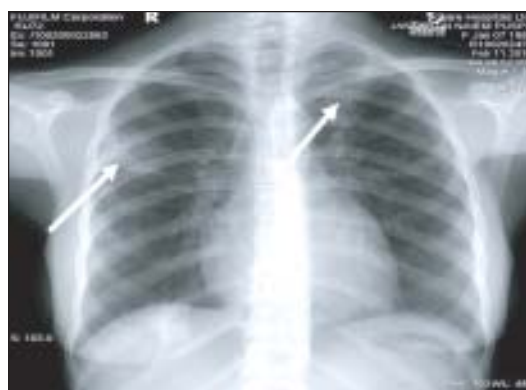**Fig-2:** Photograph showing depressed nasal bridge as showed in arrow head area

She had painless red eyes without jaundice. Thyroid gland examination was normal and there was no lymphadenopathy. There was a large painful ulcer with white base and red margin on the left border of the tongue. Nasal mucosa was full of crusts with recent evidence of bleeding and the air entry was very poor through both nasal cavities that made her to breathe through mouth. Subsequent nasal examination by ENT

consultant revealed nasal septal perforation. There was no tenderness over mastoid process and no neck rigidity. Her ankle joints were swollen with grade 2 tenderness and marked restriction of the movements. Both knee joints were also swollen other tender with mild effusion in the left. Small joints of her hands & feet were tender but didn't show any swelling or deformity. Other systemic examinations revealed no significant abnormality.

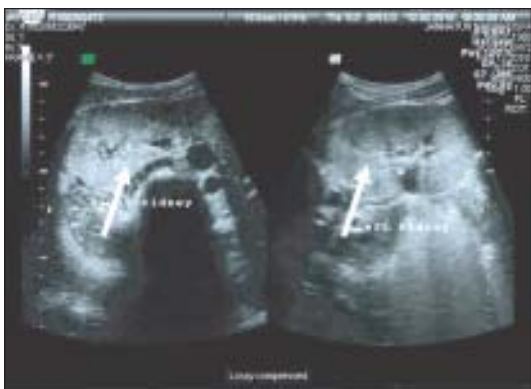Laboratory Investigations after admission to Square Hospital revealed normocytic normochromic anemia with Hb of 6.42 gm/dl and increase in rouleaux on smear, ESR > 140 mm in 1st hour, CRP 79.8 mg/L, Serum Creatinine 3.9 mg/dl, Uric acid 9.7 mg/dl, plenty RBC/HPF in urine microscopy but no cast or crystals, UTP (in 24 hours urine) 0.6 gm/L. Serum ANA, anti-DS DNA, anti-phospholipid antibody and direct Coomb's test were all negative. Serum C3 and C4 level were normal. Her liver function test was also normal. C-ANCA was 39.8 U/ml(normal < 2 ) but normal titre of P-ANCA. X-Ray PNS showed opacified right maxillary sinus as shown in figure 6.

Chest X ray P/A view showed pulmonary consolidation and infiltrates in right mid-zone at the peripheral part and in the left apical area respectively as shown in figure 3.



**Fig-3:** X-Ray Chest PA view showing Consolidation and infiltrates as showed in arrow head area

Ultrasonogram of the abdomen showed normal size and shape of the kidneys with increased cortical echogenicity and loss of cortico-medullary demarcation suggestive of chronic renal parenchymal disease as shown in figure 4.



**Fig.-4:** Ultra sonogram abdomen showing hyperechoic renal parenchyma with loss of cortico-medullary demarcations in both kidneys.

Patient refused to undergo planned renal and nasal biopsy. She was diagnosed as diffuse Wegener's Granulomatosis on the basis of clinical, serological and radiological findings.

she was put on daily oral Cyclophosphamide 2 mg/kg/d and oral Prednisolone 1mg/kg/day. She was also transfused with 3 (three) units of packed RBC and also used topical steroid for eyes and tongue lesions. Before starting immunosuppressive therapy, patient and her spouse were counseled about the disease course, mode, benefit and side effects of treatment including the need for avoidance of pregnancy. After a week of hospitalization, she was discharged home in a relatively better state with advice to continue Cyclophosphamide and Prednisolone in same dose along with other ancillary drugs.

#### Discussion:

Our patient was diagnosed as Wegener's Granulomatosis (WG) on the basis of following findings: 1) bilateral nasal obstruction with saddle nose deformity and epistaxis, painful large aphthous ulceration in the tongue, 2) cough with mild hemoptysis and radiologically pulmonary consolidations and infiltrates. 3) microscopic hematuria with renal failure (serum creatinine 3.9mg%). So, 3 out of 4 recommended criteria were present in this case. Patient refused nasal and renal biopsy so the 4<sup>th</sup> criteria could not be evaluated. she also had acute non-deforming asymmetric polyarthritis, bilateral episcleritis which are the supporting features of WG.

Serum C-ANCA was strongly positive in our patient indicating active WG but serum P-ANCA was negative

as expected. C-ANCA has a high degree of association with WG and it is positive in >90% patient with active disease. The presence of C-ANCA is not required for diagnosis of WG by either ACR or Chaper Hill Consensus Conference (CHCC) definitions. Rarely elevated C-ANCA may be found in association with other autoimmune diseases e.g. microscopic polyangitis (MPA), Churg-Strauss syndrome (CSS), SLE, polyarteritis nodosa (PAN) and Takayasu disease<sup>1,9</sup>. But these diseases can usually be differentiated from WG on the basis of clinical, serological and imaging findings.

Our patient's blood picture showed normocytic normochromic moderate anemia with Hb of 6.42 gm%, and total count 7.08 K/ $\mu$ L, platelet count 321 K/ $\mu$ L. She also had very high ESR > 140 mm in 1st hour and CRP 79.8 mg/L indicating very active inflammation.

Prior to admission in Square Hospitals, she had incision & drainage of nasal septal abscess and subsequently started on empiric anti-tubercular therapy. Clinically and radiologically Wegener's Granulomatosis may mimic pulmonary tuberculosis and may also present like pyogenic nasal septal abscess in localized variety. Study of this case emphasizes that WG must be considered when assessing patients presenting with common respiratory symptoms with x-ray abnormalities in lungs in the form of nodules or infiltrates. High degree of suspicion is required to avoid misdiagnosis specifically in tuberculosis endemic areas otherwise diagnosis can be delayed as happened in our patient.

Ear, nose and throat involvement characteristically occurs up to 90% cases of WG and usually precedes generalized involvement for a long period of time<sup>10</sup>. Our patient developed saddle nose deformity due to granulomatous septal cartilage loss, which was misdiagnosed initially and treated as pyogenic septal abscess. There was also a big oral aphthous ulcer which may occur up to 6%-50% case of WG MRI Brain showed right maxillary sinusitis and right mastoiditis. Pulmonary involvement occurs as much as in 80% patients of WG in the form of cough (34%), hemoptysis (18%), chest discomfort (8%) and dyspnea (7%). Diffuse alveolar hemorrhage due to alveolar capillaritis was reported in 5-45% of cases<sup>10,11</sup>. Radiological common findings are – pulmonary infiltrates (67%), multiple nodules (58%) with or without cavitations and rarely migrating shadows<sup>12</sup>. Our patient had almost

all these radiological features in addition to common symptoms of cough, mild haemoptysis and pleuritic left sided pain.

Renal disease is present in 17% cases at initial diagnosis<sup>1</sup>. It manifests as crescentic necrotizing GN characterized by urinary sediment with more than 5 RBC/hpf or RBC cast<sup>10</sup>. Our patient had high serum creatinine (3.9 mg%) and microscopic hematuria. She also had bilateral asymmetrical non-deforming polyarthritis of the ankle, knee, elbow, wrist and small joints of hands & feet. She also had bilateral episcleritis. Ocular manifestations are reported to occur in 28% - 58% of patients with WG<sup>2</sup>. Other forms of ocular involvement includes scleritis, keratitis, uveitis and conjunctivitis. Rarely proptosis due to retrobulbar granuloma was also reported<sup>2</sup>.

This patient did not develop any dermatological or neurological manifestations. But skin vasculitis manifestation may occur up to 45% case which are palpable purpura, livedo reticularis and pyoderma gangrenosum<sup>10</sup>. Nervous system is affected by WG in 22% of patients manifested by mononeuritis multiplex, sensory-motor polyneuropathy, seizures, stroke, cerebritis, multiple cranial nerves palsy, diabetes insipidus and aseptic meningitis<sup>10</sup>. A almost similar case was reported in teachers association journal (TAJ) of Rajshahi Medical College by Islam Q Tarikul, Ahasan HAM Nazmul et al. in 1993.<sup>13</sup>

Treatment of WG is carried out in two phase: induction of remission and maintenance. The national institute of Health recommends low dose oral cyclophosphamide (2 mg/kg/day) and prednisolone (1 mg/kg/day) which dramatically improves survival. Steroid reduces mortality but less effective alone in inducing remission and so steroid is kept at lowest possible dose<sup>14,15</sup>. Both oral and intravenous therapy of cyclophosphamide have similar efficacy in terms of inducing remission. Intravenous therapy is associated with less side effects but with a high rate of relapse. Patient with pulmonary hemorrhage is to be treated with aggressive immunosuppressive therapy (monthly intravenous cyclophosphamide plus oral prednisolone along with plasmapheresis)<sup>16-18</sup>.

Our patient responded to combination oral immunosuppressive therapy with marked improvement in symptoms and signs along with gradual reduction of

serum creatinine and progressive decrease in RBC counts in urine as found in post-discharge follow up. Remission can be achieved in up to 90% cases within a year of combination immunosuppressive treatment. subsequently cyclophosphamide can be substituted with methotrexate or azathioprine to maintain remission<sup>19-23</sup>.

Newer treatments include intravenous immunoglobulin (IVIG), mycophenolate mofetil, TNF blockers, rituximab, 15-desoxyspergualin, antithymocyte globulin, alemtuzumab and stem cell transplantation<sup>24-38</sup>. Intravenous immunoglobulin (IVIG) may be effective by interfering with ANCAs and thus inhibits ANCA-mediated neutrophil activation<sup>24,25</sup>. Mycophenolate mofetil in combination with prednisolone has been used in small series of refractory WG cases, for both induction and maintenance, with variable responses<sup>26,27</sup>. The initial pilot study showed good response when etanercept was added to standard therapy but the response to infliximab is variable and its use is not recommended yet<sup>28,29</sup>. Clinical improvement or remission with rituximab has been described in the literature. It appears to be more effective in the vasculitic rather than the granulomatous phase<sup>33-36</sup>. 15-desoxyspergualin is a synthetic derivative of spergualin, a protein from *Bacillus laterosporus* that is capable of preventing T- and B-cell maturation and has been used with some success in refractory cases<sup>37,38</sup>. Data about stem cell transplant is very limited<sup>31</sup>.

#### **Conclusion:**

Wegener's Granulomatosis is a rare and invariably fatal form of systemic vasculitis but early diagnosis and management have significant positive impact on future outcome and prognosis.

High degree of suspicion is needed in tuberculosis endemic areas as mode of presentation of either disease may considerably overlap at some stage of the disease course.

Study of this case emphasizes the need for careful consideration and systematic analysis of patient's presenting respiratory symptoms and signs suggestive of pulmonary TB, so that the diagnosis of systemic vasculitis like WG will not be missed or delayed.

#### **Reference:**

1. Hoffman GS, Kerr GS, Leavitt RY, et al. Wegener granulomatosis: an analysis of 158 patients. *Ann Intern Med.* Mar 15 1992;116(6):488-98.

2. Wegener's Granulomatosis Etanercept Trial (WGET) Research Group. Limited versus severe Wegener's granulomatosis: baseline patient data on patients in the Wegener's granulomatosis etanercept trial. *Arthritis Rheum.* August 2003;48(8):2299-2309.
3. Kallenberg CGM. Pathogenesis of PR3-ANCA associated vasculitis. *J Autoimmun.* February-March 2008;30:29-36.
4. Finkielman JD, Lee AS, Hummel AM, et al. ANCA are detectable in nearly all patients with active severe Wegener's Granulomatosis. *Am J Med.* July 2007;120:643.e9-14.
5. Kallenberg CGM, Heeringa P, Stegeman CA. Mechanisms of disease: pathogenesis and treatment of ANCA-associated vasculitis. *Nat Clin Pract Rheumatol.* December 2006;2:661-670.
6. Moosig F, Lamprecht P, Gross WL. Wegener's Granulomatosis: the current view. *Clin Rev Allergy Immunol.* October 2008;35(1-2):19-21.
7. Phillip R, Luqmani R. Mortality in systemic vasculitis: a systematic review. *Clin Exp Rheumatol.* September-October 2008;26:S94-S104.
8. Leavitt RY, Fauci AS, Bloch DA, et al. The American College of Rheumatology 1990 criteria for the classification of Wegener's granulomatosis. *Arthritis Rheum.* August 1990;33(8):1101-1107.
9. Nolle B, Specs D, Ludemann j, Rohrbach MS, De Remee Ra, Gross WL. Anticytoplasmic autoantibodies: Their Immuno diagnostic value in Wegener's granulomatosis. *Am Intern Med* 1989; 111:28-40
10. Fauci AS, Haynes BS, Katz P, Wolff SM. Wegener's granulomatosis: prospective clinical and therapeutic experience with 85 patients for 21 years. *Ann Intern Med.* January 1983;98(1):76-85.
11. Manganelli P, Fietta P, Carotti M, Pesci A, Salaffi F. Respiratory system involvement in systemic vasculitis. *Clin Exp Rheumatol.* March-April 2006;24:S48-S59.
12. Polychronopoulos VS, Prakash UBS, Golbin JM, Edell ES, Specks U. Airway involvement in Wegener's Granulomatosis. *Rheum Dis Clin N Am.* November 2007;33:755-775.
13. Islam QT, Ahasan HAM, Chowdhury MAJ, et al. Wegener's granulomatosis – a case report. *TAJ*,1993;6:68-69.
14. Mukhtyar C, Guillevin L, Cid MC, et al. EULAR recommendations for the management of primary small and medium vessel vasculitis. *Ann Rheum Dis.* March 2009;68:310-317.
15. Walsh M, Merkel PA, Mahr A, Jayne D. Effects of duration of glucocorticoid therapy on relapse rate in antineutrophil cytoplasmic antibody-associated vasculitis: A meta-analysis. *Arthritis Care Res (Hoboken).* Aug 2010;62(8):1166-73.
16. Pusey CD, Rees AJ, Evans DJ, Peters DK, Lockwood CM. Plasma exchange in focal necrotizing glomerulonephritis without anti-GBM antibodies. *Kidney Int.* October 1991;40(4):757-763.
17. [Best Evidence] Jayne DR, Gaskin G, Rasmussen N, et al. Randomized trial of plasma exchange or high-dosage methylprednisolone as adjunctive therapy for severe renal vasculitis. *J Am Soc Nephrol.* July 2007;18(7):2180-2188.
18. Klemmer PJ, Chalermkulrat W, Reif MS, Hogan SL, Henke DC, Falk RJ. Plasmapheresis therapy for diffuse alveolar hemorrhage in patients with small-vessel vasculitis. *Am J Kidney Dis.* December 2003;42(6):1149-1153.
19. Jayne D, Rasmussen N, Andrassey K, et al. A randomized trial of maintenance therapy for vasculitis associated with antineutrophil cytoplasmic antibodies. *N Engl J Med.* July 2003;349(1):36-44.
20. Sanders JS, Slot MC, Stegeman CA. Maintenance therapy for vasculitis associated with antineutrophil cytoplasmic autoantibodies. *N Engl J Med.* November 2003;349(21):2072-2073.
21. Slot MC, Tervaert JW, Boomsma MM, Stegeman CA. Positive classic antineutrophil cytoplasmic antibody (C-ANCA) titer at switch to azathioprine therapy associated with relapse in proteinase 3-related vasculitis. *Arthritis Rheum.* April 2004;51(2):269-273
22. Pagnoux C, Mahr A, Hamidou MA, et al. Azathioprine or methotrexate maintenance for ANCA-associated vasculitis. *N Engl J Med.* December 2008;359:2790-2803.
23. Metzler C, Miehle N, Manger K, et al. Elevated relapse rate under oral methotrexate versus leflunomide for maintenance of remission in Wegener's granulomatosis. *Rheumatology (Oxford).* July 2007;46(7):1087-1091
24. Bosch X, Guilabert A, Espinosa G, Mirapeix E. Treatment of antineutrophil cytoplasmic antibody-associated vasculitis: a systematic review. *JAMA.* August 2007;298:655-669.
25. Martinez V, Cohen P, Pagnoux C, et al. Intravenous immunoglobulins for relapses of systemic vasculitides associated with antineutrophil cytoplasmic autoantibodies: results of a multicenter, prospective, open-label study of twenty-two patients. *Arthritis Rheum.* January 2008;58(1):308-371.
26. Joy MS, Hogan SL, Jennette JC, Falk RJ, Nachman PH. A pilot study using mycophenolate mofetil in relapsing or resistant ANCA small vessel vasculitis. *Nephrol Dial Transplant.* December 2005;20(12):2725-2732.
27. Koukoulaki M, Jayne DR. Mycophenolate mofetil in antineutrophil cytoplasm antibodies-associated systemic vasculitis. *Nephron Clin Pract.* 2006;102(3-4):c100-7.
28. Stone JH, Uhlfelder ML, Hellmann DB, Crook S, Bedocs NM, Hoffman GS. Etanercept combined with conventional treatment in Wegener's granulomatosis: a six-month open-label trial to evaluate safety. *Arthritis Rheum.* May 2001;44(5):1149-1154.
29. Wegener's Granulomatosis Etanercept Trial (WGET) Research Group. Etanercept plus standard therapy for Wegener's Granulomatosis. *N Engl J Med.* Jan 27 2005;352(4):351-61..

30. Booth A, Harper L, Hammad T, Bacon P, Griffith M, Levy J, et al. Prospective study of TNFalpha blockade with infliximab in anti-neutrophil cytoplasmic antibody-associated systemic vasculitis. *J Am Soc Nephrol*. Mar 2004;15(3):717-21.
31. Lee RW, D'Cruz DP. Novel therapies for anti-neutrophil cytoplasmic antibody-associated vasculitis. *Drugs*. 2008;68:747-770.
32. Sangle SR, Hughes GR, D'Cruz DP. Infliximab in patients with systemic vasculitis that is difficult to treat: poor outcome and significant adverse effects. *Ann Rheum Dis*. April 2007;66(4):564-565.
33. Stasi R, Stipa E, Del Poeta G, Amadori S, Newland AC, Provan D. Long-term observation of patients with anti-neutrophil cytoplasmic antibody-associated vasculitis treated with rituximab. *Rheumatology* (Oxford). November 2006;45(11):1432-1436.
34. Keogh KA, Ytterberg SR, Fervenza FC, Carlson KA, Schroeder DR, Specks U. Rituximab for refractory Wegener's granulomatosis: report of a prospective, open-label pilot trial. *Am J Respir Crit Care Med*. January 2006;173(2):180-187.
35. Aries PM, Hellmich B, Voswinkel J, et al. Lack of efficacy of rituximab in Wegener's granulomatosis with refractory granulomatous manifestations. *Ann Rheum Dis*. July 2006;65(7):853-858.
36. Seo P, Specks U, Keogh KA. Efficacy of rituximab in limited Wegener's granulomatosis with refractory granulomatous manifestations. *J Rheumatol*. October 2008;35(10):2017-2023.
37. Hinze CH, Colbert RA. B-cell depletion in Wegener's Granulomatosis. *Clin Rev Allergy Immunol*. June 2008;34:372-379.
38. Schmitt WH, Birck R, Heinzel PA, et al. Prolonged treatment of refractory Wegener's granulomatosis with 15-deoxyspergualin: an open study in seven patients. *Nephrol Dial Transplant*. June 2005;20(6):1083-1092.