

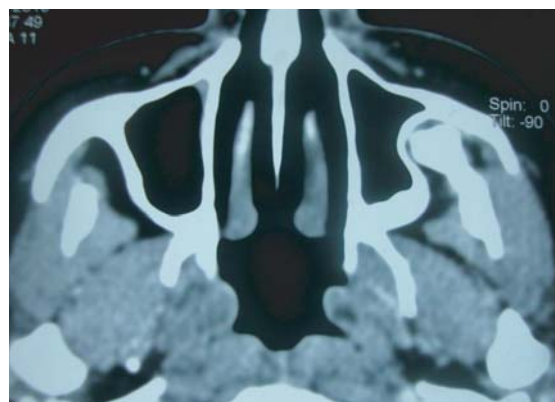
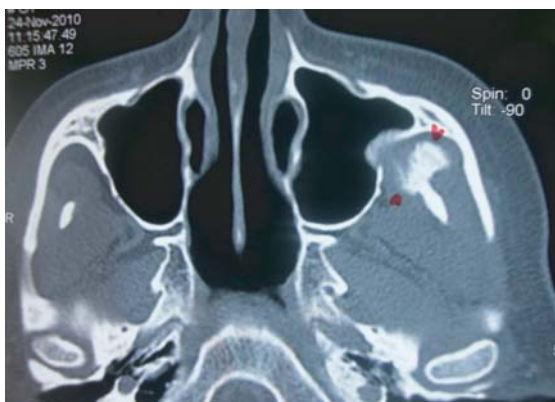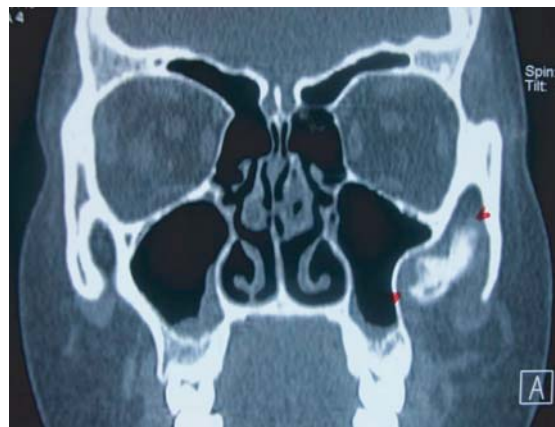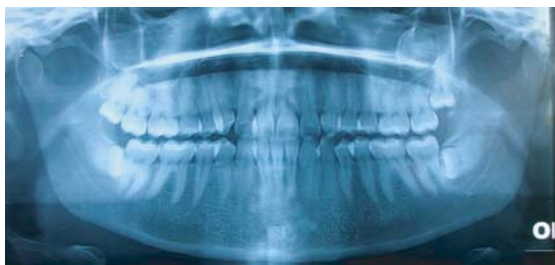SHORT COMMUNICATION

Images in Medical Practice

A Patient with Rare Cause of Restricted Mouth Opening

S. M. ANWAR SADAT^a, SUFIA NASRIN RITA^b, MAHFUJUL HAQ KHAN^c

(*J Bangladesh Coll Phys Surg 2011; 29: 109-110*)



A 30-year-old female patient presented with gradual inability to open her mouth for last eight months without any history of accidental injury to face, dental pain or associated fever. She was quite healthy without any habit of betel quid chewing. Clinical examination of patient

revealed inadequate mouth opening with inter incisal opening of 12 mm, restricted movement of both TMJs in all dimensions with no tenderness or palpable swelling in TMJs areas and over the surfaces of mandible and maxillae. Intra-oral examination revealed unerupted all 3rd molars with normal dento-alveolar and mucosal contours as seen through limited mouth opening. Orthopantomogram of mandible and maxillae showed deep seated horizontal impaction of lower 3rd molars and vertical impaction of upper 3rd molars without any evidence of bony lesion in both lower and upper jaws. Suspecting any pathology in coronoid process, pterygomaxillary fissure, infra-temporal and temporal spaces, a CT Scan of maxillofacial region was advised

- Dr. S. M. Anwar Sadat, BDS, MCPS (Dental Surgery), FCPS, MS (Oral & Maxillofacial Surgery), Dept. of Oral & Maxillofacial Surgery, Dhaka Dental College & Hospital.
- Dr. Sufia Nasrin Rita, BDS, FCPS, Assistant Professor & Head, Dept. of Orthodontics, Sapporo Dental College.
- Dr. Mahfujul Haq Khan, BDS, DDS (BSMMU), PhD (Japan), Post Doc JSPS, Fellow (Japan), Associate Professor and Consultant, Department of Dentistry, BIRDEM Hospital & Ibrahim Medical College, Dhaka

which showed a mushroom shaped bony lesion attached to the tip of coronoid process which compressed the lateral wall of the left maxillary antrum with remodeling of bony wall of the antrum. Lucent areas with surrounding osteosclerotic change were seen at bony outgrowth. Considering the possibility of osteochondroma, the area was exposed through intra-oral approach under general anesthesia and the mass was removed with a part of coronoid process. Histologically the lesion was confirmed as osteochondroma. After one and half month follow up, patient's mouth opening is 25 mm normally and 30 mm with stretching. Considering the experience of such case, tumor or tumor like lesions can be suspected as one of

the causes of trismus or ankylosis (extra-articular) of TMJ which is usually not considered in daily practice.

References:

1. Yesildag A, Yariktas M, Doner F, Aydin G, Munduz M, Topal U. Osteochondroma of the Coronoid Process and Joint Formation with Zygomatic Arch (Jacob Disease): Report of a Case. *Eur J Dent.* 2010; 4(1): 91–94.
2. Akan H, Mehreliyeva N. The value of three-dimensional computed tomography in diagnosis and management of Osteochondroma of the Coronoid Process (Jacob's disease). *Dentomaxillofac Radiol.* 2006; 35(1):55-9.
3. Escuder i de la Torre O, Vert Klok E, Marí i Roig A, Mommaerts MY, Pericot i Ayats J. Jacob's disease: report of two cases and review of the literature. *J Craniomaxillofac Surg.* 2001; 29(6):372-6.