

A Foreign Body in the Rectum

M T ISLAM^a, M A BAQUI^b, S AHMED^c, N BEGUM^d

(*J Bangladesh Coll Phys Surg 2012; 30: 234-235*)

A 35 year old male presented at 1700 hours with the history of having inserted a body spray container into the rectum about 28 hours earlier. He had tried to remove the container himself without success. He had no other symptoms and on examination the object was palpable in left lower abdomen, anus and rectum were normal. A plain X-ray of the abdomen showed the foreign body (Fig. 1.). He was prescribed 30 ml lactulose, 50 ml liquid paraffin orally and six stick of glycerin suppository per rectally on the night of admission with the hope of spontaneous evacuation. But on the next day morning he passed small soft stool only and as there was no signs of obstruction 200 ml of enema (100 ml soap water mixed with 100 ml liquid paraffin) was given but failed to evacuate the foreign body. So he was planned for manual extraction or laparotomy under general anesthesia as a routine case on next day morning (3rd day of admission). Surprisingly, he passed the foreign body at 1630 hours on second day of admission with combined effort of self-abdominal manipulation and bearing down. He was observed for any complication and allowed oral feeding on next day.

Foreign body insertion in the rectum has been extensively described in the surgical literature, with the

earliest reports dating back to the 16th century.¹ A problem commonly encountered in patients with rectal foreign body is the delay in presentation.^{2,3} The clinical presentation is varied, depending on the presence or absence of complications (being perforation, peritonitis and intra-abdominal abscesses).⁴ Diagnosis can be made in the majority of cases with accurate history and confirmed with plain radiographs (plain film abdominal radiography is the recommended first-line approach, as the objects are usually radio-opaque).

Various techniques for removal are available, including some that are minimally invasive. The appropriate technique will depend on the size and surface of the retained object and the presence of complications such as perforation or obstruction.³ An attempt at manual retrieval of the foreign body is always warranted as a first step, with or without light sedation. If this is unsuccessful, or there is evidence of significant bowel injury or even perforation, surgical intervention is warranted.¹

Although the majority of patients with rectal FB require an examination under anaesthesia or even, on occasion, a laparotomy for removal, a few FB may pass spontaneously after the administration of enemas or laxatives.⁵ After FB extraction, all patients must

- Lt. Col Md Tanvirul Islam, FCPS, Fellow Colon and Rectal Surgery (NUH, Singapore), Classified Specialist in Surgery, Combined Military Hospital, Dhaka Cantonment.
- Brig Gen Mohammad Abdul Baqui, FCPS, Professor & Head, Department of Surgery, Armed Forces Medical College. Adviser Specialist Combined Military Hospital, Dhaka Cantonment.
- Lt. Col Siddique Ahmed, FCPS, Associate Professor of Surgery, Classified Specialist in Surgery, Armed Forces Medical College, Dhaka Cantonment.
- Lt Col Nasrin Begum, MPhil, Graded Specialist in Anatomy, Armed Forces Medical College, Dhaka Cantonment.

Address of Correspondence: Lt. Col Md Tanvirul Islam, FCPS, Fellow Colon and Rectal Surgery (NUH, Singapore), Classified Specialist in Surgery, Combined Military Hospital, Dhaka Cantonment, Dhaka-1206. Mobile: 01712562358, Email: tanvir-cr@hotmail.com

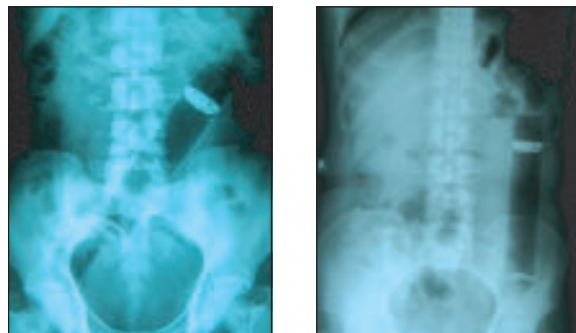


Fig. -1: Plain X-ray showing rectal foreign body

remain in observation to exclude possible rectal perforation.

References:

1. Kasotakisa G, Roediger L, S. Mittal S, Rectal foreign bodies: A case report and review of the literature. *International Journal of Surgery Case Reports* 2012; 3:111–115.
2. Goldberg JE, Steele SR. Rectal foreign bodies. *Surg Clin North Am* 2010;90:173–84.
3. Kurer MA, Davey C, Khan S, Chintapatla S. Colorectal foreign bodies: a systematic review. *Colorectal Dis* 2010;12 September (9):851–61.
4. Clarke DL, Buccimazza I, Anderson FA, et al. Colorectal foreign bodies. *Colorectal Dis* 2005; 7:98–103.
5. Rodríguez-Hermosa JI, Codina-Cazador A, Ruiz B, et al. Management of foreign bodies in the rectum. *Colorectal Dis* 2007; 9:543–548.