

Ocular Imaging

MZ RAHMAN^a, J AHMED^b

(*J Bangladesh Coll Phys Surg 2014; 32: 110-111*)

Case Report:

1st case: A 45 years old lady, normotensive, non diabetic presented to us with complaints of recurrent attack of pain, redness both eyes for 6 months, that were improved with the use of topical steroid. She also complains of dimness of vision in her both eyes for 2 months. On examination there were anterior Uveitis, vitritis, bilateral optic disc swelling and choroidal nodule. This inflammation and nodule give us clues for granulomatous uveitis. Her ESR was -40 mm in 1st hour, MT was 2mm induration, X-ray chest showed bilateral enlarged hilar lymph node, CT scan of brain was unremarkable. Our clinical diagnosis was bilateral granulomatous panuveitis with involvement of optic disc due to sarcoidosis.

We have started topical steroid and with the consultation with neurologist and pulmonologist oral prednisolone was started. The disease process well responded with the treatment.

2nd case: A 29 years old gentleman presented with the bilateral decrease vision for 3 months. On examination there found large granuloma involving optic nerve head that leads to disc swelling, macular edema, hard exudates, haemorrhages and vascular tortuosity. His ESR was 35 mm in 1st hour, MT showed no induration's, X-ray chest, HRCT chest, CT scan of brain were unremarkable, serum ACE was 120 IU/L. The clinical diagnosis of sarcoid granuloma involving optic nerve head was made. With consultation of neurologist oral prednisolone was started, the lesions healed completely.

1. Dr. Md. Zahedur Rahman, Consultant Ophthalmologist, Specialist in Uveal Diseases and Ocular Inflammation, Bangladesh Eye Hospital.
2. Prof. Jalal Ahmed, Director, Professor & Head, Department of Cataract, National Institute of Ophthalmology, Consultant Phaco and LASIK, Bangladesh Eye Hospital.

Address of Correspondence: Dr. Md. Zahedur Rahman, Consultant Ophthalmologist, Specialist in Uveal Diseases and Ocular Inflammation, Bangladesh Eye Hospital.

The images:

The fundus photograph of right eye of 1st patient (1 A) shows mild optic disc swelling otherwise normal fundus.

The fundus photograph of left eye (Fig: 1 B) shows obvious disc swelling, hyperemic disc and small nodule in peripheral fundus.

The fundus fluorescein angiography of both eyes (Fig: 1 C) showing hyperfluorescence of optic disc due to staining.

The X- chest (Fig: 1 D) of same patient shows bilateral hilar lymphadenopathy.

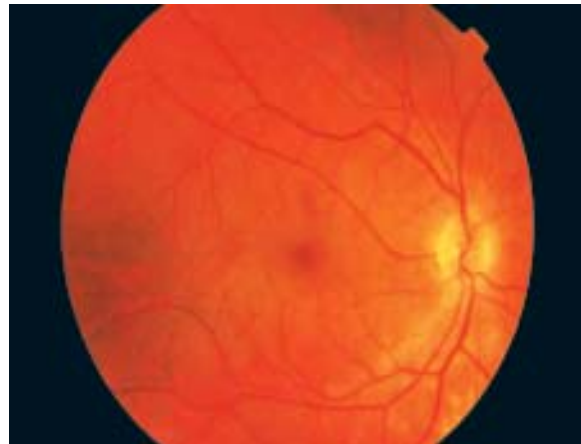

Fig.-1(A)

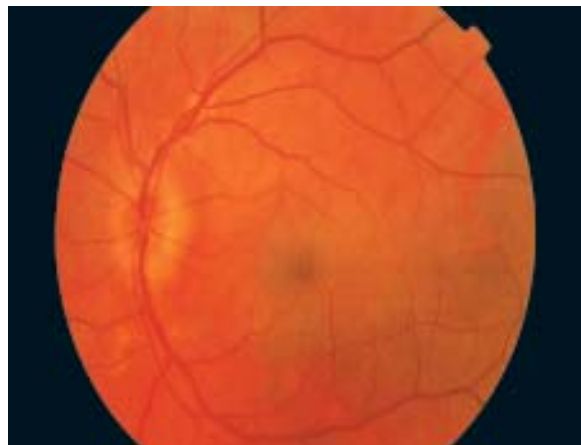

Fig.-1(B)




Fig.-1(C)

The fundus photograph of right eye (Fig:2A) of 2nd patient showing, large yellow white elevated lesion involving optic nerve head extending superiotemporally towards superotemporal vascular arcade and macula. There are also present disc swelling, overlying haemorrhage and vascular tortucity macular edema, hard exudates.

The fundus photograph of right eyes of the 2nd patient after treatment showing, the granuloma involving optic nerve head completely resolved. The macular edema, disc swelling, hard exudates, hemorrhages also resolved and the vascular tortucity decrease.

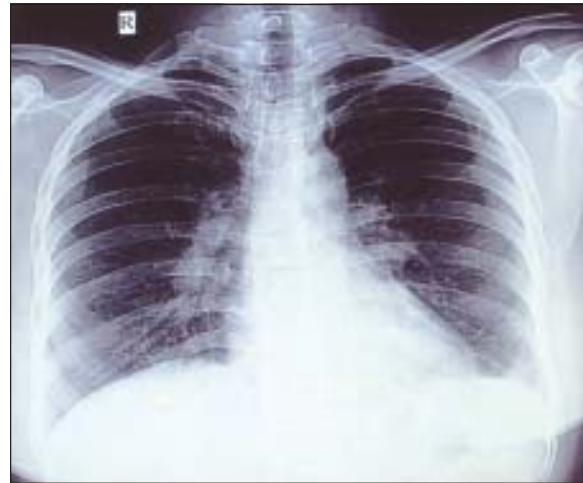

Fig.-1(D)

Differentials:

Bilateral optic disc swelling may be due to raised intracranial due to ICSOL, benign intracranial hypertension, intracranial vascular malignant hypertension, occlusion etc.

Granulomatous uveitis with optic disc swelling may be due to sarcoidosis, tuberculosis, Vogt Koyanaga Harada disease.

Conclusion:

Various systemic diseases like sarcoidosis, tuberculosis, rheumatoid arthritis, SLE, seronegative arthropathy, Behcet, disease etc, ocular manifestation maybe the 1st presentation.

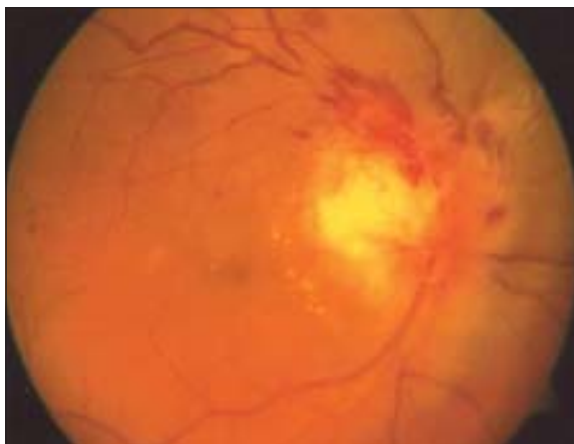

Fig.-2 (A)

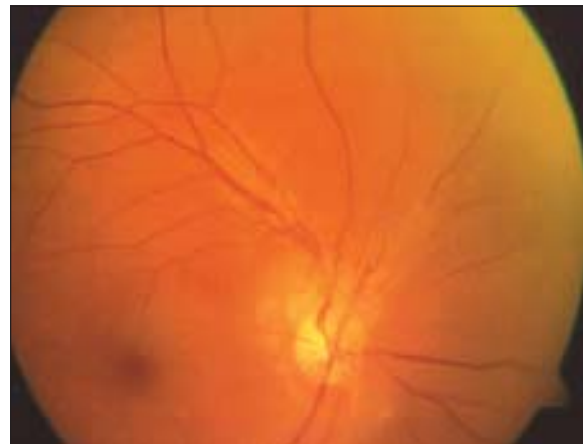

Fig.-2 (B)