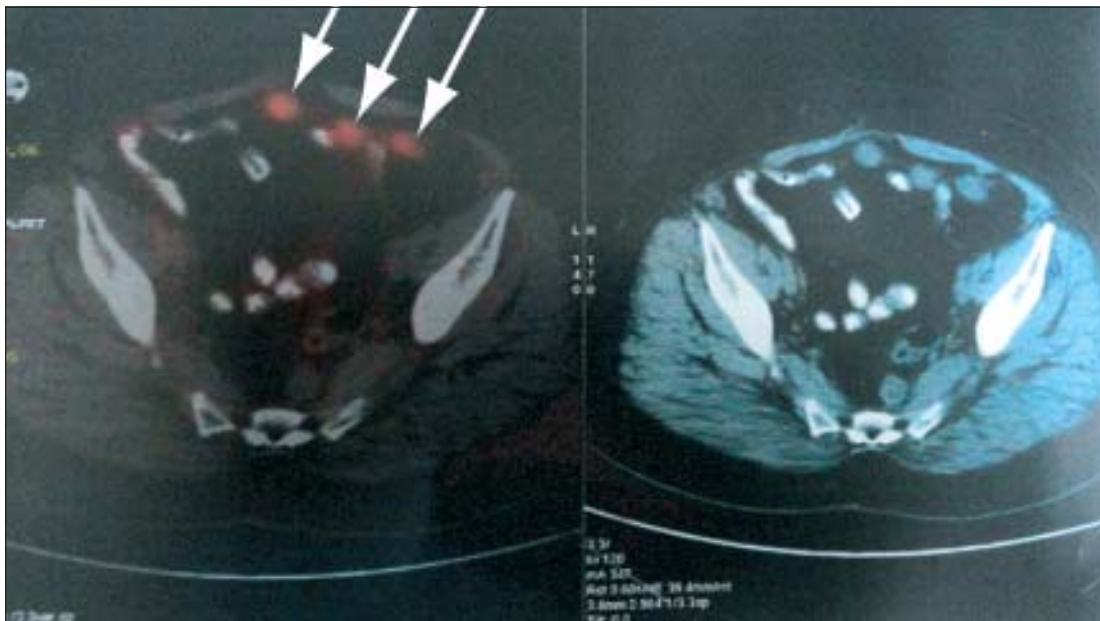


# Detection of Omental Recurrence of Colorectal Cancer by FDG-PET/CT

MM RAHMAN

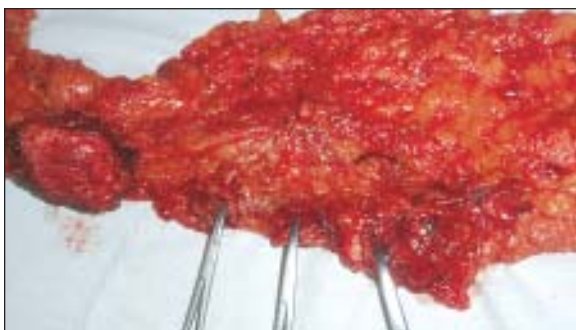A 48 year old lady underwent anterior resection of rectosigmoid colon for a tumour in the upper rectum in September 2011. High ligation of the inferior mesenteric artery and total mesorectal excision done during the operative procedure. Histopathology report revealed moderately differentiated adenocarcinoma. All ends of the colon were tumour free. There was no evidence of lymph node involvement. She received six cycle chemotherapy containing Oxaliplatin and capecitabine afterwards. She was running well, enjoying a healthy family life after the treatment. Dietary and bowel habit was normal. She was under strict follow up with S CEA level, USG examination of the abdomen and colonoscopy every six months after initial treatment. All were within normal limit. In January 2015, she

developed lower abdominal pain, but bowel habit was normal, serum CEA level was 50 ng/ml, colonoscopy, ultrasonography was normal, only a lump found adhered with parietal wall which was detected in CT scan. But PET/CT examination revealed multiple high FDG uptake suggesting recurrences in the abdominal cavity in the area of lower abdomen, not related with gut in addition to the parietal lump which was earlier detected by CT scan. After laparotomy, along with a lump adhered to parietal wall on the right side, there was multiple seedlings on the omentum matching with the PET/CT findings. Excision of the lump along with omentectomy done. Histopathological analysis yielded a diagnosis of metastatic adenocarcinoma from the omental lesion.

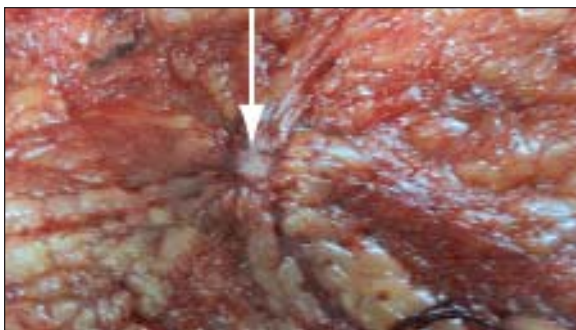


**Fig.-1:** Marked areas show increased FDG uptake in a PET/CT Scan suggesting metastatic deposits

Recurrence develops within 3 years after radical surgery for co-lon cancer in 83.6% of recurrent colon cancer cases and is very rarely detected after 5 years (3.6% of cases)<sup>1</sup>. Therefore, regular follow-up with various diagnostic modalities until 5 years after surgery is a reasonable strategy to detect recurrent disease. The commonly used imaging modalities in such cases include ultrasonography, computed tomography (CT), and magnetic resonance imaging (MRI). However, <sup>18</sup>F-fluorodeoxyglucose glucose-positron emission tomography (FDG-PET) is more effective in determining the presence of malignancy, especially in cases of colorectal cancer (CRC)<sup>2</sup>.



**Fig.-2:** Post operative view of greater omentum shows three metastatic seedlings marked by artery forceps



**Fig.-3:** Close view of the metastatic seedling in the omentum-marked by the arrow.

Locoregional pelvic recurrence and liver metastases are the major sites of relapse after resection of CRC. Recurrence occurs in one third of patients in the first 2 years after resection. Patterns of recurrence are different in colon cancer compared with rectal cancer. Local recurrence is more common in patients with rectal rather

than colon cancer ranging from 7% to 33% and 1–19%, respectively<sup>3</sup>,

Detection of recurrent lesions usually involves serum tumor marker level measurement, ultrasonography, CT, and MRI. In addition, the efficacy of FDG-PET has been confirmed<sup>4</sup>. Luboldt et al. reported that FDG-PET/CT provided promising accuracy for colorectal mass detection and that, in all carcinomas and adenomas with high-grade dysplasia<sup>5</sup>. A review by Visioni and Kim stated that the sensitivity and specificity of PET-CT in detecting CRC recurrence were 89–95% and 83–92%, respectively<sup>6</sup>. One of the studies evaluated in that review<sup>7</sup> reported a positive predictive value of 96.4% and a negative predictive value of 76.9% for the diagnosis of CRC recurrence by PET-CT. So PET/CT is a useful tool for the diagnosis of recurrence of colorectal cancer even in a smaller size within omentum and peritoneum. which are missed in traditional CT scan examination.. After that appropriate measures like radical surgery improves the total survival of the patient.

#### References:

1. Kobayashi H, Mochizuki H, Sugihara K et al: Characteristics of recurrence and surveillance tools after curative resection for colorectal cancer: A multicenter study. *Surgery*, 2007; 141(1): 67–75.
2. Takashi Orii B Motohiro Okumura B Masaki Yoshimura B Hiroe Kitahara B Yukihiro Karasawa .*Am J Case Rep*, 2015; 16: 149-152
3. Owen J, O'Connor, Shanaugh McDermott, James Slattery, Dushyant Sahani, and Michael A. Blake. The Use of PET-CT in the Assessment of Patients with Colorectal Carcinoma. *Internat J Surg Oncol* 2011 <http://dx.doi.org/10.1155/2011/846512>.
4. Sarikaya I, Bloomston M, Povoski SP et al: FDG-PET scan in patients with clinically and/or radiologically suspicious colorectal recurrence but normal CEA. *World J Surg Oncol*, 2007; 5: 64
5. Luboldt W, Volker T, Wiedemann B et al: Detection of relevant colonic neoplasms with PET/CT: promising accuracy with minimal CT dose and a standardized PET cut-off. *Eur Radiol*, 2010; 20(9): 2274–85
6. Visioni A, Kim J: Positron Emission Tomography (PET) for benign and malignant disease. *Surg Clin North Am*, 2011; 91(1): 249–66
7. Chen LB, Tong JL, Song HZ et al: <sup>18</sup>F-DG PET/CT in detection of recurrence and metastasis of colorectal cancer. *World J Gastroenterol*, 2007; 13(37): 5025–29.