

A Young Male with Blurring of Vision

MD ROBED AMIN^a, RAHAT ARA KHAN RUHEE^b

(*J Bangladesh Coll Phys Surg 2019; 37: 46*)

Mr. X, a 24-year-old non-diabetic, normotensive man, hailing from Kaliganj presented in DMCH with the complaints of several episodes of vomiting for one day and blurring of vision for the same duration of time after ingestion of 180 mL (6 units) of vodka (ethyl alcohol) mixing with other agent on the previous night. The patient also complained of blurring of vision of his left eye which occurred suddenly, was painless, involving both eyes within a few hours. It progressed for the next 24 hours after which it started getting better. The patient admits to drinking alcohol every two to three months; however, is not a habitual drinker. These episodes involve binge drinking with smoking tobacco.

There was no history of trauma, orbital tenderness, quadrant or altitudinal hemianopia, dryness, grittiness, headache, facial pain, weakness, tinnitus or hearing difficulties. There was no hematemesis, melena, head trauma, headache, neck stiffness, altered mental status and the patient denied a history of migraine. His vomiting was not voluntarily induced and occurred spontaneously.

On examination, he was ataxic, incoherent speech.

The patient admits to drinking alcohol every two to three months; however, is not a habitual drinker. These episodes involve binge drinking with smoking tobacco. Visual acuity was 6/60, field of vision is impaired peripherally, color vision was distorted,

Ophthalmoscopy revealed bilateral retinal whitening, flakes peripherally in all four quadrants. An MRI revealed hyperdensity in frontal and basal ganglion areas with haemorrhagic area in rt lentiform nucleus. Patient was diagnosed as Methanol poisoning with CNS and Eye toxicity.

The characteristic MRI findings in methanol toxicity are bilateral putaminal hyperdensity and Haemorrhagic manifestation as a result of necroses. This finding is although not specific to methanol toxicity but is commonly observed¹. These findings are usually result from the direct toxic effects of methanol metabolites and metabolic acidosis in the basal ganglia². Cerebral and intraventricular hemorrhage, cerebellar necrosis, diffuse cerebral edema, bilateral subcortical white matter necrosis or edema, and optic nerve necrosis all have been described in severe methanol intoxication,^{2,3}. Optic nerve demyelination secondary to formic acid has been suggested as responsible for optic nerve damage with or without axonal loss.

1. Hsu HH, Chen CY, Chen FH, et al. Optic atrophy and cerebral infarcts caused by methanol intoxication: MRI. *Neuroradiology* 1997;39:192-94
2. Gaul HP, Wallace CJ, Auer RN, et al. MR findings in methanol intoxication. *AJNR Am J Neuroradiol* 1995;16:1783-86
3. Halavaara J, Valanne L, Setälä K. Neuroimaging supports the clinical diagnosis of methanol poisoning *Neuroradiology*, 2002;44:924-28

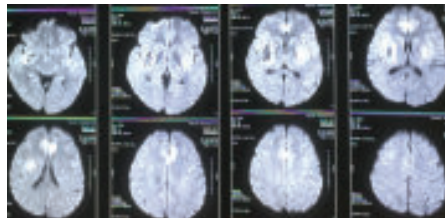
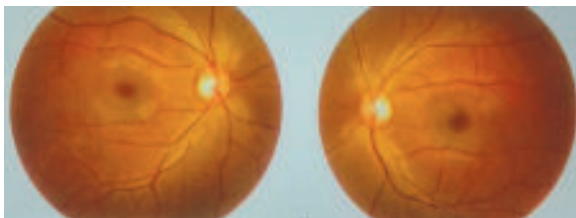


Fig.-1: (a) Ophthalmoscopy after the treatment, (b) MRI showing methanol effect in Brain

a. Dr. Md. Robed Amin, Associate Professor of Medicine, Dhaka Medical College

b. Dr. Rahat Ara Khan Ruhee, Honorary Medical Officer, Dpt of Medicine, Dhaka Medical College

LETTER TO THE EDITOR

(*J Bangladesh Coll Phys Surg 2019; 37: 47-48*)

Serum Procalcitonin as a Predictor of Bacteremia in Burn Injury.

Faisal Johandi^a, Si Jack Chong^{a,b}

- a. Department of Plastic, Reconstructive and Aesthetic Surgery, Singapore General Hospital, Singapore
- b. Department of Plastic, Reconstructive and Aesthetic Surgery, Sengkang General Hospital, Singapore

Address of Correspondence: Faisal Johandi, Outram Road, Singapore 169608, Telephone number: +65 91062004, E-mail address: muhammadfaisal.johandi@mohh.com.sg

Introduction:

Sepsis is a clinical syndrome that is caused by a dysregulated inflammatory response to infection, which can lead to multiple organ failure and eventual death. It involves physiologic, biologic, and biochemical abnormalities.¹ Early identification of sepsis in a burns patient would ensure that appropriate management is provided early. Bacteremia, a dreaded complication of burn injury often seen in sepsis, is associated with an increased risk of bacterial spread to multiple end organs thereby increasing the risk of morbidity and mortality. Early evidence of bacteremia is often not readily available, as it would require a thorough and time-consuming blood culture bacterial growth analysis. Hence, a reliable and accessible tool to predict the possibility of bacteremia in burn injury would help guide physicians in the care of critically ill patients. In this study, we evaluate the clinical role of serum procalcitonin as an early predictor of bacteremia in burn patients.

Methods:

In our institution, we maintain a prospective database of all burns patients. In this study, we performed a review of patients who were admitted to our Burns Intensive Care Unit over a 3-year period (June 2013 to June 2016).

Data analyzed included the Total Body Surface Area (TBSA) on admission, serum procalcitonin level within the first 48 hours and incidence of bacteremia within the first 10 days of admission when there is bacterial growth in blood culture. At our centre, measurement

of TBSA is guided by Lund and Browder Chart²; and serum procalcitonin and blood culture samples were sent if the patient was febrile i.e. body temperature more than 38.5 degrees Celsius.

Data compiled was analyzed using Statistical Package for the Social Sciences® Version 20.0.

Results:

During the 3-year period analyzed in our study, 67 patients were admitted to our Burns Intensive Care Unit. Patients with no serum procalcitonin level within the first 48 hours were excluded. A total of 39 patients were included in our study.

While the main aim of the study is to assess the relationship between serum procalcitonin and bacteremia, the authors do recognise the possible added relationship between TBSA and serum procalcitonin on admission. Hence, we have grouped the patients into 3 groups according to the TBSA (A: <20%, B: 20-40% and C: >40%) to study and account for the possible correlation.

In a review by Meisner M³, which also included non-burn injury patients, a high procalcitonin level (>0.5 to >2.0ng/mL) is proposed to have a high positive predictive value for sepsis, severe sepsis or septic shock while normal or very low procalcitonin levels (<0.25 to <0.5ng/mL), have a high negative predictive value to rule out sepsis. In our study, serum procalcitonin levels were subcategorized into 2 groups: Low procalcitonin (<2.0ng/ml) and High procalcitonin (≥2.0ng/ml).

Groups A, B and C had 11, 8 and 20 patients respectively. Tables 1 and 2 below shows the number of patients included in the study, grouped into the respective categories according to TBSA, and the data studied.

Based on the data compiled, as illustrated in the Figure 1, there is a positive correlation between raised serum procalcitonin (≥2.0ng/ml) and the presence of bacteremia. When statistical analysis was performed using Chi-squared test, this relationship is statistically

significant (p -value=0.047; $p<0.05$). An analysis of the relationship between TBSA and serum procalcitonin also showed a possibility that there is a correlation between the initial TBSA with the initial procalcitonin levels (Figure 2).

Discussion:

In conclusion, the authors believe that serum procalcitonin can serve as a reliable early predictor of bacteremia. We were able to identify a statistically significant positive correlation between raised serum procalcitonin (≥ 2.0 ng/ml) within the first 48 hours of admission and the presence of bacteremia within the first 10 days of admission.

We do recognize that there are many factors that can influence procalcitonin levels and also the presence of bacteremia. Our study also highlighted a positive correlation between TBSA and serum procalcitonin. A review of the current literature highlights the possible validity of this relationship. Patients with $\geq 20\%$ TBSA are at a higher risk of bacteremia⁴ with a yield of 18.6 % positive cultures compared to a yield of 1.1 % positive blood cultures for TBSA burn $<20\%$ ⁵.

The authors believe that while serum procalcitonin levels can provide a quick way to predict the presence of bacteremia and thereby predict the possibility of sepsis, a detailed study to identify reference values of procalcitonin for burn injury of different TBSA would be very helpful. This will allow early initiation of empiric antibiotics before further colonization of bacteria in the patient⁶.

Conclusion:

The authors hope that procalcitonin can be used to further improve the care provided in burn injury by preempting the occurrence of complications. We do recognize that the statistical validity of our study can be further improved with future studies involving larger study populations. With a large sample size, we can also aim to identify a reference value of serum procalcitonin to guide in the predicting of bacteremia in burn injury. While elevated procalcitonin level may predict likelihood of bacteremia, a study of the direct relationship between sepsis and other factors including TBSA, mechanism of injury and time to treatment would also allow for a more comprehensive analysis.

References

1. Fleischmann C, Scherag A, Adhikari NK, et al. Assessment of Global Incidence and Mortality of Hospital-treated Sepsis. Current Estimates and Limitations. *Am J Respir Crit Care Med* 2016; 193:259.
2. S Hettiaratchy, R Papini. Initial management of a major burn: II—assessment and resuscitation. *BMJ*. 2004 Jul 10; 329(7457): 101–103.
3. Meisner M. Update on Procalcitonin Measurements. *Ann Lab Med*. 2014 Jul; 34(4): 263–273.
4. J Hwee, C Song, KC Tan, BK Tan, SJ Chong. The trends in Burns Epidemiology in a tropical regional burns centre. *Burns*. 2016 May;42(3):682-6
5. CT Song, J Hwee, C Song, BK Tan, SJ Chong. Burns infection profile of Singapore: prevalence of multidrug-resistant *Acinetobacter baumannii* and the role of blood cultures. *Burns and Trauma*. 2016 4:13
6. SJ Chong, S Ahmed, JM Tay, C Song, Tan TT. 5 year analysis of bacteriology culture in a tropical burns ICU. *Burns* Dec 2011; 37(8):1349-53