

# Verruca: Need to Know about Human Papilloma Virus (HPV) Infection

L KHONDKER<sup>a</sup>, MOR SHAH<sup>b</sup>, MSI KHAN<sup>c</sup>

### Summary:

*Verruca or warts are common significant cause of cosmetic concern and frustration of the patient. Social activities may be affected. Verruca are formed by benign proliferations of the skin and mucosa that are caused by infection with Human papilloma virus (HPV). These viruses do not produce acute signs or symptoms but induce a slow, focal expansion of epithelial cells. There are 100 types of Human papilloma virus (HPV). The natural history of common warts is for most of them to spontaneously resolve. But lesions are sometime uncomfortable. Warts typically continue to increase in size and distribution and may become*

*more resistant to treatment over time. A significant proportion of women with genital HPV infection develops low-grade cervical lesions. Most of these low-grade lesions regress spontaneously; one study suggests that approximately 15 percent progress to high-grade cervical lesions within two years. High-grade cervical lesions have a strong malignant potential; one study found that about one-third of high-grade lesions progress to cancer within ten years.*

**Key words:** Verruca, Human Papilloma Virus (HPV), cervical cancer.

(*J Bangladesh Coll Phys Surg 2012; 30: 151-158*)

### Introduction:

Verruca or warts, are benign proliferations of the skin and mucous membrane these are due to infection with Human papilloma viruses. These viruses do not produce acute signs or symptoms but induce a slow focal

expansion of epithelial cells. Lesions may remain subclinical for long periods or may grow to large fulminating masses that persist for months or even years. A subset of human papilloma virus (HPV) is known to cause benign warts that may undergo neoplastic transformation.<sup>1</sup>

- a. Dr. Lubna Khondker, MBBS, DDV, MCPS, FCPS (Dermatology and Venereology), Assistant Professor of Dermatology and Venereology, Bangabandhu Sheikh Mujib Medical University, Shahbag, Dhaka.
- b. Col. (Dr) Md Obaidur Rahman Shah, MBBS, DDV, FCPS (Dermatology and Venereology), Classified Specialist in Dermatology and Venereology, Combined Military Hospital (CMH), Dhaka Cantt, Dhaka.
- c. Major (Dr). Md Shirajul Islam Khan, MCPS, DDV (Dermatology and Venereology), Specialist in Dermatology and Venereology, Combined Military Hospital (CMH), Dhaka Cantt, Dhaka.

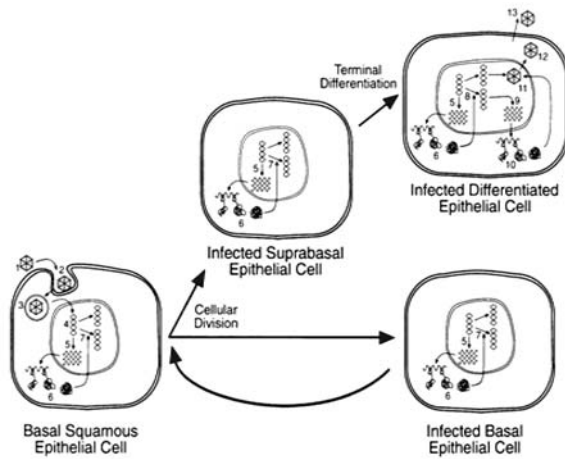
**Address of Correspondence:** Dr. Lubna Khondker, MBBS, DDV, MCPS, FCPS (Dermatology and Venereology), Assistant Professor of Dermatology and Venereology, Bangabandhu Sheikh Mujib Medical University, Shahbag, Dhaka, Mobile- 01552370429, E-mail: lubna\_derma@yahoo.com.

**Received:** 21 May, 2011

**Accepted:** 11 June, 2012

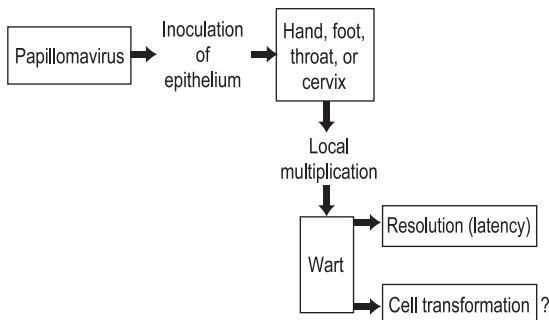
### Human Papilloma Virus (HPV)

Papilloma viruses are a diverse group of small DNA viruses that induce warts in a variety of vertebrates including human. Some papilloma viruses also have malignant potential. Papilloma viruses are highly species specific.<sup>2</sup> Hence, the papilloma virus causing infection in humans is called as human papilloma virus (HPV). Most papilloma viruses have a specific cellular tropism. The lesions can be cutaneous or can involve mucosal squamous epithelium.<sup>3</sup> The virus infects the basal layer of the epithelium, possibly stem cells, but virus replication takes place only in fully differentiated keratinocytes, i.e. cells of the upper stratum spinosum and stratum granulosum.<sup>4</sup> The papilloma viruses are small, non enveloped icosahedral DNA viruses.<sup>5</sup>



**Replication cycle of Papilloma virus:** To establish a wart or a papilloma, the virus must infect the basal epithelial cell. Our knowledge is limited about the initial steps in the replication cycle such as attachment (1), uptake (2), Endocytosis (3) and transport to nucleus and uncoating of the viral DNA (4). Early region transcription (5), Translation of the early protein (6), and steady state viral DNA replication (7) an occurring basal cell and in the infected supra basal epithelial cell. Events in the viral lifecycle leading to the production of virion particles occur in the differentiated keratinocytes: Vegetative viral DNA replication (8), Transcription of the late region (9), production of the capsid proteins L1 and L2 (10), assemble of the virion particles (11), nuclear breakdown (12), and release of virus (13). [From: *Fields Virology. 4<sup>th</sup>ed.Knipe DM, Howley PM; 2001.p.2197-229.*

**Papillomavirus pathogenesis**



From: *Medical Microbiology, 5<sup>th</sup> ed. Murray, Rosenthal & P Faller, Mosby inc. 2005.*

**Types of Human Papilloma Virus(HPV)**

More than 120 different HPV types have been characterized and it is believed that there are many additional types that have not yet been described.<sup>6</sup> The classification of viral types is based on the species of origin and the extent and degree of related viral genome. The initial classification of the specific type was based on the extent of homology of the DNA genome, using liquid hybridization techniques<sup>7</sup> Depending upon their distinct regional predilection, histopathology and biology, HPV types are separated into three categories(nongenital) types(viz. HPV types 1-4), genital mucosal types (viz. HPV types 6,11,16and 18), and isolates from epidermodysplasia verruciformis (EV) (viz. HPV types 5 & 8).<sup>1</sup> Another important category may be those with a malignant potential. First noted in association with epidermodysplasia verruciformis (viz. HPV type 5 & 8), association of HPV types 16 & 18 with cervical carcinoma has also been found.<sup>8</sup>

**Epidemiology of verruca**

It is difficult to determine the overall prevalence of HPV infection. However, it is generally accepted that HPV infections are common and their prevalence has probably increased over the last few decades.<sup>9</sup> Warts occur at any age. Epidemiological data suggested that cutaneous warts are common in children but tend to vary in age distribution according to types.<sup>10</sup> Transmission occurs by means of physical contact with a contaminated object, e.g. the wart itself or toys. The estimated prevalence is 1% in sexually active population in USA. Anogenital warts caused by HPV types 6 and 11, are considered as low risk. High risk HPV types 16 and 18 are found in approximately 40% to 60 % and 10 % to 20 % of all cervical carcinomas, respectively.<sup>11</sup>

Acquisition of HPV depends on several factors, including the location of lesions, the quantity of infectious virus present, and the degree and nature of contact, & the general and HPV specific immunologic status of the exposed individual. Although humoral immunity contributes to resistance to acquisition of infection, host cellular immune reactivity plays an important role in wart regression. Individuals with impaired cell mediated immunity are particularly susceptible to persistent HPV infection, & their infections are notoriously resistant to treatment. Warts are common in renal and solid organ transplant patients

on immunosuppressive therapy, which may contribute to their increased risk of malignancy. Non-genital warts occur most frequently in children and young adults, in whom the incidence may exceed 10%. Anogenital warts behave as a sexually transmitted condition, and partners can transmit the virus with high efficiency. Penile lesions occur frequently in the sexual contacts of women with cervical intraepithelial neoplasia but not all pearly penile papules are caused by HPV.<sup>1</sup>

### Natural history

In many cases of cutaneous warts, spontaneous resolution occurs within 1 or 2 years. The rate of resolution may be adversely influenced by the HPV type, the extent of duration of warts and the suppression of the host's cell-mediated immune response.<sup>9</sup> Reported clearance rates in children are 23% at 2 months, 30% at 3 months, 65% to 78% at 2 years, and 90% over 5 years.<sup>5</sup>

Deficiencies in cell-mediated immunity can lead to persistence of infection. This can occur as a primary condition e.g. in ataxia-telangiectasia or common variable immune deficiency.<sup>12</sup> Secondary immunodeficiency are also associated with frequent & persistent HPV infection, e.g. hematological malignancies, and acquired immune deficiency syndrome (AIDS). Organ allograft recipients, who are on long term immunosuppressives, also have a higher incidence. In atopic dermatitis, there is an increased occurrence of warts.<sup>13</sup>

### Incubation period

The time of acquisition of the infection can seldom be ascertained for common and planter warts, but the incubation period has been estimated to range between a few weeks and more than a year<sup>3</sup>, and experimental infections have taken as long as 20 months to produce clinical warts<sup>14</sup>. A prospective study of sexual contacts of patients with genital warts indicate an incubation period of 3 weeks to 8 months (average 2.8 months)<sup>15</sup>. It is believed that perinatally acquired HPV infection may not manifest as genital warts for up to 2 years<sup>16</sup>. Only 57% of cases of laryngeal papilloma in children are diagnosed by 2 years of age<sup>17</sup>.

### Infectivity & transmission

There is no reliable information on the infectivity of common and plantar warts, but it is low. Warts spread by direct or indirect contact. Impairment of epithelial

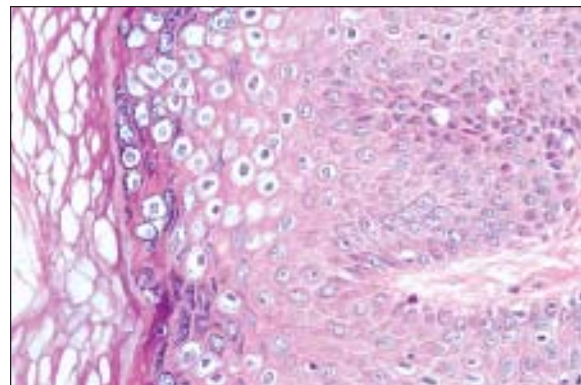
barrier function from trauma, maceration or both, can predispose to infection with HPV either 'in utero' or during delivery from mother to infant is an important mode of spread of the virus to neonates.<sup>4</sup>

In adults, anogenital warts are transmitted through sexual contact in most patients.<sup>15</sup> Anogenital warts are uncommon in children and hence there are insufficient data to conclusively prove their sexual transmission infection from the mother's genital tract at delivery is regarded as a frequent source of childhood anogenital warts.<sup>18</sup> postnatal transmission from adults with genital warts may occur non-sexually.<sup>19</sup> Other reports suggested a sexual mode of transmission. Thus, both sexual and non sexual routes are significant in the transmission of anogenital warts in children. Absence of other evidence of sexual abuse, location of warts on fully keratinized skin as opposed to genital or anal mucosa, a clinical resemblance to common warts and young age of the child perhaps up to 1-2 years at the onset of warts, would support non sexual transmission. If sexual abuse is suspected, HPV typing may be useful to establish the mode of transmission.<sup>4</sup>

### Pathology

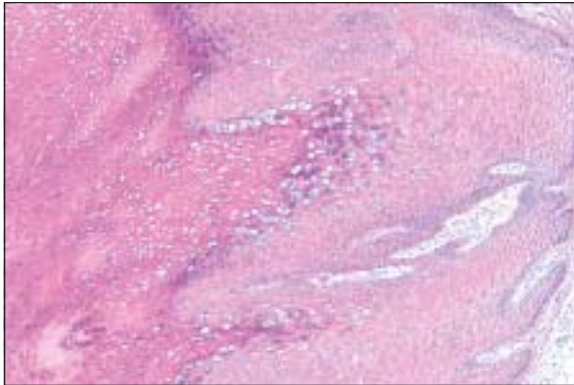
The characteristic histological feature of viral warts is vacuolation in cells in and below the granular layer, often with basophilic inclusion bodies composed of viral particles, and eosinophilic inclusions representing abnormal keratohyaline granules. This cytopathic effect may show detailed features typical of the HPV type involved<sup>20</sup> and is most always accompanied by epidermal acanthosis & often papillomatosis.<sup>21</sup>

Histologically, the koilocytic keratinocytes contain nuclear inclusions and "basket weave" appearance is seen in the cornified layer (HE). (fig.1). *Verruca vulgaris*



**Fig. 1**

seen in the forearm of 13 y-o male, showing papillomatosis and hyperparakeratosis with koilocytosis (HE). Hypergranulosis with nuclear inclusions and perinuclear koilocytic changes is evident. Vacuoles remaining in the cornified layer are suggestive of HPV infection. (fig.2)



**Fig. 2**

#### **Immunity to HPV**

The viral life cycle appears to have evolved to minimize the exposure of the immune system to viral antigens. However, the course of infection is determined by the immune response of the host.<sup>22</sup> T cell immune responses appears to be most important after the host has been infected, whereas humoral immunity may help prevent the spread of infection to new sites with the host reduces the likelihood of reinfection.<sup>2</sup> Protection appears to be largely type specific.<sup>23</sup> Resistance to re-infection by one HPV type does not appear to confer resistance to re-infection by other types. Cell mediated immunity appears to be the principal mechanism for rejection of warts. In persistent disorders of cell mediated immunity, the prevalence and severity of warts and the incidence of HPV related malignancy are increased.<sup>24</sup>

#### **Clinical features:**

HPV infection can occur in many parts of the body such as the skin, and mucous membranes of the genitals and oral cavity. There is some type specificity for involvement of different sites. Some warts may have malignant potential, but almost all resolve spontaneously. Spontaneous recovery depends largely on the individual's immune status, e.g. in immunosuppressed individuals, generally the infection persists for a long time & involves larger areas & may be resistant to therapy; moreover, recurrences are

common. On the skin, HPV infection may manifest as common warts, flat warts & filiform warts: depending on the site, there may be palmer & planter warts, anogenital warts, oral warts and conjunctival warts.<sup>4</sup>

#### ***Verruca Vulgaris (Common warts):***

HPV type 1, 2, 4, 27, and 57. & 63 cause common warts. They occur largely between the age of 5 and 20 and only 15% occur after the age of 35. Frequent immersion of hands in water is a risk factor for common warts. Meat handlers, fish handlers, and other abattoir workers have a high incidence of common warts of the hands. The prevalence reaches 50% in those persons with direct contact with meat.<sup>1</sup> Common warts are usually located on the dorsa of the hands and in children under 12 years of age, on the knees. They also favor the fingers and palms. Periungual warts are more common in nail biters and may be confluent, involving the proximal and lateral nail folds. Common warts may occur anywhere on the skin apparently spreading from the hands by autoinoculation.<sup>4</sup>

Fissuring may lead to bleeding and tenderness. Lesions range in size from pinpoint to more than 1 cm, most averaging about 5 mm. They grow in size for weeks to months and usually present as elevated, rounded papules with a rough, grayish surface, which is so characterized that it has given us the verrucous.<sup>1</sup>

Common warts are usually symptom less, but may be tender specially growing beneath the nail plate. It may disturb in nail growth. Warts on the eye lid may be associated with conjunctivitis or keratitis. About 65% of common warts disappear spontaneously within 2 years and tend to do so earlier in boys.<sup>4</sup>

#### **Planter Warts:**

The occurrence of warts on the planter skin is not uncommon. People who have the habit of rubbing their feet against rough surfaces while bathing or otherwise, are more prone to develop such lesions. The lesions are mainly seen over the pressure points such as the heels or metatarsal heads. A planter wart appears as a small, shiny, deep seated papule. Gradually it becomes a sharply defined rounded lesion with rough keratotic surface surrounded by a smooth collar of thickened horn. The common types causing planter warts are HPV types 1, 2, 4, or 57.<sup>4</sup> Planter warts may be confused with callosities or corns. The diagnosis is made by noting

- papillomavirus testing to detect high-grade squamous intraepithelial lesions. *Canadian Medical Association Journal* 2000;163(5):513-518.
18. Bellinson, J.L., Pretorius, R.G., Zhang, W.H. "Cervical Cancer Screening by Simple Visual Inspection After Acetic Acid." *Obstetrics and Gynecology*. 2001. 98(3). 441-444.
  19. Bomfim, S. "Visual Inspection with acetic acid for cervical cancer detection". *International Journal of Gyn and OB*. 2005. 88.
  20. De Vuyst, H. "Comparison of pap smear, visual inspection with acetic acid, HPV DNA-PCR testing and cervicography." *International Journal of Gyn and OB*. 2005. 89.
  21. Doh, A.S. "Visual Inspection with acetic acid and cytology as screening methods for cervical lesions in Cameroon." *International Journal of Gyn and OB*. 2005. 89.
  22. Goel, A., Gandhi, G., Batra, S. "Visual Inspection of the cervix with acetic acid for cervical intraepithelial lesions." *International Journal of Gynecology and Obstetrics* 2005. 88, 25-30.
  23. Lawrence, MJ, Wigton, TR, Leonhardt, JG. "Screening for Cervical Neoplasia in an Unselected Rural Guatemalan Population Using Direct Visual Inspection after Acetic Acid Application: A pilot study." *Journal of Lower Genital Tract Disease*. 2005. 9(4). 232-235.
  24. Ngelangel, C.A. "Acetic-acid guided visual inspection vs. cytology-based screening for cervical cancer in the Phillipines." *International Journal of Gyn and OB*. 2003. 83.
  25. ACOG Practice Bulletin No. 99: management of abnormal cervical cytology and histology. *Obstet Gynecol*. 2008;112(6):1419-1444.
  26. ACOG Committee on Gynecological Practice. *ACOG Practice Bulletin No. 109: Cervical Cytology Screening*. *Obstet Gynecol*. 2009 Dec;114(6):1409-1420.
  27. James WD, Berger TG, Elston MD. *Andrews' Diseases of Skin*. 10<sup>th</sup> ed. Philadelphia: WB Saunder's Comp; 2006. 403-13.
  28. Elliot, D. *et al*. Combined Cryotherapy/70% Salicylic Acid Treatment for Plantar Verrucae. *The Journal of Foot and Ankle Surgery* 2001; Vol. 40(1): p. 36-41.
  29. Campbell J. *et al*. Warts are not Merely Blemishes on the Skin: A Study on the Morbidity Associated with having Viral Cutaneous Warts. *Australasian Journal of Dermatology* 2003; Vol. 44: p. 169-173.
  30. Bunny M.H. *et al*. An Assessment of Methods of Treating Viral Warts by Comparative Treatment Trials Based on a Standard Design. *British Journal of Dermatology* 1976; Vol. 94: p. 667-679.
  31. Sinclair R.D. & Thai K.E. Cryosurgery of Benign Skin Lesions. *Australasian Journal of Dermatology* 1999; Vol. 40: p. 175-186.
  32. Landsman, M.J. *et al*. Diagnosis, Pathophysiology and Treatment of Plantar Verrucae. *Clinics in Podiatric Medicine and Surgery: Podiatric Dermatology* 1996; Vol. 13(1): p. 55-71.
  33. Berth Jone. *et al*. Plantar Verrucae and HIV Infection. *Clinics in Podiatric Medicine and Surgery* 1998; Vol. 15(2): p. 317-327.
  34. Bazmi K. *et al*. Cryotherapy of Viral Warts: A Sustained 10-s Freeze is More Effective than the Traditional Method. *British Journal of Dermatology* 2001; Vol. 145: p. 554-557.

the break in the dermatoglyphic pattern over the lesion, pain on lateral pressure and the appearance of bleeding points on paring. The can also be confused with discrete horny papules punctate keratoderma.

**Plane warts (flat warts):**

Plane warts, due mainly to HPV-3 and HPV-10, are smooth, flat or slightly elevated and are usually skin-colored or grayish-yellow but may be pigmented. They are round or polygonal in shape and vary in size from 1 to 5 mm or more in diameter. The face and the dorsa of the hands and the shins are the sites of predilection.<sup>25</sup>

**Filiform and digitate warts:**

Filiform and digitate warts occur commonly in the male, on the face and neck, and are irregularly distributed and often clustered. Digitate warts often in small group, also occurs on the scalp in both sexes, where they are occasionally confused with epidermal naevi. Isolated warts on the limbs often assume a filiform shape.<sup>4</sup>

**Anogenital warts:**

Anogenital warts are common, with an estimated 1.3 million new cases per year in the USA. They are often asymptomatic, but may cause discomfort, discharge or bleeding. The typical anogenital wart is soft, pink, elongated and sometimes filiform or pedunculated. The lesions are usually multiple especially on moist surfaces, and their growth can be enhanced during or in the presence of any other local infections. Large malodorous masses may form on vulvar or perianal skin. This classic 'acuminate' form constitutes about two thirds of anogenital warts. The commonest sites, the area frenulum, corona and glans in men, and the posterior fourchette in women, correspond to the likely sites of greatest coital friction.<sup>15</sup>

In children, warts in the anogenital area are often more hyperkeratotic than in adults and may be caused by HPV types associated with cutaneous disease as well as by HPV-6 and HPV-11. The duration of anogenital warts varies from a few weeks to many years. Recurrence can be expected in about 23 % of cases, the interval varying from 2 month to 23 years.<sup>26</sup>

**Concept of Cervical Cancer:**

Cervical cancer kills approximately 230,000 women annually, with the vast majority of deaths occurring in developing countries. Worldwide, cervical carcinoma

is the fifth most common cancer-related cause of death among women; in the developing world, it is the leading cause of cancer death in women. The global distribution of cervical cancer varies, with Africa, Asia, and Latin America bearing a substantial burden of this disease.<sup>11</sup> Research worldwide has clearly shown that virtually all cervical cancer is caused by human papillomavirus (HPV) infection.<sup>23</sup> It is estimated that less than five percent of women infected with HPV who receive no health intervention ultimately develop cervical cancer.<sup>27</sup> Some estimates indicate that more than 50 percent of sexually active adults in the United States have experienced an infection with one or more HPV viral types.<sup>10</sup> One study, using prevalence data among Finnish women, estimated a woman's lifetime risk of HPV infection at 75 percent.<sup>11</sup> One study suggests that in up to 70 percent of those initially diagnosed, the infection is undetectable within two years.<sup>12</sup>

**HIV infection:**

In HIV infection, common, planter, flat, oral and genital warts are all very common. Warty keratoses at the angle of the mouth, often bilateral are a characteristic and perhaps unique, manifestation of HPV infection in patients with AIDS. The warts are caused predominantly by HPV-2,-27 and -57. Genital neoplasia associated with HPV 16 and -18 occur much more frequently in HIV infected women and homosexual men. HIV infected persons whose helper T-cell count never falls below 200 are more likely to have sustained remission of their warts. Genital warts are increased 15 fold among HIV infected women.<sup>27</sup>

**Diagnosis:**

1. The clinical appearance and history of acquired, slowly enlarging papules usually lead to the diagnosis of viral wart.
2. Histologic examination can be used to confirm the diagnosis.
3. Application of 3% to 5% acetic acid to genital warts enhances visualization of these lesions. Particularly with colposcopic magnification, although the diagnosis should not rest only on the present of the white lesions as the test is non-specific.
4. Immunohistochemical detection can be used to detect these capsid proteins in clinical materials,

including formalin-fixed tissue, but is sensitive and not routine.

5. PCR techniques detect cutaneous HPV but are generally limited to research & diagnostic laboratories.<sup>1</sup>

#### Discussion:

It is believed that most people would have claimed to have a verruca at some stage of their lives and they have also accepted the fact that 'the wart infection has increased over the last century with the figures estimated between 7 and 10 per cent in Europe and the USA.<sup>3</sup> Warts are not commonly found in tropical regions, however, they are commonly known to occur in the winter months according to Elliot *et al.*<sup>28</sup>. It is known that, Verruca pedis commonly affect approximately 4.5 per cent of school children in the UK.<sup>29</sup> The incidence of verruca pedis peaks at the ages of 12 and 16 years with females and males being equally affected with the wart virus infection.<sup>30</sup>

It is considered that verruca vulgaris can spread from person to person or when traumatized or fissured skin comes into contact with the virus in communal showers, changing rooms and swimming pools which can also increase the incidence of verruca vulgaris, stated by Elliot *et al.*<sup>28</sup>

Campbell *et al.* (2003) reported that duofilm and cryotherapy was the best choice of treatment employed when a survey was conducted among 85 patients chosen from the public and from the dermatological department in Australia.<sup>29</sup> Bunny *et al.* have been reviewed within the literature and have been reported for treating verrucae pedis and concluded that the most satisfactory treatment was duofilm. However, the success rates differ within many studies. Bunny *et al.* reported that in their 1969 trial, 296 common warts from 382 patients were treated with salicylic acid. The authors found an 84% cure rate by the end of 12 weeks and concluded that salicylic acid is a suitable method for treating common warts. However, many years later, Bunny disagreed with the fact that salicylic acid is not compulsory for the treatment of warts. There is no evidence to suggest why the author had come to this conclusion.<sup>30</sup>

One study was found to have compared the combination of 17% salicylic acid with 17% lactic acid versus placebo by Sinclair *et al.* in a small sample size of 57

patients in a double blinded study. The age range of the participants between 7-30 years in the active treatment group and 8-34 years in the placebo group were found later in the results section. There was no age variation in the two groups which may have led the reader to think of any patient bias. The cure rates from this study were compared at 6 weeks and 6 months. At 6 weeks the authors reported a high cure rate in the active treatment group (66%) compared to the placebo group (18%). At the end of 6 months the author reported a high cure rate in the active treatment group (83%) compared to the placebo group (54%). The authors reported that duofilm was more significant in the active treatment group (80%) than in the placebo group (43%) during the first week of treatment but was less significant in the final week of treatment in the placebo group (35%) than in the active treatment group (4%). Furthermore, it was also reported that 60% of the participants had HPV1 IgM antibody detected in their sera where as only 9% were detected with HPV2 IgM antibody.<sup>39</sup>

Several authors have stated that 'the most advocated procedure is the use of liquid nitrogen,' which has a boiling point of -196°C has shown to have a 91% cure rate by Landsman *et al.*<sup>32</sup> If cryotherapy is applied every three weeks, the effectiveness will be of great significance in the cure rates and this significance was demonstrated by Berth-Jones *et al.* when they compared effectiveness of cryotherapy when treating warts at weekly, 2-weekly and 3-weekly intervals. A sample size of two hundred and twenty five participants had taken part in this study. The cure rates from this study were reviewed at the end 3 months for the weekly group, 6 months for the 2-weekly group and 9 months for the 3-weekly group. The authors reported an overall cure rate of 43% in the weekly group, 37% in the 2-weekly group and 26% in the 3-weekly group by the end of 3 months even more so, the authors reported that after 12 treatments the cure rates were similar in the weekly group (43%), 2-weekly group (48%) and in the 3-weekly group (44%). Participant withdrawal rate was relatively low (24%) before the 3 months compared to the beginning of the 12 treatments (40%). The authors state the reason for this was 'failure to attend'. In the author's findings, blistering and soreness was a common complaint presented among the three treatment groups.<sup>33</sup>

Several authors (Bunny *et al.*) have debated whether a single or a double freeze cycle is suited best when treating warts.<sup>30</sup> Sinclair & Thai (1999) have stated that ‘the timed spot freeze technique is one method of standardising the delivery of the desired dose of cryogen to maximise destruction of the lesion, it was concluded that the double freezing had no effect on the hand warts but had a greater effect on plantar warts, although single freezing may be beneficial when treating hand warts. They evaluated the value of a second freeze thaw when treating common warts in three hundred participants presenting with hand and plantar warts.’<sup>31</sup>

Bunny *et al.* states that ‘the time required to freeze the wart is between 5-30 seconds depending on the thickness of the wart.’<sup>30</sup> The actual time to freeze the warts was studied in 2001 by Bazmi *et al.* in a study frame of two hundred participants, 91 males and 109 females, with a mean age of 22 years. The participants were randomly selected to receive a traditional method of freezing or a 10 second sustained freezing with liquid nitrogen. The participants were treated with a single freeze thaw cycle using the ‘Brymill Cryogun’, and according to the authors this method was easier and it worked more rapidly than did the cotton buds.<sup>34</sup>

### Conclusion:

HPV infection (genital) is a sexually transmitted infection (STI) that is very common among young men and women in many parts of the world. More than 30 HPV types are associated with genital warts. Research worldwide has clearly shown that virtually all cervical cancer is caused by human papillomavirus (HPV) infection. Besides cancer of the cervix, genital HPV infection is closely linked with cancer of the glans penis, anus, vulvo-vaginal area and periungual skin. In HIV infection, common, planter, flat, oral and genital warts are all very common. A large portion of genital HPV infection is either subclinical or latent. Subclinical or latent infection are probably responsible for most recurrences, following treatment of genital warts.<sup>27</sup> So knowledge about HPV infection, its early detection and treatment is necessary.

### References:

1. Wolf K, Goldsmith LA, Katz SI, Gilchrest BA, Paller AS, Laffel DJ. Fitzpatrick's Dermatology in General Medicine. 7<sup>th</sup> ed. USA: McGraw-Hill Comp; 2008. 1914-22.
2. Howley PM, Lowy DR. Papilloma virus and their replication In: Knipe DM, Howley PM, editor. Fields Virology. 4<sup>th</sup> ed. Philadelphia: Lippincott Williams; 2001; p. 2197-229.
3. Sterling JC. Virus infections. In: Burns T, Breathnach S, Cox N, Griffith C, editors. Rook's Textbook of dermatology. 7<sup>th</sup> ed. Oxford: Blackwell Publishing; 2004; p. 25.1-25.83.
4. Brentyens MH, Yeung-Yue KA, Lee PC, Tyring SK. Human papillomavirus: a review. *Dermatol Clin.* 2002; 20:315-31.
5. Gaffikin, Lynne DrPH. "Performance of Visual Inspection With Acetic Acid for Cervical Cancer Screening: A Qualitative Summary of Evidence to Date". *Obstetrical and Gynecological Survey* 2003; Vol 58(8).
6. Ghaemmaghami, F. "Visual Inspection with acetic acid as a feasible screening test for cervical neoplasia in Iran." *International Journal of Gyn Cancer.* 2004. 14.
7. Bentose EC. Human papillomavirus infection and molluscum contagiosum In: Harper J, Oranje A, Prose N, editors. *Textbook of pediatric dermatology.* 2<sup>nd</sup> ed. Oxford: Blackwell; 2006; p. 369-84.
8. Sedlacek TV. Advances in the diagnosis and treatment of human papillomavirus infections. *Clinical Obstetrics and Gynecology* 1999; 42(2):206-220.
9. Schiffman M, Herrero R, Hildesheim A, et al. HPV DNA testing in cervical cancer screening: results from women in a high-risk province of Costa Rica. *Journal of the American Medical Association* 2000; 283:87-93 .
10. Wright TC Jr, Denny L, Kuhn L, et al. HPV DNA testing of self-collected vaginal samples compared with cytologic screening to detect cervical cancer. *Journal of the American Medical Association.* 2000; 283(1):81-86.
11. Franco EL, Rohan TE, Villa LL. Epidemiologic evidence and human papillomavirus infection as a necessary cause of cervical cancer. *Journal of the National Cancer Institute* 1999; 91(6):506-511.
12. Walboomers JM, Jacobs MV, Manos MM, et al. Human papillomavirus is a necessary cause of invasive cervical cancer worldwide. *Journal of Pathology* 1999; 189(1):12-19.
13. Sellors JW, Mahoney JB, Kaczorowski J, et al. Prevalence and predictors of human papillomavirus infection in women in Ontario, Canada. *Canadian Medical Association Journal* 2000; 163(5):503-508.
14. Digene, Inc. Hybrid capture technology. [http://www.digene.com/customer/techsup/hcs\\_tech.htm](http://www.digene.com/customer/techsup/hcs_tech.htm). (Accessed January 2000).
15. Digene, Inc. HPV physician q & a. [http://www.digene.com/resources/hpvinfo/phys\\_faq.htm](http://www.digene.com/resources/hpvinfo/phys_faq.htm). (Accessed January 6, 2000).
16. Lytwyn A, Sellors JW, Mahoney JB, et al. Comparison of human papillomavirus DNA testing and repeat Papanicolaou test in women with lowgrade cervical abnormalities: a randomized trial. *Canadian Medical Association Journal* 2000; 163(6):701-707.
17. Sellors JW, Lorincz A, Mahoney JB, et al. Comparison of self-collected vaginal, vulvar and urine samples with physician-collected cervical samples for human